



Factors Affecting Survival in Metastatic Tumor Treatment Metastatik Beyin Tümörü Tedavisinde Sağkalımı Etkileyen Faktörler

Kemal Ertılav¹, Serdar Ercan², Zeki Serdar Ataizi³

¹Suleyman Demirel University, School of Medicine, Department of Neurosurgery, Isparta, Turkey

²Eskisehir City Hospital, Department of Neurosurgery, Eskisehir, Turkey.

³Yunus Emre State Hospital, Department of Neurosurgery, Eskisehir, Turkey.

Abstract

Objective: The incidence of brain metastases increases every day due to the advances in systemic treatment of cancers and the widespread of magnetic resonance imaging (MR) scanning. However, there are no basic treatment methods that go parallel to this increase. In this study, the effects of surgical intervention on survival were examined.

Material-Method: Patients who were admitted to our hospital with a diagnosis of metastatic brain tumor between 2014 and 2017 and who underwent surgery were included in the study. Demographic information was compiled retrospectively from patient records and these patients were followed at regular intervals. The data obtained were analyzed as multivariate using the proportional model of Cox and long rank test using SPSS, and $p < 0.005$ was considered significant.

Results: A total of 39 patients were included in the study. Total resection in 22 patients (TR) (56.4%), subtotal resection (STR) in 14 patients (35.8%), and only biopsy was performed due to poor condition in 3 patients (7.6%). Total resection of metastatic brain tumor was significantly increased the overall survival time. When Karnofsky Performance Status (KPS) was evaluated, $KPS > 70$ was found in 75% of patients. Longer survival was observed in patients with high performance scores. Total survival was 7 months in patients with $KPS > 70$, and 2 months in patients with $KPS < 70$.

Conclusions: Patients should be treated with corticosteroids instead of continuing emergency surgical resection, which provides sufficient time to complete preoperative preparations. Resection amount of metastatic tumor was found to be significantly associated with prognosis..

Keywords: Brain Tumor, Metastatic Tumor, Survival, Surgery.

Özet

Amaç: Kanselerin sistemik tedavilerindeki gelişmeler ve manyetik rezonans (MR) görüntülemesinin yaygınlaşması nedenleri ile beyin metastazlarının görülme sıklığı her gün artmaktadır. Ancak bu artışa paralel olarak giden temel tedavi yöntemleri bulunmamaktadır. Bu çalışmada cerrahi girişimin sağkalıma olan etkileri incelendi.

Materyal-Metot: 2014 -2017 yılları arasında metastatik beyin tümörü tanısı ile hastanemize başvuran ve cerrahi müdahale yapılan hastalar çalışmaya dahil edildi. Demografik bilgiler retrospektif olarak hasta kayıtlarından derlendi ve bu hastalar düzenli aralıklar ile takip edildi. Elde edilen veriler SPSS kullanılarak long rank ve Cox'un oransal modeli kullanılarak çok değişkenli olarak analiz edildi ve $p < 0,005$ anlamlı olarak kabul edildi.

Bulgular: Çalışmaya toplam 39 hasta dahil edildi. 22 hastada total rezeksiyon (TR) (%56,4), 14 hastada subtotal rezeksiyon (STR) (%35,8), 3 hastada (%7,6) kötü durum nedeniyle sadece biyopsi yapıldı. Metastatik beyin tümörünün total rezeksiyonu genel sağkalım süresini anlamlı olarak artırdığı anlaşıldı. Karnofsky Performans Durumu (KPS) değerlendirildiğinde, hastaların %75'inde $KPS > 70$ bulundu. Performans skoru yüksek olan hastalarda daha uzun sağkalım olduğu anlaşıldı. Toplam sağkalım $KPS > 70$ olan hastalarda ortalama 7 ay ve $KPS < 70$ olan hastalarda 2 ay olarak bulundu.

Sonuç: Hastalar preoperatif hazırlıkları tamamlamak için yeterli zaman sağlayan acil cerrahi rezeksiyona devam etmek yerine kortikosteroidlerle tedavi edilmelidir. Metastatik tümörün rezeksiyon miktarı prognoz ile anlamlı şekilde ilişkili olduğu görüldü.

Anahtar kelimeler: Beyin Tümörü, Metastatik Tümör, Sağkalım, Cerrahi.

Introduction

Metastatic brain tumors, which appear to be more common than primary tumors of the brain, often occur and multiply with primary tumors. Due to do tendency to invasion of metastatic brain tumors, they affect the surrounding neurological tissue and cause significant morbidity and mortality. The most common metastases to the brain are lung (45%), breast (15%),

melanoma (10%) and colorectal carcinomas (<2%) (1).

Metastases to the brain can only be diagnosed when clinical symptoms occur due to mass effect. Therefore, the rate of brain metastases is thought to be higher than known. Approximately 80% of patients with metastatic tumor in the brain were found to have multiple masses at first admission (2, 3).

Achrol stated that there was a difference in metastatic brain tumors according to gender, for example, men had a higher incidence of metastases of lung carcinoma, while women with breast carcinoma were the first (4).

The presence of brain metastasis in a primary cancer patient with solid mass is considered to be a poor prognostic indicator and the mortality rate is very high(5).

Treatment models such as surgical resection, stereotactic radiosurgery, fractionated radiation therapy and whole brain radiation therapy (WBRT) are used in the treatment of metastatic tumor in the brain. Untreated metastatic tumors shortens the mean survival of the primary tumor (3, 6).

The aim of this multicenter study was to investigate the effects of metastatic brain tumors on survival after surgical treatment.

Material and Methods

The patients who were admitted to the hospital with the diagnosis of metastatic brain tumor, operated and followed up between 2014 and 2017 were included in our study. Demographic and clinical information, surgical notes, lesion type, location, dimensions, duration of surgery, postoperative complications, pathology reports, clinical case notes, radiological images were obtained retrospectively from patient records. Overall survival is defined as the time from surgery to death or last visit. The performance of the patients was evaluated by Karnofsky performance score (KPS) and those with KPS>70 were classified as good performance.

Data analysis was performed using SPSS (Version 22.0. Armonk, NY: IBM Corp.). Univariate event-time analysis was performed using log rank test and Cox's proportional hazard model using multivariate analysis.

Results

A total of 39 patients (16 female and 23 male) with a mean age of 58,101 (42-82) were included to our study. The most common primary tumors were lung (19), breast (7), colorectal (6) and prostate (4) and malign melanoma (3). 19 patients (48.8%) presented with solid organ cancer and BM simultaneously. Of the 20 patients (51.2%) with previously diagnosed primary malignancy, 14 (70%) had a stable course, while 6 (30%) had progressive cancer.

Intravenous dexamethasone was administered to all symptomatic patients with brain metastasis who presented with brain edema. Craniotomy was performed in all patients. Only the life-threatening lesion was excised for patients with two or more brain metastases.

Total resection (TR) was performed in 22 patients (56.4%), subtotal resection (STR) in 14 patients (35.8%), and only biopsy was performed in 3 patients (7.6%) due to their poor condition (Figure 1). Total resection of metastatic brain tumor was significantly increased the overall survival time (p=0.004, Figure 2). Then, all patients received WBRT treatment. The mean time from surgery to WBRT was 22 days (range 8-64). Postoperative WBRT uptake significantly increased overall survival (OS) (p=0.0035) (Table 1).

Table 1. Demographic distribution of patients with metastatic brain tumor

Male (n)	23	
Female (n)	16	
Age (avarage)	58.108	
Locations (n)	Right	Left
Parietal	7	5
Occipital	3	4
Temporal	6	8
Frontal	2	1
Posterior fossa	2	1
Primer tumor diagnosed	20 (51.2%)	
Primer tumor non-diagnosed	19 (48.8%)	
Total tumor resection	22 (56.4%)	
Subtotal tumor resetion	14 (35.8%)	
Kaspersky Performance Scale		
>70	75%	
>70	25%	

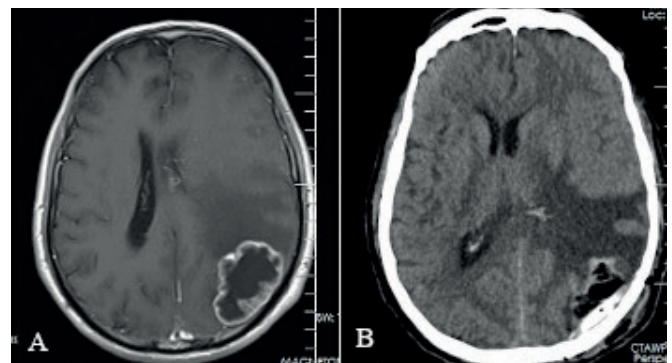


Figure 1. MRI and CT scan of metastatic brain tumor (A: preoperative scan of occipital metastatic tumor, B: Postoperative scan)

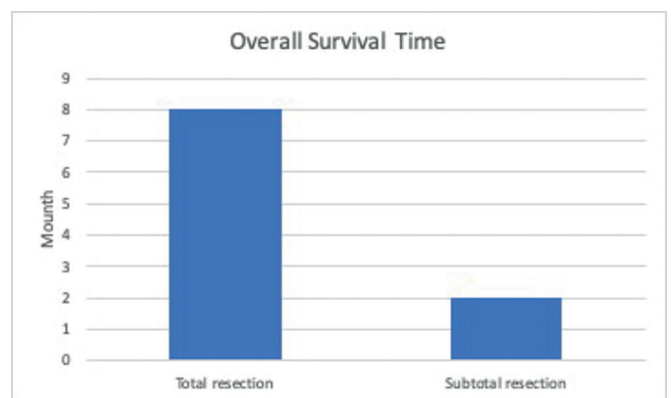


Figure 2. The correlation between overall survival time and the amount of metastatic tumor resection. Total resection of the tumor has significantly increased survival tim

3 patients died. The mean overall survival was 6.00 months. When Karnofsky Performance Status (KPS) of the patients were evaluated, KPS>70 was found in 75% of the patients. Good performance was associated with longer survival; OS: 7 months in patients with KPS>70 and 2 months in patients with KPS<70 (Figure 3).

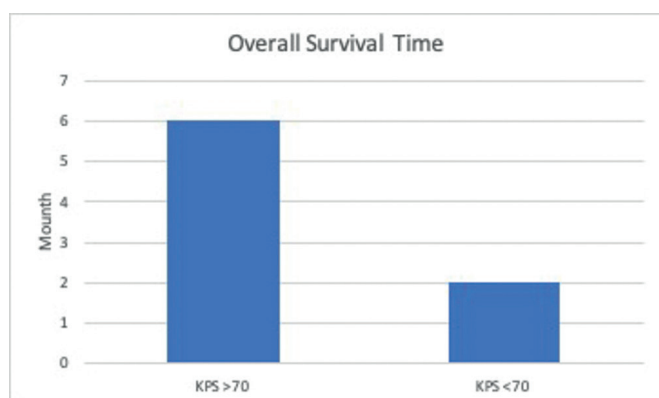


Figure 3. The correlation between overall survival time and KPS. The patients with KPS >70 has significantly higher survival time. KPS: (Karnofsky Performance Status)

Discussion

The aim of aesthetic dentistry today is to restore the missing One of the undesirable effects of systemic cancer is metastasis to the brain, which has critical functions. Metastatic brain tumor is seen in 15-30% of all cancers. They have high morbidity and mortality (7, 8). Although it is considered to be the last stage of previously uncontrolled primary tumor disease, the diagnosis of metastatic brain tumors has increased in recent years thanks to developing imaging techniques. Detection of metastatic brain tumors prior to primary tumor provided early diagnosis and increased survival (9). Detection of primary and metastatic tumors in the early period has increased, especially thanks to the routine use of contrast-enhanced MRI (10, 11). In our study, 20 patients were previously diagnosed as primary malignant tumors, while 19 patients presented to the clinic with different symptoms and the primary source was identified after the diagnosis of metastatic brain tumor. The most common source of primary malignant tumors that metastasize to the brain was found to be lung (20-40%) and breast (5-17%) (12-14). In our series, the primary tumor was the most metastatic lung.

Despite increasing treatment protocols for systemic cancer, metastatic brain tumor treatment still controversial (15). Although there are significant improvements in the metabolic structure of brain metastases, it may show poor prognosis after standard treatment (3). Therefore, the aim of the treatment is to extend the quality survival time.

Fractional WBRT or SRT is applied firstly because chemotherapy and pharmacological agents have limited use due to weak penetration into the central nervous system (15). WBRT treatment and surgical use is the mainstay for the treatment of multiple metastatic lesions in the brain, even if many symptoms occur in the brain. These treatments have many limitations due to adverse effects depending on the location and characteristics of the tumor. In our patients, steroid treatment (1 mg / kg / day) was started for the preoperative patients in the treatment of the symptoms related to the compression caused by metastatic brain tumor. Steroid treatment reduces brain edema and saves time for surgical intervention or radiotherapy.

One of the most crucial points in the treatment of brain

metastasis is to decide which patient should undergo surgery. Treatment should be planned by considering the pathologies caused by the pressure and biochemical response caused by metastatic tumor in normal brain tissue. Surgical intervention should be considered in case of hydrocephalus due to blockage as a result of tumor growth and pressure, and detection of the newly formed mass after WBRT (5, 16).

In the past, aggressive approaches including both surgical treatment and stereotactic radiosurgery (SRS) were available. This treatment protocol was used to be increased both recurrence and survival (17-19). However, surgical resection of a single large and symptomatic lesion has been found to be more advantageous in symptomatic recovery and survival compared to WBRT (20). This is consistent with similar studies explaining that large surgical resection of metastatic tumors has better outcomes with surgical resection. Lee et al. showed that median survival was significantly different compared to total total resection (median survival=20.4) and subtotal resection (median survival=15.1) (6, 21, 22).

In our series of 39 patients, good performance status (KPS>70) was the only significant prognostic factor independent of adjuvant WBRT treatment. Total surgical resection significantly prolonged survival compared to subtotal resection ($p=0.0039$).

Conclusion

In order to reduce the high morbidity and mortality associated with surgical resection, it is recommended that patients should be treated with corticosteroids instead of continuing with emergency surgical resection. This provides sufficient time for all patients to complete preoperative preparations before surgery. For the regression of neurological symptoms, the amount of resection of metastatic tumor affects prognosis. Total or near-total resection is recommended, depending on the localization of the tumor and the patient's condition.

References

1. Lowery FJ, Yu D. Brain metastasis: unique challenges and open opportunities. *Biochim Biophys Acta (BBA)-Reviews Cancer*. 2017;1867(1):49-57.
2. Brastianos PK, Carter SL, Santagata S, Cahill DP, Taylor-Weiner A, Jones RT, et al. Genomic characterization of brain metastases reveals branched evolution and potential therapeutic targets. *Cancer Discov*. 2015;5(11):1164-77.
3. Lah TT, Novak M, Breznik B. Brain Malignancies: Cancer Cell Trafficking in and out of the Niches. *Semin Cancer Biol* [Internet]. 2019; Available from: <http://www.ncbi.nlm.nih.gov/pubmed/31654711>
4. Achrol AS, Rennert RC, Anders C, Soffietti R, Ahluwalia MS, Nayak L, et al. Brain metastases. *Nat Rev Dis Prim*. 2019;5(1):1-26.
5. Owonikoko TK, Arbiser J, Zelnak A, Shu HKG, Shim H, Robin AM, et al. Current approaches to the treatment of metastatic brain tumours. Vol. 11, *Nature Reviews Clinical Oncology*. 2014. p. 203-22.
6. Salehi A, Kamath AA, Leuthardt EC, Kim AH. Management

of intracranial metastatic disease with laser interstitial thermal therapy. *Front Oncol.* 2018;8(OCT):1–6.

7. Distefano A, Yap HY, Hortobagyi GN, Blumenschein GR. The natural history of breast cancer patients with brain metastases. *Cancer.* 1979;44(5):1913–8.

8. Gavrilovic IT, Posner JB. Brain metastases: epidemiology and pathophysiology. *J Neurooncol.* 2005;75(1):5–14.

9. Nayak L, Lee EQ, Wen PY. Epidemiology of brain metastases. *Curr Oncol Rep.* 2012;14(1):48–54.

10. Schellinger PD, Meinck HM, Thron A. Diagnostic accuracy of MRI compared to CCT in patients with brain metastases. *J Neurooncol.* 1999;44(3):275–81.

11. Sze G, Milano E, Johnson C, Heier L. Detection of brain metastases: comparison of contrast-enhanced MR with unenhanced MR and enhanced CT. *Am J Neuroradiol.* 1990;11(4):785–91.

12. Davis FG, Dolecek TA, McCarthy BJ, Villano JL. Toward determining the lifetime occurrence of metastatic brain tumors estimated from 2007 United States cancer incidence data. *Neuro Oncol.* 2012;14(9):1171–7.

13. Nussbaum ES, Djalilian HR, Cho KH, Hall WA. Brain metastases: histology, multiplicity, surgery, and survival. *Cancer Interdiscip Int J Am Cancer Soc.* 1996;78(8):1781–8.

14. Zhang X, Zhang W, Cao W-D, Cheng G, Liu B, Cheng J. A review of current management of brain metastases. *Ann Surg Oncol.* 2012;19(3):1043–50.

15. Sunderland GJ, Jenkinson MD, Zakaria R. Surgical management of posterior fossa metastases. *J Neurooncol* [Internet]. 2016;130(3):535–42. Available from: <http://dx.doi.org/10.1007/s11060-016-2254-2>

16. Kalkanis SN, Kondziolka D, Gaspar LE, Burri SH, Asher AL, Cobbs CS, et al. The role of surgical resection in the management of newly diagnosed brain metastases: a systematic review and evidence-based clinical practice guideline. *J Neurooncol.* 2010;96(1):33–43.

17. Vecht CJ, Haaxma-Reiche H, Noordijk EM, Padberg GW, Voormolen JHC, Hoekstra FH, et al. Treatment of single brain metastasis: radiotherapy alone or combined with neurosurgery. *Ann Neurol Off J Am Neurol Assoc Child Neurol Soc.* 1993;33(6):583–90.

18. Aoyama H, Shirato H, Tago M, Nakagawa K, Toyoda T, Hatano K, et al. Stereotactic radiosurgery plus whole-brain radiation therapy vs stereotactic radiosurgery alone for treatment of brain metastases: a randomized controlled trial. *Jama.* 2006;295(21):2483–91.

19. Patchell RA, Tibbs PA, Walsh JW, Dempsey RJ, Maruyama Y, Kryscio RJ, et al. A randomized trial of surgery in the treatment of single metastases to the brain. *N Engl J Med.* 1990;322(8):494–500.

20. Mekhail T, Sombeck M, Sollaccio R. Adjuvant whole-brain radiotherapy versus observation after radiosurgery or surgical resection of one to three cerebral metastases: results of the EORTC 22952-26001 study. *Curr Oncol Rep.* 2011;13(4):255–8.

21. Thon N, Kreth F-W, Tonn J-C. The role of surgery for brain metastases from solid tumors. In: *Handbook of clinical neurology.* Elsevier; 2018. p. 113–21.

22. Lee C-H, Kim DG, Kim JW, Han JH, Kim YH, Park C-K, et al. The role of surgical resection in the management of brain metastasis: a 17-year longitudinal study. *Acta Neurochir (Wien).* 2013;155(3):389–97.