

# As a Result of Gunshot Wounds That Bullet in the Cervical Canal: A Case Report

Ateşli Silah Yaralanması Sonucu Servikal Kanal İçinde Bir Kurşun: Olgu Sunumu

**Fatma Duran Memiş**

Department of Emergency Medicine, University of Erzincan Binali Yıldırım, Mengücek Gazi Research and Training Hospital, Erzincan

Yazışma Adresi / Correspondence:

**Fatma Duran Memiş**

Erzincan Mengücek Gazi Eğitim Ve Araştırma Hastanesi, Acil Tıp Kliniği, Erzincan

T: +90 535 933 36 18 E-mail: [ftmdrn@hotmail.com](mailto:ftmdrn@hotmail.com)

Geliş Tarihi / Received : 21.06.2019 Kabul Tarihi / Accepted : 09.03.2020

Orcid:

**Fatma Duran Memiş** <https://orcid.org/0000-0001-7244-6958>

(Sakarya Tıp Dergisi / Sakarya Med J 2020, 10(1):148-151) DOI: 10.31832/smj.581126

## Abstract

Head and neck injuries account for about 30% of all firearm injuries. In this article, we present a case of head and neck bullet injury in which a bullet directed towards the cervical vertebral body and it was placed in the second cervical vertebral canal considering the trajectory after entering the body. A 27-year-old male patient was referred to our emergency department due to lead. It was confirmed that the mass in the localization identified the x-ray was the bullet. Cervical computed tomography revealed a foreign body (bullet) in the C2 vertebral canal and fracture in the C2 vertebral column. The patient was followed up in the intensive care unit, and then he died on the sixteenth day. As in our patient, the importance of patient stabilization is understood in head and neck injury due to firearm by considering the entry hole of the bullet, the trajectory and the place where it ends. This case with lead in the cervical canal after firearm injury is presented because it is a rare condition.

**Keywords** vertebra; trauma; emergency; firearm

## Öz

Baş-boyun yaralanmaları, tüm ateşli silah yaralanmalarının yaklaşık % 30'unu oluşturur. Bu makalede, mermi çekirdeğinin vücuda girdikten sonra, izlediği seyir göz önüne alındığında, servikal vertebra laraya doğru yönelmiş bir mermi çekirdeğinin servikal ikinci vertebral kanala yerleştiği baş-boyun kurşunlanma vakası sunulmuştur. 27 yaş erkek hasta acil servisimize kurşunlanma sebebiyle sevk edildi. Çekilen grafileri ile tanımlanan lokalizasyondaki kitlenin mermi çekirdeği olduğu tespit edildi. Hastaya çekilen servikal bilgisayarlı tomografide C2 vertebral kanalının içinde yabancı cisim (kurşun) ve C2 vertebral kolanda fraktür görüldü. Hasta yoğun bakım ünitesinde takibe alındı ve 16. gününde öldü. Ateşli silah yaralanması sonrası servikal kanalda kurşun bulunan bu olgu nadir gözlenen bir durum olması sebebiyle sunulmuştur.

**Anahtar kelimeler**

vertebra; travma; acil; ateşli silah yaralanması

### Introduction

Firearm injuries are quite common in daily life in developed and developing countries. The head and neck region is vital and has many anatomical structures. The major vessels carrying high flow blood, larynx, trachea and the first part of the medulla spinalis, which are involved in the regulation of many vital functions, are threatened by traumatic factors affecting the neck. Therefore, life-threatening clinical conditions occur more often in firearm injuries to the head and neck compared to other anatomical regions.<sup>1-3</sup> Head and neck injuries account for about 30% of all firearm injuries. It is more common in men and in black people. The mortality rate as a result of these injuries is higher in the young population.<sup>4</sup> Although the most important cause of death is vascular injuries, clinical signs of different characters can be seen due to the trajectory.<sup>5</sup>

In this article, we present a case of head and neck bullet injury in which a bullet directed towards the cervical vertebral body was placed in the second cervical vertebral canal considering the trajectory after entering the body.

### Case Report

A-27-year old male patient who was admitted to the emergency department due to a bullet injury in his face was found to have an irregular bullet entry hole in the left maxilla with only one focus on the body, but no bullet exit hole was found in the head and neck region. The bullet localization determined with the x-ray. (Figure 1)

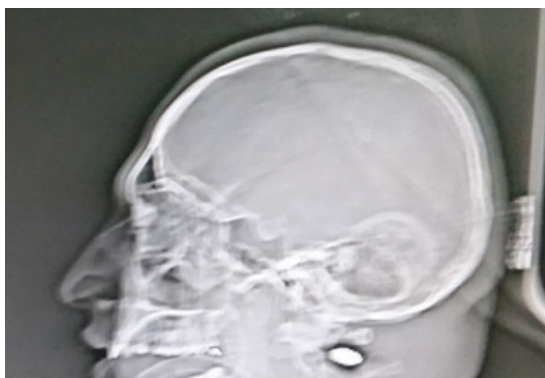


Figure 1: Lateral graphy image of bullet (indicated by arrow)

His general condition was moderate/good consciousness prone to sleep GKS:14 (E3V5M6)and his extremities moved spontaneously. His vital signs were normal, computerized brain tomography was reported normal . Cervical computed tomography revealed a foreign body (bullet) in the C2 vertebra canal and fracture in the C2 vertebral column (Figure 2-3-4). In the laboratory, tests was as follows: Glucose: 239 Ure/Kr: 39/0,96 WBC: 12,1 HGB: 12,4 PLT: 144. Neurosurgery and anesthesiologist consultation was requested. The patient was followed up in the intensive care unit, and then he died on the sixteenth day.

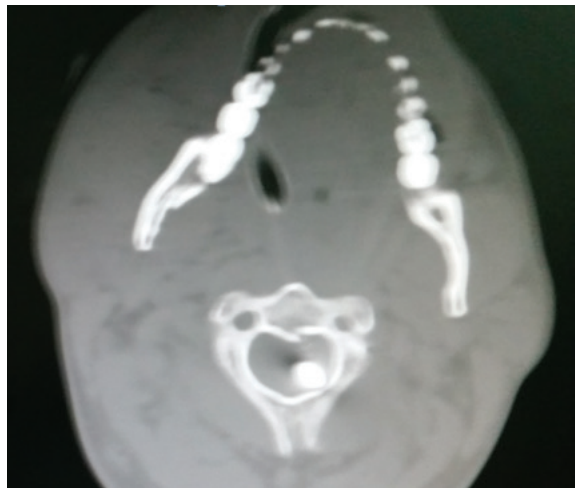

Figure 2: Tomographic image of the bullet in the cervical canal (indicated by arrow)

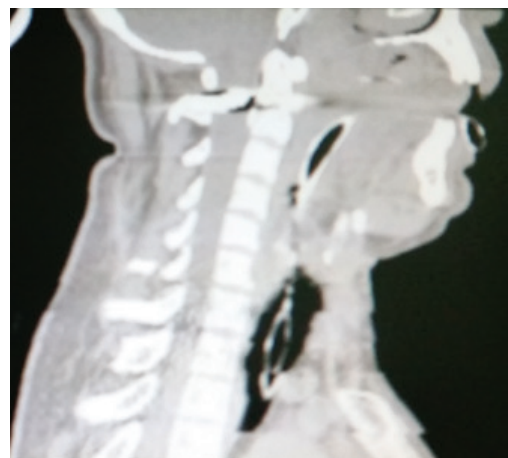
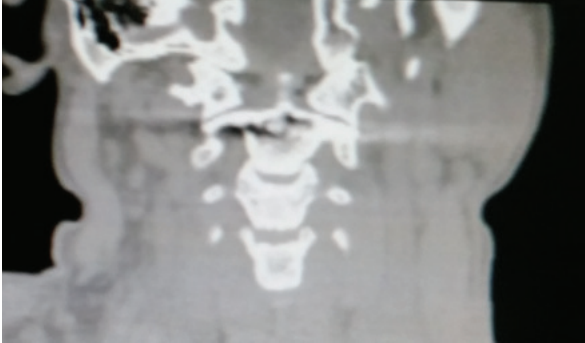


Figure 3: Tomographic image of the bullet in the cervical canal (indicated by arrow)



*Figure 4: Tomographic image of the bullet in the cervical canal (indicated by arrow)*

### **Discussion**

Patients with spinal cord trauma due to firearm injuries should be considered standard trauma patients. In the first evaluation, management of airway, bleeding control, struggling shock, internal organ injuries and spinal cord immobilization should be treated first. 6 Neck trauma can result in many clinical conditions. This is due to the various vital structures of this region. Trauma-related morbidity or mortality is caused by damaged vital structures. Medical and systemic stabilization should be the priority in patients with spinal cord injury due to gunshot injury. An important point here is whether to do an emergency surgical operation in a single part or multi-part injuries. In our patient, firstly patient stabilization was performed. In this case, the course of a bullet, which is a rare condition, reaches from the foremen magnum to the cervical canal. The bullet doesn't have an exit hole. The mortality rate in poniard neck firearm injuries is about 11% and this rate rises to around 66% in the injury of vital structures.<sup>7</sup> In these patients, the first thing to do is necessary to ensure airway safety. In these patients, the first thing to do is necessary to make sure airway safety. Respiration should be assured and patients should be given volume replacement.<sup>8</sup>

As a result; This case with after the firearm injury bullet in the cervical canal is presented because it is a rare condition

#### References

1. Grimes WR, Morris DM, Deitch EA. Shot gun wounds involving the head and neck, *Am J Surg*, 1988; 155: 776-779. (PMID: 3377118)
2. Yağhdere Ö, Gülkaya M, Gerek M, Dündar A. Ateşli silah yaralanması nedeniyle arteria karotis communis rüptürü, *Kulak Burun Boğaz Bülteni*, 1995; 2(2), 46-47.
3. Özkara E, Yemişçil A, Akacın K, Özdemir I, Çallı Ç. Boyun bölgesinde ateşli silah yarısı (Bir olgu sunumu), *Adli Tıp Bülteni*, 2000; 5(2):100-103.
4. Martin WS, Gussack GS. Pediatric penetrating head and neck trauma, *Laryngoscope*, 1990; 100:1288-1291. PMID: 2243519
5. Boyacıoğlu K, Büyükbayrak F, Yayla Tunçer E, AK A, Alp HM. Boyunda Atipik Mermi Seyirli Ateşli Silah Yaralanması *Damar Cer Derg* 2012;21(3):259-62
6. Waters RL, Adkins RH: The effects of removal of bullet fragments retained in the spinal canal. A collaborative study by the national spinal cord injury model systems. *Spine* 1991;16(8): 934-939.
7. Pippal SK, Soni S, Asif SK, Bhadoria S. An extraordinary case of ricochet gunshot injury in the head & neck region with an atypical bullet trajectory—a case report. *World articles in ear, nose and throat*, 2009 Vol 2–1 Available at <http://www.waent.org>
8. Committee on Trauma, American Collage of Surgeons. *Advanced Trauma Life Support Instructors Manual American Collage of Surgeons, Chicago* 2005