

A novel method for treatment of persistent colorectal anastomotic strictures: Magnetic compression strictureplasty

Tekrarlayıcı kolorektal anastomoz striktürlerinin tedavisinde yeni bir teknik: Manyetik kompresyon striktüroplasti

Ali Kılıç¹, Abdullah Şişik¹

¹ Department of General Surgery, University of Health Sciences, Umraniye Education and Research Hospital, Istanbul, Turkey

ORCID ID of the author(s)

AK: 0000-0002-4948-0055
AŞ: 0000-0002-7500-8651

Abstract

Aim: Colonic anastomotic strictures are usually caused by staple use, anastomotic leakage, intestinal or suture line ischemia and radiotherapy. Endoscopic treatments should be the first choice. Resection of the stricture line and re-anastomosis form the basis of surgical treatment. Compared to endoscopic approaches, the morbidity rate of surgical treatments for strictures are higher. In patients with stricture and history of multiple pelvic surgeries who don't allow endoscopic treatments, magnetic compression strictureplasty (MCS) may be a good choice for lower morbidity.

Methods: The study population included patients with colorectal anastomotic stricture who had failed endoscopic treatments and for whom a tertiary resection and anastomosis was also considered as having high morbidity. Firstly, the MCS technique was planned by colonoscopic approach. It was aimed to place the magnet proximal to the stenotic colon with the colonoscope, which has a ring-shaped magnet attached at the tip, through the ileostomy entrance. This endoscopic approach failed. Then, laparotomy was performed. A 1-cm colotomy was performed from the proximal site of the stricture, and the magnet was left inside the intestine. Another magnet was placed distally to stricture from the anus. The two magnets were observed to compress the stricture by magnetic attraction, and the operation was terminated. Patient demographics, surgical history, MRI results, colonoscopic examination results were recorded. The follow-up conditions of the patients were noted.

Results: MCS was performed on two male patients mean aged 70 (14.14) years. All patients had multiple abdominal surgeries in their surgical history. Colonoscopy showed fully obstructing anastomotic stricture in patients. The mean distance from the anal verge to the stricture in colonoscopic examination was 7±1.41 cm. Mean stricture length in MRI was 12±2.82 mm. In follow up, control rectosigmoidoscopies revealed that the magnets had fallen into the rectum lumen and the stricture line was fully patent for all patients.

Conclusion: MCS might be preferred as a safe surgical technique with low morbidity in patients with previous multiple colorectal surgeries and a full obstructive stricture in the colorectal anastomosis line.

Keywords: Stricture, Magnet, Low-Morbidity, Low anterior resection, Redo surgery

Öz

Amaç: Anastomoz kaçakları, anastomozun stapler ile yapılmış olması, anastomoz hattında oluşan iskemi ve radyoterapi uygulamaları kolonik anastomotik darlıkların en önemli sebepleridir. Striktür tedavisinde endoskopik girişimler ilk tercih olmalıdır. Striktür hattının rezeksiyonu ve yeniden anastomoz cerrahi tedavinin temelini oluşturur. Endoskopik yaklaşımlarla karşılaştırıldığında, darlıklara yönelik cerrahi tedavilerin morbidite oranı daha yüksektir. Endoskopik tedavilere izin vermeyen darlık ve çoklu pelvik cerrahi öyküsü olan hastalarda, manyetik kompresyon striktüroplastisi (MCS) düşük morbidite için iyi bir seçim olabilir.

Yöntemler: Çalışma popülasyonu kolorektal anastomotik darlığı olan ilave bir rezeksiyon-anastomoz girişiminin yüksek morbiditeye sahip olduğu ve endoskopik tedavilerin başarısız olduğu hastaları içermektedir. İlk olarak MCS yöntemi kolonoskopik olarak planlandı. İleostomi açıklığından girerek ucunda halka şeklinde bir mıknatıs olan kolonoskop ile mıknatısın kolondaki darlığın proksimaline yerleştirilmesi hedeflendi. Bu endoskopik girişim başarısız oldu. Daha sonra hastalara laparotomi yapıldı. Striktürün proksimal bölgesinden yapılan 1 cm'lik kolotomiden sirküler yapıda 1,5 cm çaplı mıknatıs bağırsağın içine bırakıldı. Anüsten de striktürün distaline başka bir mıknatıs yerleştirildi ve iki mıknatısın, manyetik çekimle striktüre kısmı sıkıştırarak birbirine yapıştığı gözlemlendi ve ameliyat sonlandırıldı. Hastaların demografik bilgileri, cerrahi geçmişleri, MRG sonuçları, kolonoskopik muayene sonuçları kaydedildi. Hastaların postoperatif takip bilgileri kaydedildi.

Bulgular: İki erkek hastaya MCS uygulandı. Yaş ortalaması 70 (14,14) saptandı. Tüm hastalar daha önce geçirilmiş multipl abdominal cerrahi öyküsüne sahipti. Kolonoskopide, hastalarda tamamen tıkanmış anastomotik darlık gözlemlendi. Kolonoskopik incelemede anal girimden striktüre olan ortalama mesafe 7±1,41 cm saptandı. Manyetik rezonans görüntülemeye ortalama striktür uzunluğu 12±2,82 mm saptandı. Postoperatif takipte kontrol rectosigmoidoskopide mıknatısların rektum lümenine düştüğü ve darlık hattının tamamen açıldığı gözlemlendi.

Sonuç: MCS, daha önce multipl kolorektal cerrahi geçirmiş olan ve kolorektal anastomoz hattında tam tıkaçıcı striktüre sahip hastalarda güvenli ve düşük morbiditeli bir cerrahi teknik olarak tercih edilebilir.

Anahtar kelimeler: Striktür, Mıknatıs, Düşük morbidite, Aşağı anterior rezeksiyon, Redo cerrahi

Corresponding author/Sorumlu yazar:

Abdullah Şişik

Address/Adres: Sağlık Bilimleri Üniversitesi,
Ümraniye Eğitim ve Araştırma Hastanesi, Genel
Cerrahi Kliniği, Elmalıkent Mh. Adem Yavuz Cad.,
34766, İstanbul, Türkiye
e-Mail: abduallahsisik@gmail.com

Ethics Committee Approval: All procedures in this study involving human participants were performed in accordance with the 1964 Helsinki Declaration and its later amendments.

Etik Kurul Onayı: İnsan katılımcıların katıldığı çalışmalardaki tüm prosedürler, 1964 Helsinki Deklarasyonu ve daha sonra yapılan değişiklikler uyarınca gerçekleştirilmiştir.

Conflict of Interest: No conflict of interest was declared by the authors.

Çıkar Çatışması: Yazarlar çıkar çatışması bildirmemişlerdir.

Financial Disclosure: The authors declared that this study has received no financial support.

Finansal Destek: Yazarlar bu çalışma için finansal destek almadıklarını beyan etmişlerdir.

Published: 5/21/2020

Yayın Tarihi: 21.05.2020

Copyright © 2020 The Author(s)

Published by JOSAM

This is an open access article distributed under the terms of the Creative Commons Attribution-NonCommercial-NoDerivatives License 4.0 (CC BY-NC-ND 4.0) where it is permissible to download, share, remix, transform, and build upon the work provided it is properly cited. The work cannot be used commercially without permission from the journal.



Introduction

Benign anastomotic strictures on the anastomotic line after colorectal surgery lead to lumen narrowing. These strictures are usually caused by staple use, anastomotic leakage, intestinal or suture line ischemia and radiotherapy [1,2]. The diagnosis of strictures in a patient is based on the clinical findings of partial or complete intestinal obstruction, the presence of stenosis that does not allow the passage of a colonoscope and the thickening of the anastomotic line on radiological examinations [3]. Benign anastomotic strictures occur in 2%–7% of patients after colonic anastomoses and may range from 5% to 22% in colorectal anastomoses performed using staples [4-6]. Strictures lead to serious clinical conditions requiring endoscopic treatments or multiple surgical treatments in the majority of patients. Surgical procedures increase the morbidity of the disease.

Surgical treatments for strictures in colonic anastomoses include resection of the stricture line and re-anastomosis. Endoscopic treatment methods such as balloon dilation and stent application should be preferred in patients with partially obstructing strictures through which a guidewire can be passed [6]. In patients with complete obstruction, surgical resection and re-anastomosis are the only alternatives.

Various studies in the literature report performance of magnetic strictuoplasty in anastomotic strictures after upper gastrointestinal (GI) surgery [7]. In this study, we aimed to define a new surgical technique based on creating an anastomosis with magnetic attraction for stenosis in the colonic anastomosis line.

Materials and methods

Patients with a fully obstructing anastomotic stricture and a history of low anterior resection were included the study. Surgical histories of the patients were recorded. Magnetic resonance imaging (MRI) and colonoscopic examination were performed in all patients preoperatively. Stricture length in MRI, the distance from anal verge to stricture in colonoscopic examination and follow up results were noted. All patients were treated with MCS.

Patients

We operated two male patients with ages of 80 and 60 years during the study period. Both patients had multiple colorectal surgeries due to anastomotic leakage after low anterior resection surgery. Final colorectal anastomoses of the patients were performed with circular staples. Colonoscopy showed fully obstructing anastomotic stricture which did not allow even a guidewire to pass in both patients (Figure 1). The distance from the anal verge to stricture in colonoscopic examination was 7 (1.41) cm. Stricture length in MRI was 12 (2.82) mm (Figure 2) (Table 1).

Surgical technique

Patients were scheduled for MCS, which was initially attempted colonoscopically. A neodymium magnet ring with a diameter of 15-mm was attached to the tip of the colonoscope and advanced distally through the ileostomy entrance (Figure 3). This colonoscopic procedure failed due to the dense fecal content of the ascending colon, and the ileocecal valve contraction. Therefore, the patients underwent laparotomy. A 1-cm colotomy

was performed proximally to the stricture, and the magnet was left inside the intestine. Another magnet was placed distally to the stricture through the anus, and the two magnets were observed to compress the stricture by magnetic attraction. After primary closure of the colotomy, the surgery was terminated.

Statistical analysis

Statistical analysis was performed using IBM SPSS Statistics for Windows, version 22.0 (IBM, Armonk, NY, USA). Variables were expressed as mean (standard deviations [SD]) or as medians (range) depending on their distribution, and categorical variables were expressed as frequencies and percentages.

Table 1: Patients characteristics who were treated with magnetic compression strictuoplasty

Demographics	
Age, mean (SD)	70 (14.14)
Gender, male/female	2/0
Surgical History	
Patient 1	-Low anterior resection due to benign colorectal disease -Resection of anastomotic segment and re-anastomosis and diverting ileostomy due to anastomotic stricture (four months after the first surgery)
Patient 2	-Low anterior resection due to rectum tumor -Hartmann colostomy due to anastomotic leakage (Ten days after the first surgery) -Colostomy closure with diverting ileostomy (After adjuvant treatment)
Colonoscopic findings	Fully obstructing stricture in the colorectal anastomotic area
Stricture length in MRI, mean (SD), (min-max), (mm)	12 (2.82) (10-14)
The distance from anal verge to stricture in colonoscopic examination, mean (SD), (min-max), (cm)	7 (1.41) (6-8)

SD: standard deviation, MRI: magnetic resonance imaging

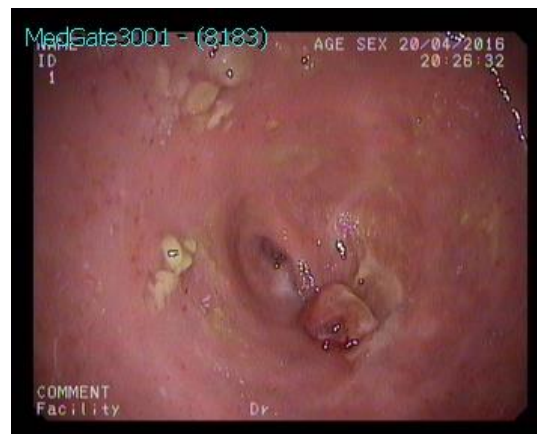

Figure 1: Colonoscopic appearance of strictured colonic segment

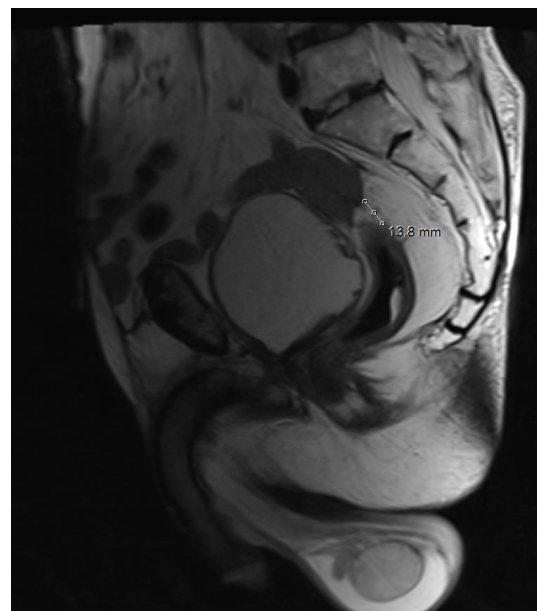


Figure 2: Magnetic resonance imaging of strictured colonic segment




Figure 3: Image of circular mid-spaced magnet with a 15-mm diameter

Results

In the first postoperative week, control rectosigmoidoscopy showed that the lumen was completely patent (Figure 4). Due to the pressure exerted by the magnets on the stricture line, the stricture line had dissolved, and the magnets were free in the lumen. An endoscopic examination performed on the first postoperative month revealed that the anastomotic line was patent. One of the patients needed a fully covered stent placement due to slightly narrowing. The stent was removed after 4 weeks. Both ileostomies were closed on postoperative third month uneventfully following rectosigmoidoscopic examination.

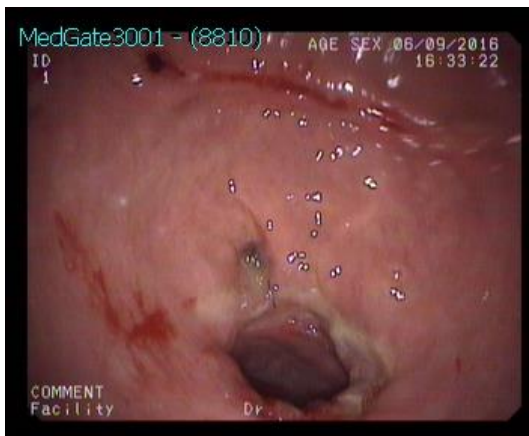

Figure 4: Colonoscopic appearance after magnetic compression strictuoplasty

Discussion

Anastomotic strictures usually develop after colorectal surgery secondary to ischemia, leakage, inflammation, or hemorrhage from anastomosis. The majority are observed in the first 6 months after surgery [8,9]. Some researchers have argued that the possibility of a stricture increases when anastomoses are performed using a stapler [10]. Literature suggests treating anastomotic strictures through which a colonoscope cannot pass proximally [8]. In both of our cases, the strictures were fully obstructive. Endoscopic procedures should be the primary choice of treatment for anastomotic strictures, and surgical treatment should be considered when endoscopic procedures fail. Endoscopic dilatation with a balloon or stent application requires passing a guidewire proximally through the stricture. However, it is not possible to apply these treatment modalities in completely obstructing strictures.

Surgical treatments for strictures include resection of the stricture and re-anastomosis of the remaining bowel. Repeated resection of the stricture line and re-anastomosis are often technically very difficult and highly morbid, particularly if the patient has undergone more than one surgical procedure in the same region in pelvic strictures. The first patient in our study

had undergone two resections and anastomoses in the distal pelvic region and stricture had recurred. In the second patient, anastomosis was performed twice in the distal pelvic region due to tumor resection and colostomy closure and stricture had developed in the anastomotic line. Similar to our case, in patients with a history of multiple pelvic anastomoses, resection and anastomosis may lead to several problems. In these patients, reaching the pelvic region may not be possible and bleeding may occur during adhesiolysis. The reliability of reconstructed anastomoses will also decrease. There is also the possibility of recurrent strictures in the new anastomotic line. For the reasons mentioned, applying MCS in this group of patients to may reduce morbidity and make surgical technique easier. The principle of this magnet-involved strictuoplasty technique compresses the stricture by the magnetic attraction of the magnets placed distally and proximally to the stricture, inducing ischemia in this area. We believe that the technique with which we achieved successful results in both of our cases can be improved by conducting studies in a selected, wider group of patients.

Limitations

Nevertheless, the current study has some limitations. The first of these restrictions is the limited number of patients in our study. Since we recommend the applicability of MCS in selected patients, we believe that we will achieve more effective results over time by applying this technique to more patients. In addition, while planning our technique, although it was intended to place the proximal magnet colonoscopically, we achieved this by laparotomy due to the stool content of the ascending colon and ileocecal valve stenosis, as we noted in this article. We think this is the developable side of the MCS technique.

Conclusion

Consequently, in patients with colorectal anastomotic strictures and previous multiple colorectal anastomosis histories, MCS can be performed instead of re-resection and re-anastomosis, which has more morbidity in case of unsuccessful endoscopic interventions.

Acknowledgments

The authors gratefully thank Dr. Sırma Tilev for assistance in the editing of the manuscript.

References

1. Chung RS, Hitch DC, Armstrong DN. The role of tissue ischemia in the pathogenesis of anastomotic stricture. *Surgery*. 1988;104:824-9.
2. Polglase AL, Hughes ES, McDermott FT, Pihl E, Burke FR. A comparison of end-to-end stapler and suture colorectal anastomosis in the dog. *Surg Gynecol Obstet*. 1981;152:792-6.
3. Kan H, Furukawa K, Suzuki H. An improvement in the quality of life after performing endoscopic balloon dilatation for postoperative anastomotic stricture of the rectum. *J Nippon Med Sch*. 2007;74:418-23.
4. Weinstock LB, Schatz BA. Endoscopic alternatives in the management of the anastomosis following resection of colonic neoplasm. *Gastrointest Endosc*. 1994;40:558-61.
5. Tuson JR, Everett WG. A retrospective study of colostomies, leaks and strictures after colorectal anastomosis. *Int J Colorectal Dis*. 1990;5:44-8.
6. Mukai M, Kishima K, Lizuka S. Endoscopic hook knife cutting before balloon dilatation of severe anastomotic stricture after rectal cancer resection. *Endoscopy*. 2009;41:193-4.
7. Woo R, Wong CM, Trimble Z, Puapong D, Koehler S, Miller S, et al. Magnetic Compression Strictuoplasty For Treatment of Refractory Esophageal Strictures in Children: Technique and Lessons Learned. *Surg Innov*. 2017;24:432-9.
8. Delaunay-Tardy K, Barthelemy C, Dumas O, Balique JG, Audigier JC. Endoscopic therapy of benign colonic post-operative strictures: report on 27 cases. *Gastroenterol Clin Biol*. 2003;27:610-3.
9. Hirono S, Ueno M, Takifuji K, Onishi H, Tani M, Uchiyama K, et al. Successful interventional dilatation of a complicated stricture of the anastomotic colon: report of a case. *Int Surg*. 2007;92:311-3.
10. Pietropaolo V, Masoni L, Ferrara M, Montori A. Endoscopic dilation of colonic postoperative strictures. *Surg Endosc*. 1990;4:26-30.

This paper has been checked for language accuracy by JOSAM editors.

The National Library of Medicine (NLM) citation style guide has been used in this paper.