

KERATOKONUSLU HASTALARDA ÖN SEGMENT PARAMETRELERİNİN PENTACAM CİHAZI İLE DEĞERLENDİRİLMESİ

EVALUATION OF ANTERIOR SEGMENT PARAMETERS IN PATIENTS WITH KERATOCONUS WITH PENTACAM DEVICE

Murat KAŞIKÇI¹, Özgür EROĞUL², Leyla ERYİĞİT EROĞUL³

¹Muğla Sıtkı Koçman Üniversitesi Eğitim ve Araştırma Hastanesi, Göz Hastalıkları Ana Bilim Dalı

²Afyonkarahisar Sağlık Bilimleri Üniversitesi Tıp Fakültesi, Göz Hastalıkları Ana Bilim Dalı

³Afyonkarahisar Devlet Hastanesi, Göz Hastalıkları Ana Bilim Dalı

ÖZET

AMAÇ: Keratokonus hastalarında hastalığın şiddetine göre ön segment parametrelerinde gözlenen değişikliklerin Pentacam cihazı kullanılarak değerlendirilmesi ve elde edilen ölçümlerin sağlıklı bireylerden elde edilen ölçümler ile karşılaştırılması amaçlanmıştır.

GEREÇ VE YÖNTEM: Elli iki keratokonus hastasının 104 gözü ile 60 sağlıklı bireyin 120 gözüne ait Pentacam cihazı verileri retrospektif olarak değerlendirildi. Hastaların demografik özellikleri, korneal ön yüzey ve arka yüzeye ait kurvatür, asferite ve elevasyon değerleri (K1, K2, korneal astigmatizma ve ortalama asferite) ile en ince korneal kalınlık (TCT), apeks korneal kalınlık (ACT), korneal volüm (CV), ön kamara derinliği (ACD), ön kamara açısı (ACA) ve ön kamara volümü (ACV) değerleri kaydedildi.

BULGULAR: Keratokonus grubunda (22 Kız, 30 Erkek) ortalama yaş 30.8 ± 11.6 yıl, kontrol grubunda (26 Kız, 34 Erkek) 32.4 ± 12.4 yıl idi. Gruplar yaş ve cinsiyet açısından uyumlu idi (sırasıyla $p=0.32$, $p=0.89$). Keratometri değerlerine göre yapılan sınıflamaya göre keratokonus seviyesi 63 göz hafif, 26 göz orta ve 15 gözde ağır keratokonus olarak gruplandı. Keratokonus hastalarında gruplar arasında korneal ön yüzey ve arka yüzeye ait kurvatür, asferite ve elevasyon değerlerinde anlamlı fark bulundu ($p<0.001$). TCT hafif grupta en yüksek, ağır grupta en düşük saptandı ve gruplar arasındaki fark anlamlı idi ($p<0.05$). ACD hafif grupta 3.21 ± 0.34 , orta grupta 3.27 ± 0.26 ve ağır grupta ise 3.79 ± 0.53 idi ve aradaki fark anlamlı bulundu ($p<0.05$).

SONUÇ: Keratokonus progresyonu ile korneal ön yüzey ve arka yüzeye ait kurvatür, asferite ve elevasyon değerleri ile kornea ön segment parametrelerinde anlamlı değişiklikler gözlenmektedir.

ANAHTAR KELİMELER: Ön segment parametreleri, Asferisite, Kornea topografisi, Düzensiz astigmatizm, Keratokonus

ABSTRACT

OBJECTIVE: It was aimed to evaluate the changes observed in the anterior segment parameters in patients with keratoconus using Pentacam device according to the severity of the disease and to compare the determined results with those obtained from the healthy individuals.

MATERIAL AND METHODS: The data obtained by the Pentacam device for 104 eyes of 52 keratoconus patients and 120 eyes of 60 healthy individuals were retrospectively evaluated. Demographic features of the patients, the corneal curvature of the anterior and posterior surface, the asphericity and the elevation values (K1, K2, corneal astigmatism, and average asphericity), thinnest corneal thickness (TCT), apex corneal thickness (ACT), corneal volume (CV), anterior chamber depth (ACD), anterior chamber angle (ACA), and anterior chamber volume (ACV) outcomes were recorded.

RESULTS: The average age was 30.8 ± 11.6 years in the Keratoconus group (22 Female, 30 Male) and 32.4 ± 12.4 years in the control group (26 Female, 34 Male). The groups were compatible with each other in terms of age and gender ($p=0.32$, $p=0.89$, respectively). In the classification based on keratometry readings, keratoconus level was grouped as mild in 63 eyes, medium in 26 eyes, and severe in 15 eyes. In keratoconus patients, there was a significant difference in curvature, asphericity, and elevation values of the corneal anterior and posterior surfaces between the groups ($p<0.001$). TCT was the highest in the mild group and lowest in the severe group, and the difference between the groups was significant ($p<0.05$). ACD was 3.21 ± 0.34 in the mild group, 3.27 ± 0.26 in the medium group, and 3.79 ± 0.53 in the severe group, and the difference was also significant ($p<0.05$).

CONCLUSIONS: Significant changes in the values of curvature, asphericity, and elevation of both corneal anterior and posterior surfaces and the parameters of the anterior segment of the cornea are observed with the progression of keratoconus.

KEYWORDS: Anterior segment parameters, Asphericity, Corneal topography, Irregular astigmatism, Keratoconus

Geliş Tarihi / Received: 12.06.2020

Kabul Tarihi / Accepted: 05.10.2020

Yazışma Adresi / Correspondence: Dr. Öğr. Üyesi Özgür EROĞUL

Afyonkarahisar Sağlık Bilimleri Üniversitesi Tıp Fakültesi, Göz Hastalıkları Ana Bilim Dalı

E-mail: ozgureroğul0342@gmail.com

Orcid No (Sırasıyla): 0000-0002-2748-9702, 0000-0002-0875-1517, 0000-0003-3622-2089

INTRODUCTION

Keratoconus is a disease characterized by progressive corneal thinning that results in the tapering of the cornea, irregular astigmatism, and decreased vision (1). Its incidence varies depending on various factors such as ethnicity and criteria used for diagnosis; its frequency in the general population is seen as 1/2000 and affects the young population in particular (2).

Because there are myopic changes in the early stages of the disease, glasses are sufficient for treatment. With the progression of the disease, increase in ectasia and tapering in the cornea increase irregular astigmatism, and at this stage, rigid gas permeable (RGP) contact lenses are used for treatment (3, 4). In cases that cannot tolerate the contact lens, intra-stromal ring segments may be used (5). Crosslinking treatment may be applied using ultraviolet-A ray and riboflavin to stop progression in advanced cases (6). A corneal transplant may be a treatment option for very advanced cases.

It is not difficult to diagnose moderate and advanced keratoconus patients with classical clinical and topographic findings, but the diagnosis of subclinical cases is difficult (7). This condition is especially important in pre-operative refractive assessment. Refractive surgery for subclinical keratoconus patients may cause ectasia disorders and progressive keratectasia in patients (8). The corneal topography device with Scheimpflug camera system is frequently used in the diagnosis of keratoconus today and provides an evaluation of the corneal anterior and posterior surfaces and anterior segment parameters. It is a valuable tool to support and verify the diagnosis in suspicious cases of keratoconus (9, 10).

This study aims to evaluate the changes observed in the anterior segment parameters with Pentacam Scheimpflug camera in patients with keratoconus according to the severity of the disease and compare the outcomes with those obtained from healthy individuals.

MATERIAL AND METHOD

Data of 104 eyes of 52 patients who were diagnosed with keratoconus and did not use contact

lenses in the cornea unit of Muğla Sıtkı Koçman University Training and Research Hospital Ophthalmology Outpatient Clinic were obtained with Pentacam Scheimpflug camera. As the control group, the data obtained with the Pentacam Scheimpflug camera of 120 eyes of 60 healthy emmetropic individuals who were examined in the ophthalmology clinic of our hospital and were not diagnosed with keratoconus were evaluated retrospectively. Patients with corneal disease other than keratoconus, those with a history of ocular surgery or ocular trauma, those with a corneal scar or opacity, and those who could not adapt to topographic imagination were excluded from the study.

Following routine ophthalmological examination to all patients and the healthy individuals, corneal topographic imagination was performed with the Scheimpflug camera system (Pentacam HR, Oculus Inc. Germany). Keratoconus was diagnosed in the presence of at least one of the Vogt's striae, Fleisher ring, Munson's sign, Descemet cracks, subepithelial fibrosis, and apical scar findings in biomicroscopic examination with asymmetric bow-tie appearance or paracentral steepness in corneal topography (9). Eyes with keratoconus were classified in 3 groups according to the average keratometry values (those less than 47 D were in the mild group (Group 1), those between 47 - 52 D were in the medium group (Group 2), those more than 52 D were in the severe group (group 3)).

Anterior segment parameters of all cases were evaluated with the Pentacam device. Demographic features of the patients, the corneal curvature of the anterior and posterior surface, the asphericity and the elevation values (K1, K2, corneal astigmatism, and average asphericity), thinnest corneal thickness (TCT), apex corneal thickness (ACT), corneal volume (CV), anterior chamber depth (ACD), anterior chamber angle (ACA), and anterior chamber volume (ACV) values were recorded.

Statistical analysis was done using SPSS 18.0 Windows version software (SPSS, Chicago, Illinois, USA). The distribution of the data was evaluated by the Kolmogorov-Smirnov test. In the comparison of the data, independent samples t-test and one-way ANOVA test were used in

the data showing normal distribution, and the Mann-Whitney U test and Kruskal Wallis tests were used in the comparison of the data without normal distribution. A Chi-square test was used to evaluate categorical data. Also, $p < 0.05$ was considered statistically significant.

Ethical Committee

The study protocol complied with the ethical principles of the Declaration of Helsinki and received full approval from the institutional review boards of Muğla Sıtkı Koçman University Ethics Committee (no.2020/ 02-VII).

RESULTS

The mean age of 52 keratoconus patients (22 W, 30 M) included in the study was 30.8 ± 11.6 years. The mean age of 60 healthy emmetrope individuals (26 W, 34 M) in the control group was 32.4 ± 12.4 years, and the two groups were compatible with each other in terms of age and gender ($p = 0.32$, $p = 0.89$, respectively).

In the classification based on keratometry values, there were 63 eyes in the group 1 with less than 47 D, 26 eyes in the group 2 with 47 - 52 D, and 15 eyes in the group 3 with more than 52 D. The keratometry and anterior segment values in all groups were summarized in **Table 1**.

Table 1: Anterior segment and keratometry values detected in keratoconus patients and control group

	KKn n=104	Group1 n=63	Group2 n=26	Group3 n=15	Control n=120	p1	p2
K1	45.8±3.8	43.5±1.5	47.3±1.6	53.4±1.8	42.8±1.5	<0.001	<0.001
K2	49.3±4.8	46.4±1.9	51.5±2.0	58.4±2.6	43.9±1.6	<0.001	<0.001
Km	47.4±4.2	44.8±1.5	49.3±1.6	55.8±1.9	43.4±1.5	<0.001	<0.001
K1post	-6.71±0.94	-6.25±0.37	-6.85±0.77	-8.49±0.71	-6.10±0.25	<0.001	<0.001
K2post	-7.15±3.34	-6.96±0.44	-7.75±0.52	-9.33±0.63	-6.45±0.29	0.03	<0.001
Kmpost	-7.23±2.01	-6.58±0.36	-7.26±0.65	-8.88±0.68	-6.27±0.26	<0.001	<0.001
TCT	453.1±63.4	483.0±43.4	426.6±30.8	365.6±77.0	542.6±30.6	<0.001	<0.001
ACT	471.7±65.9	495.3±52.1	447.5±36.6	407.8±96.6	547.3±30.3	<0.001	<0.001
ACD	3.31±0.41	3.21±0.34	3.27±0.26	3.79±0.53	2.89±0.36	<0.001	<0.001
ACA	38.4±6.1	38.1±5.6	37.8±6.2	40.7±7.5	37.3±6.8	0.18	0.28
CV	57.0±3.8	57.5±3.8	55.5±2.9	57.1±4.9	60.8±3.3	<0.001	0.08
ACV	188.1±35.2	189.4±37.2	180.6±33.8	193.8±26.4	162.7±39.4	<0.001	0.46
Aspher-ant	-0.75±0.39	-0.57±0.22	-0.89±0.36	-1.36±0.40	-0.35±0.14	<0.001	<0.001
Aspher-post	-0.64±2.01	-0.61±0.37	-1.11±0.67	-1.48±0.35	-0.38±0.13	0.15	<0.001

KK: Keratoconus, K1: Flat K, K2: Upright K, Km: Average keratometry, K1 post: Posterior flat K, K2 post: Posterior Upright K, Km Post: Average posterior keratometry, TCT: Total corneal thickness, ACT: Apex corneal thickness, ACD: Anterior chamber depth, ACA: Anterior chamber angle, CV: Corneal volume, ACV: Anterior chamber volume, p1: Comparison between keratoconus patients and control patients, p2: Comparison between keratoconus patients (Group 1-Group2-Group3)

According to this, there was a statistically significant difference between the keratoconus group and the control group in all values ($p < 0.05$) except ACA ($p = 0.18$) and posterior asphericity ($p = 0.15$). When groups of keratoconus patients were compared, there was a significant difference in curvature, asphericity, and elevation values of the corneal anterior and

posterior surfaces ($p < 0.001$). TCT and ACT were the highest in the mild group and lowest in the severe group, and the difference between the groups was significant ($p < 0.05$) (**Figure 1, 2**).

ACD was 3.21 ± 0.34 in the mild group, 3.27 ± 0.26 in the medium group, and 3.79 ± 0.53 in the severe group, and the difference was significant ($p < 0.001$). There was no significant difference in CV, ACV, and ACA measurements between the groups ($p > 0.05$).

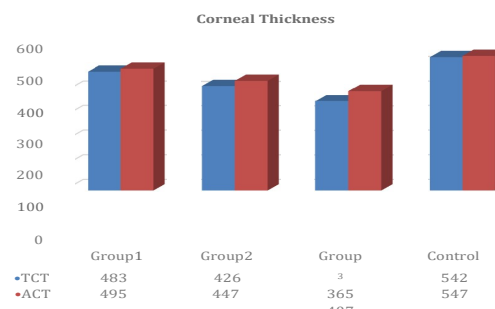


Figure 1: The total corneal thickness and apex corneal thickness values measured in keratoconus patients and control group based on keratometry values

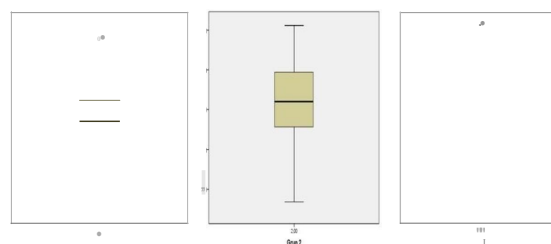


Figure 2: ACD (anterior chamber depth) values in keratoconus patients grouped based on keratometry values

DISCUSSION

In this study, corneal thickness values in advanced keratoconus patients were lower than in early-stage and mid-stage keratoconus patients, while ACD was higher. Corneal anterior and posterior surface curvature and asphericity values of keratoconus patients were significantly different according to the severity of the disease.

Accurate and reliable measurement of curvature and asphericity values of corneal anterior and posterior surface and anterior segment parameters are important in both diagnosis of keratoconus and success of refractive surgery (11). Pentacam device with Scheimpflug camera system which helps determine the diagnosis of keratoconus and stage of keratoconus is a non-invasive, fast, reliable, repeatable, easy to

shoot, and easy to learn for a technician, and provides the evaluation of corneal anterior and posterior surfaces and anterior segment parameters (12). Adding elevation maps to curvature maps increases topographic sensitivity in determining corneal shape anomalies such as early ectasia (13).

Progressive thinning of the cornea is a well-known feature of the pathophysiology of keratoconus (14). The value of the thinnest corneal thickness (TCT) is one of the most important factors in keratoconus detection and follow-up (15). In refractive surgeries, TCT is also considered an important parameter in screening and following candidates (16). Previous studies have shown that clinical keratoconus can cause ectatic progression after refractive surgery in its early stages and preclinical stages (17, 18). To better distinguish between the early stages of keratoconus and healthy eyes, several parameters with high sensitivity and specificity have been identified in the literature. Corneal pachymetry, corneal volume, anterior-posterior form, and anterior-posterior surface deviations have been reported to be used as correct parameters to detect keratoconus (19, 20). Similar to the literature, TCT and ACT values which were lower in the eyes with keratoconus than those in the control group decreased following keratoconus progression (19). These findings support the literature revealing that in the preclinical or early stages of the disease, corneal thinning in the peripheral area is accompanied by no tissue loss and only by minor changes in keratocyte orientation (19).

The Pentacam system can evaluate the cornea and anterior segment of the eye from the anterior surface of the cornea to the posterior surface of the lens (9). ACD is one of the main parameters evaluated in the Pentacam device. In our study, ACD was 3.21 ± 0.34 in the mild group, 3.27 ± 0.26 in the medium group, and 3.79 ± 0.53 in the severe group, and the difference was significant. Even in eyes with mild keratoconus, ACD was significantly deeper than those in the control group, and depth increased progressively as the disease progressed. In our study, the mean ACD difference between severe and mild keratoconus groups was 0.58 mm. In our study,

the increase in ACD was greater than the increase in TCT. The anterior protrusion of the corneal center was thought to be a source of this increase and difference. Accurate measurement of anterior camera depth has great importance in implantation of phakic intraocular lenses, and there are studies reporting that phakic intraocular lenses are quite successful in correcting astigmatism and spherical errors in patients with keratoconus (21, 22). Similarly, in a recent study, it was stated that intracorneal ring segments and phakic toric implantable lenses are effective methods based on the effect of reducing optic abnormalities in patients with keratoconus (23). Çağıl et al. (24) compared corneal volume (CV) in keratoconus patients, subclinical keratoconus patients, and normal control subjects and showed that this parameter helps to distinguish keratoconus from normal eyes, but no distinction can be made between keratoconus and subclinical keratoconus. Emre et al. (25) found that CV decreased as the disease progressed in keratoconus patients. In our study, there was a significant difference in corneal volume between the patient and control group, while there was no significant difference between the patient groups. This may be because the number of cases is limited. CV value is extremely important in intracorneal ring (INTACS) implantation, which is an alternative surgical method in patients with transparent corneas who are not satisfied with their glasses or contact lenses (26).

There was no significant difference between the groups when the ACA was evaluated. In previous studies, it has been reported that the peripheral cornea becomes straighter in eyes with keratoconus, so the ACA is narrowed (27).

In our study, we found a significant difference only in corneas with severe keratoconus compared to the control group, and the anterior camera angle ACA was narrower in corneas with keratoconus than the control group.

It was emphasized that anterior corneal elevation, as well as posterior corneal elevation, plays a very important role in distinguishing eyes with keratoconus and subclinical keratoconus (9). In the present study, we observed that anterior corneal asphericity and posterior asphericity re-

sults in eyes with keratoconus were significantly different between mild, moderate and severe keratoconus patients. This result supports the idea that anterior and posterior corneal asphericity values can be used together with other parameters in the diagnosis and staging of keratoconus (9, 28). In the study conducted by Sarfzadeh and Nasiri with a total of 225 eyes of 225 individuals, including 41 suspected KC, 40 mild KC, 71 moderate KC, 48 severe KC; stated that posterior corneal height, corneal thickness and high-grade aberrations are important indicators to be considered to diagnose different degrees of keratoconus (29).

In a recent study in our country; It has been stated that with Pentacam Scheimpflug tomography analysis, most, if not all, subclinical keratoconus cases can be detected, and the detection of increased corneal light back distribution may be a more sensitive way to identify keratoconus in its early stages (30). In the same study, it was stated that the increase in densitometry in the central zone could be useful in detecting subclinical keratoconus (30).

In current approaches to the detection of subclinical keratoconus; There are studies conducted with diagnostic values of morphogeometric parameters. In a study conducted in 2020; It has been stated that the severity level of the disease can be characterized by measuring the 3-dimensional structural changes in keratoconus by using new morphogeometric indices developed considering the location and spatial projection of the anterior and posterior corneal apex and the minimum corneal thickness points (31).

As a result, although keratoconus looks like a type of deformity of the cornea, it requires diagnosis and follow-up with many corneal and anterior segment parameters, provides early recognition of the disease with devices developed in recent years and requires high-level devices that guide physicians in treatment. In this context, the Pentacam device is an important tool for diagnosis and follow-up with its sensitive, reliable, and repeatable properties. Longer and detailed studies are needed to understand the changes in keratoconus earlier and more clearly.

REFERENCES

1. Arnalich-Montiel et al. Corneal surgery in keratoconus: which type, which technique, which outcomes? *Eye and Vision*. 2016;3(2):1-14.
2. Najmi H, Mobarki Y, Mania K et al. The correlation between keratoconus and eye rubbing: a review. *Int J Ophthalmol*. 2019; 12(11):1775-1781.
3. Barnett M, Mannis MJ. Contact lenses in the management of keratoconus. *Cornea*. 2011;30(12):1510-6.
4. Nilagiri VK, Metlapally S, Kalaiselvan P, Schor MC, Bhadravaj RS. LogMAR and Stereoacuity in Keratoconus Corrected with Spectacles and RGP Contact Lenses. *Optom Vis Sci*. 2018; 95(4): 391-398.
5. Kubaloglu A, Sari ES, Cinar Y, Koytak A, Kurnaz E, Özer Türk Y. Intrastromal corneal ring segment implantation for the treatment of keratoconus. *Cornea*. 2011;30(1):11-7.
6. Mazzotta C, Caporossi T, Denaro R, et al. Morphological and functional correlations in riboflavin UV A corneal collagen cross-linking for keratoconus. *Acta Ophthalmol*. 2012;90:259-265.
7. Barr JT, Wilson BS, Gordon MO, et al. CLEK Study Group. Estimation of the incidence and factors predictive of corneal scarring in the Collaborative Longitudinal Evaluation of Keratoconus (CLEK) Study. *Cornea*. 2006;25(1):16-25.
8. Santhiago MR, Giacomini NT, Smadja D, Bechara SJ. Ectasia risk factors in refractive surgery. *Clin Ophthalmol*. 2016;10:713-720.
9. Sanctis U, Loiacono C, Richiardi L, Turco D, Mutani B, Grignolo FM. Sensitivity and specificity of posterior corneal elevation measured by Pentacam in discriminating keratoconus/ subclinical keratoconus. *Ophthalmology*. 2008; 115:1534-1539.
10. Huseynli S, Borges JS and Alio LJ. Comparative evaluation of Scheimpflug tomography parameters between thin non-keratoconic, subclinical keratoconic, and mild keratoconic corneas. *European Journal of Ophthalmology*. 2018; 28(5): 521-534.
11. McMahan TT, Szczotka-Flynn L, Barr JT, et al, CLEK Study Group. A new method for grading the severity of keratoconus the Keratoconus Severity Score (KSS). *Cornea*. 2006;25: 794-800.
12. Michael W, Ovette F, Renato R. Tomographic Parameters for the Detection of Keratoconus. *Eye & Contact Lens*. 2014; 40(6):326-330.
13. Vazquez PR, Galletti JD, Minguez N, et al. Pentacam Scheimpflug tomography findings in topographically normal patients and subclinical keratoconus cases. *Am J Ophthalmol*. 2014; 158(1): 32-40.
14. Sherwin T, Brookes NH. Morphological changes in keratoconus: pathology or pathogenesis. *Clin Exp Ophthalmol*. 2004; 32: 211-217.

- 15.** Ucakhan OO, Ozkan M, Kanpolat A. Corneal thickness measurements in normal and keratoconic eyes: pentacam comprehensive eye scanner versus noncontact specular microscopy and ultrasound pachymetry. *J Cataract Refract Surg.* 2006;32(6):970–977.
- 16.** Binder PS, Lindstrom RL, Stulting RD, et al. Keratoconus and corneal ectasia after LASIK. *J Refract Surg.* 2005;21(6):749.
- 17.** Randleman JB, Russell B, Ward MA, Thompson KP, Stulting RD. Risk factors and prognosis for corneal ectasia after LASIK. *Ophthalmology.* 2003;110(2):267–275.
- 18.** Giri P, Azar DT. Risk profiles of ectasia after keratorefractive surgery. *Curr Opin Ophthalmol.* 2017;28(4):337–342.
- 19.** Piñero DP, Alió JL, Alesoñ A, Vergara ME, Miranda M. Corneal volume, pachymetry, and correlation of anterior and posterior corneal shape in subclinical and different stages of clinical keratoconus. *J Cataract Refract Surg.* 2010; 36(5):814–825.
- 20.** Ucakhan OO, Cetinkor V, Ozkan M, Kanpolat A. Evaluation of Scheimpflug imaging parameters in subclinical keratoconus, keratoconus, and normal eyes. *J Cataract Refract Surg.* 2011;37(6):1116–1124.
- 21.** Budo C, Bartels MC, Van Rij G. Implantation of Artisan toric phakic intraocular lenses for the correction of astigmatism and spherical errors in patients with keratoconus. *J Refract Surg.* 2005; 21:218–222.
- 22.** Leccisotti A, Fields SV. Angle-supported phakic intraocular lenses in eyes with keratoconus and myopia. *J Cataract Refract Surg.* 2003; 29:1530–1536.
- 23.** Ramin S, Sangin Abadi A, Doroodgar F, et al. Comparison of Visual, Refractive and Aberration Measurements of INTACS versus Toric ICL Lens Implantation; A Four-year Follow-up. *Med Hypothesis Discov Innov Ophthalmol.* 2018;7:32–39.
- 24.** Çağıl N, Çakmak HB, Uğurlu N, et. al Corneal Volume Measurements with Pentacam for Detection of Keratoconus and Subclinical Keratoconus. *Turk J Ophthalmol.* 2013;43:77–82.
- 25.** Emre S, Doganay S, Yologlu S. Evaluation of anterior segment parameters in keratoconic eyes measured with the Pentacam system. *J Cataract Refract Surg.* 2007;33:1708–1712.
- 26.** Ambrosio R, Alonso RS, Luz A, Coca Velarde LG. Corneal-thickness spatial profile and corneal-volume distribution: tomographic indices to detect keratoconus. *J Cataract Refract Surg.* 2006;32(11):1851–1859.
- 27.** Smolek MK, Klyce SD. Is keratoconus a true ectasia? An evaluation of corneal surface area. *Arch Ophthalmol.* 2000; 118: 1179–1186.
- 28.** Rabsilber TM, Khoramnia R, Auffarth GU. Anterior chamber measurements using Pentacam rotating Scheimpflug camera. *J Cataract Refract Surg.* 2006; 32:456–459.
- 29.** M. Safarzadeh, N. Nasiri. Anterior segment characteristics in normal and keratoconus eyes evaluated with a combined Scheimpflug/Placido corneal imaging device. *Journal of Current Ophthalmology.* 2016; 28: 106–111.
- 30.** Koc M, Tekin K, Tekin MI, et al. An Early Finding of Keratoconus: Increase in Corneal Densitometry. *Cornea.* 2018; 0: 1–7.
- 31.** Velázquez JS, Cavas F, Piñero DP, Cañavate FJ, Barrio JA, Alio J. Morphogeometric analysis for characterization of keratoconus considering the spatial localization and projection of apex and minimum corneal thickness point. *Journal of Advanced Research.* 2020; 24: 261–271.