

11 Yaşında Burkitt Lenfomalı Bir Çocukta Bilateral Adrenal Kitleye Eşlik Eden İnce Bağırsak İnvajinasyonu

Small Intestine Intussusception Accompanying Bilateral Adrenal Mass in an 11 Year-Old Child with Burkitt Lymphoma

Nafiz SARIŞIK¹, Can ACIPAYAM², Ahmet Gökhan GÜLER³, Abdulkadir Yasir BAHAR⁴, Betül KIZILDAĞ⁵, Fatih TEMİZ⁶

¹Department of Pediatrics, Faculty of Medicine, Kahramanmaraş Sutcu Imam University, Kahramanmaraş, Turkey

²Department of Pediatrics, Division of Pediatric Hematology and Oncology, Faculty of Medicine, Kahramanmaraş Sutcu Imam University, Kahramanmaraş, Turkey

³Department of Pediatric Surgery, Faculty of Medicine, Kahramanmaraş Sutcu Imam University, Kahramanmaraş, Turkey.

⁴Department of Pathology, Faculty of Medicine, Kahramanmaraş Sutcu Imam University, Kahramanmaraş, Turkey

⁵Department of Radiology, Faculty of Medicine, Kahramanmaraş Sutcu Imam University, Kahramanmaraş, Turkey.

⁶Department of Pediatrics, Division of Pediatric Endocrinology and Metabolism, Faculty of Medicine, Kahramanmaraş Sutcu Imam University, Kahramanmaraş, Turkey

Geliş Tarihi: 17.03.2019 **Kabul Tarihi:** 31.05.2019 **DOI:** 10.17517/ksutfd.541100

Özet

Gastrointestinal sistem, ektranodal non-hodgkin lenfomaların tutulum gösterdiği yaygın yerlerden biridir. Öte yandan, non-hodgkin lenfomalar ince bağırsakta nadir görülmektedir. Biz, literatürde bilateral adrenal kitle ve ince bağırsak kaynaklı burkitt lenfoma olan nadir bir olguyu sunmak istedik.

11 yaşında erkek hasta akut gelişen karın ağrısı tablosuyla çocuk acil polikliniğine başvurdu. Yapılan Abdominal USG incelemesinde invajinasyon ve bilateral srenal kitle görüldü. Olgu acil ameliyata alındı. Ameliyatta ince bağırsakta 4-5 adet lezyon görüldü. Kısmi bağırsak rezeksiyonu yapıldı. Rezeksiyon materyalinin patoloji sonucu ile hastaya ince bağırsak orijinli Burkitt Lenfoma tanısı konuldu. İnce bağırsak orijinli non-hodgkin lenfomalar genellikle karın ağrısı ile başvurmaktadır, prognozu ise histolojik tip ve dereceye bağlıdır. Olguya NHL-BFM 95 kemoterapi kürü başlandı ve iyi bir klinik yanıt alındı. Kemoterapi kürünün tamamlanmasından sonra olgumuz iki ay boyunca remisyonunda kaldı.

Sonuç olarak, Bilateral adrenal kitlenin eşlik ettiği Burkitt lenfoma oldukça nadir görülmektedir ve bilateral adrenal kitlelerin diğer nedenlerini dışlamak için özen gösterilmelidir. Ayrıca bu olgumuzda bilateral adrenal kitlenin ayırıcı tanısında burkitt lenfoma olduğu vurgulanmıştır.

Anahtar kelimeler: Primer adrenal kitle, Hodgkin olmayan lenfoma, ince bağırsak, invajinasyon

Abstract

Gastrointestinal tract is one of the most common extranodal site involved by non-Hodgkin lymphomas. However, Non-Hodgkin lymphomas are seen less in the small intestine. We present here a rare condition in the literature which is a case of bilateral adrenal masses and Burkitt lymphoma with small intestine origin.

Eleven years old male patient was admitted to pediatric emergency service with acute abdomen. Abdominal USG examination revealed intussusception and bilateral adrenal masses. Emergency surgery was planned. In the surgical operation, five lesions were seen in the small intestine. Partial small intestine resection was performed. The patient was diagnosed as Burkitt Lymphoma with small bowel origin due to pathology of resection material. Non-hodgkin lymphomas with small intestine origin usually present with abdominal pain, and their prognosis depends on histological type and grade. NHL-BFM 95 chemotherapy treatment was initiated and a good clinical response was achieved, and the patient remained in complete remission for two months after completion of chemotherapy.

In conclusion, Bilateral adrenal masses remain a rare form of Burkitt lymphoma and care must be taken in ruling out other causes of bilateral adrenal masses.

Furthermore, with this case, we emphasize that Burkitt lymphoma should be considered in differential diagnosis of bilateral adrenal masses.

Key words: Primary adrenal mass, Non-Hodgkin lymphoma, small intestine, intussusception

Yazışma Adresi: Nafiz SARIŞIK Kahramanmaraş Sutcu Imam University Faculty of Medicine, Department of Pediatrics,

Avşar Kampüsü, Kahramanmaraş, 46100, Turkey **Tel:** 03443003765, **Mail:** dr_nafiz@hotmail.com

ORCID No(Sırasıyla): 0000-0003-3317-7745, 0000-0002-6379-224X, 0000-0003-4740-3512, 0000-0002-6963-3389, 0000-0002-2567-4330, 0000-0002-2226-0116

INTRODUCTION

Gastrointestinal tract is the most common extranodal site involved by lymphoma with the majority being non-Hodgkin type. Gastrointestinal lymphomas are generally not clinically specific and cannot be easily distinguished from other benign and malignant conditions. Most of the cases with lymphoma involvement in the adrenal gland are non-hodgkin lymphomas and are usually seen up to 25% in the late stage of disease (1,2). However, primary adrenal lymphoma is defined as lymphomas that develop within the adrenal gland and do not form lymphadenopathy or leukemic formation and comprise 3% of extranodal lymphomas (2,3). It is more common in men than women (4). We present here a rare condition in literature which is a case of bilateral surrenal masses and burkitt lymphoma with small intestine origin.

CASE PRESENTATION

An 11-year-old boy, not known to have had diseases before presented to our hospital with progressively increasing pain in the abdomen and fullness in the right lower quadrant of his abdomen, generalized weakness, easy fatigability, and decreased appetite for 1.5 months' duration. He also complained of nausea and had a weight loss of 7 kg over this period. On examination, he was found to have a blood pressure of 100/65 mmHg with no postural drop, a pulse rate of 90 beats/minute and no fever. On admission, physical examination revealed that no enlarged superficial lymph nodes were palpable and there was no hepatosplenomegaly. Abdomen was with no palpable masses. There were no neurological deficits and stigmata of liver disease. Laboratory findings were not significant in terms of complete blood count and renal function tests. Abdominal ultrasound examination and contrast enhanced magnetic resonance imaging was performed which revealed masses on both left and right adrenal glands measuring 4.7X2.8X2.7 cm and 3.7X3.0X2.7 cm respectively (Figure 1).

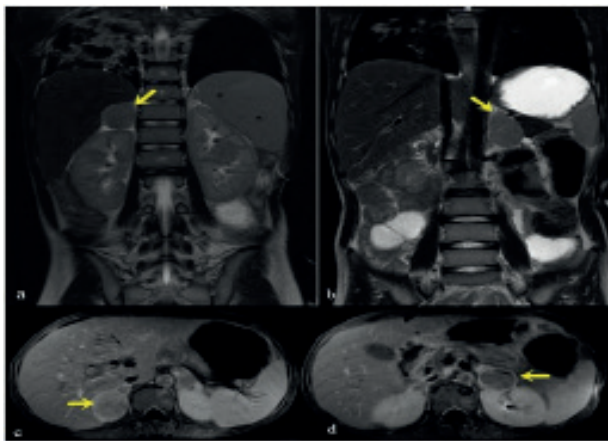


Figure 1. Coronal T2-weighted magnetic resonance images are displaying right (a) and left (b) adrenal masses with intermediate signal intensity (arrows). Axial fat suppressed, T1-weighted slices after intravenous gadolinium administration are depicting well-demarcated masses with moderate contrast enhancement those encompassed both right (c) and left (d) adrenal glands (arrows).

Gas-filled and enlarged small intestine loops full-filling the abdomen was compatible with obstruction due to intussusception at distal ileum level was also noted (not shown). 4-5 lesions and intussusception were seen in the small intestine. One lesions and segmental small intestine rezection was performed. The lesions were removed and sent to the pathology laboratory (Figure 2).

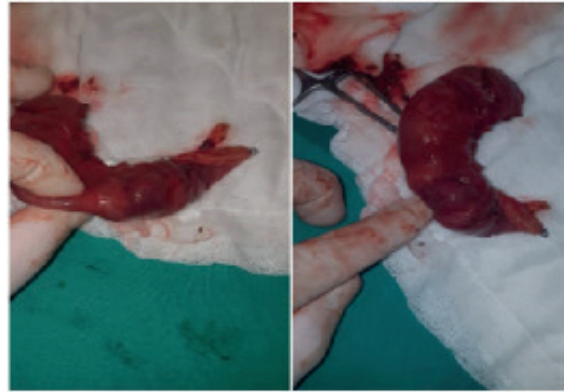

Figure 2. Lesion send to pathology

Microscopic examination of the masses revealed a diffuse lymphoid infiltrate composed of medium-sized lymphoid cells and a so-called starry-sky pattern which is due to the presence of tingible body macrophages. The tumor also has numerous mitotic figure and apoptotic cells (Figure 3). The tumor cells were positive for CD20, CD79a, CD10, BCL-6, cMYC and negative for CD3, CD5, BCL-2, and TdT, immunohistochemically (Figures 3a, 3b, 3c). The ki-67 proliferating index was over 95% percent (Figure 3d). The morphologic and immunohistochemical features are diagnostic for a high-grade B-cell lymphoma and Burkitt's lymphoma diagnosis was made.

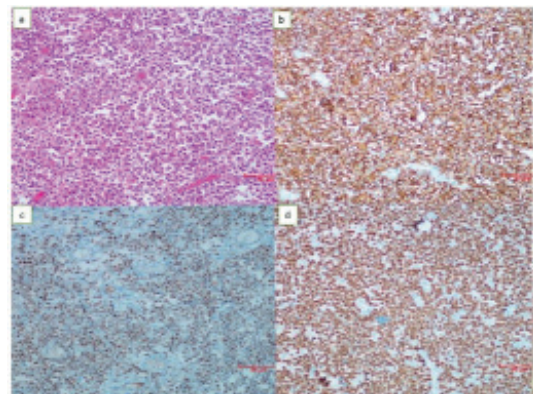


Figure 3. Histology images. In fig.a; diffuse infiltration of medium-sized monoton tumor cells showed. Also a lot of mitotic and apoptotic cells and tingible-body macrophages showed (Hematoxylin and eosin stain, original magnification $\times 200$). CD20 immunohistochemical stain is strongly positive for tumor cells (Fig.b, immunohistochemical stain, original magnification $\times 200$). MYC was positive in 50% of tumour cells (Fig.c, immunohistochemical stain, original magnification $\times 200$). Ki-67 proliferation index was above 95% (Fig.d, immunohistochemical stain, original magnification $\times 200$).

For further management, the patient was referred to our hematology clinic and was planned for chemotherapy regimen (NHL BFM 95). After the two sessions of chemotherapy adrenal mass has been completely vanished (**Figure 4**).

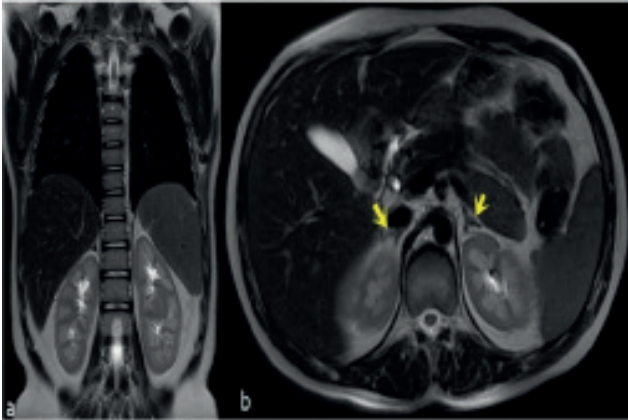


Figure 4. Follow-up coronal (a) and axial (b) magnetic resonance T2 weighted images are showing normal adrenal glands (arrows) consistent with a complete response to treatment.

He received a total of six cycles of chemotherapy regimen and was routinely followed pre- and postchemotherapy at the hematology clinic with complete blood count and serum LDH evaluations. The patient whose chemotherapy has been completed is remitted for 2 months.

DISCUSSION

Burkitt lymphoma with the origin of the gastrointestinal system is most commonly seen in children between the ages of 5-15 (5). Intussusception which makes an acute abdomen, caused by Burkitt lymphoma is a very rare condition that makes the diagnosis difficult (6). Burkitt's lymphoma is frequently associated with abdominal pain, nausea, and intestinal obstruction as a result of direct compression or intussusception of the bowel lumen (7). In our case, obstruction findings and invagination were found to make the diagnosis difficult. Small intestine and adrenal gland are rare sites for the involvement of Burkitt lymphoma. The most common symptoms are abdominal pain, loss of appetite, nausea and weight loss with palpable mass on physical examination (8). Primary adrenal lymphoma is a very rare subtype of extranodal lymphoma. Only 100 case had been reported in the literature (9). Primary adrenal lymphomas are typically seen in elders and males, and 70% of the case are bilateral (10,11). According to previous studies, male/female ratio is 7:1 and mean age at the time of diagnosis is 70 years (12,13). In our case, our patient presented with bilateral adrenal masses and intussusception. Multiple lesions were seen in the colon during the operation. The pathology result of the lesion was found to be Burkitt's lymphoma. If the patient did not present with acute abdomen, the diagnostic biopsy would have to be done from the mass in the adrenal gland. The patient was diagnosed as Burkitt's lymphoma and his bilateral adrenal

masses were completely regressed after two cycles of chemotherapy and our patient was diagnosed as Burkitt lymphoma with bilateral adrenal glands involvement. In the study performed by Rashidi et al. (14), it was found that most of the primary adrenal lymphoma had bilateral involvement, 78% was diffuse large B-cell lymphoma and about 60% had adrenal insufficiency, but our case did not support this study. Adrenal insufficiency was not seen in our case and the bilateral adrenal masses regressed after chemotherapy. Surgery was needed to confirm the diagnosis of Burkitt lymphoma and to treat symptoms such as existing intestinal obstruction, abdominal mass, invagination and acute abdomen. In our case, surgical operation was performed to treat the acute abdomen and to send a biopsy from the diagnostic mass. Survival was determined by chemotherapy.

As a conclusion, Burkitt lymphoma with bilateral adrenal masses and gastrointestinal involvement is rare in children in the literature. The staging and treatment protocol could not be clarified due to its rarity. There is a need for research involving detailed series on this subject, In addition, in children, vomiting and abdominal pain which does not relieve with symptomatic approaches should be evaluated for etiologic imaging and although it is rare, Burkitt lymphoma should be considered in differential diagnosis.

Declaration of Interest: Authors declare no conflict of interest.

REFERENCES

- Schreiber CS, Sakon JR, Simião FP, Tomarchio MP, Huayllas M, Pereira LCMM, et al. Primary adrenal lymphoma: a case series study. *Ann Hematol.* 2008;87(10):859-61.
- Ozimek A, Diebold J, Linke R, Heyn J, Hallfeldt K, Mussack T. Bilateral primary adrenal non-Hodgkin's lymphoma and primary adrenocortical carcinoma--review of the literature preoperative differentiation of adrenal tumors. *Endocr J.* 2008; 55(4):625-38.
- Zhang L, Talwalkar SS, Shaheen SP 2nd. A case of primary unilateral adrenal Burkitt-like large cell lymphoma presenting as adrenal insufficiency. *Ann Diagn Pathol.* 2007; 11(2):127-31.
- Hsu CW, Ho CL, Sheu WH, Harn HJ, Chao TY. Adrenal insufficiency caused by primary aggressive non-Hodgkin's lymphoma of bilateral adrenal glands: report of a case and literature review. *Ann Hematol.* 1999;78(3):151-4.
- Bethel CA, Bhattacharyya N, Hutchinson C, Ruymann F, Cooney DR. Alimentary tract malignancies in children. *J Pediatr Surg.* 1997;32(7):1004-8; discussion 1008-9.
- Cossaro M, Noce L, Bonutti A, Pecile P, Di Loreto C, Saro F, et al. An abdominal Burkitt's lymphoma in acute phase. Case report. *Minerva Pediatr.* 2006;58(3):311-8.
- Sandlund JT, Downing JR, Crist WM. Non-Hodgkin's lymphoma in childhood. *N Engl J Med.* 1996 May 9;334(19):1238-48.
- Al-Sayes FM. Gastrointestinal Non-Hodgkin's lymphoma: a clinico-pathological study. *Saudi J Gastroenterol.* 2006;12(3):118-22.
- De Miguel Sánchez C, Ruiz L, González JL, Hernández JL. Acute adrenal insufficiency secondary to bilateral adrenal B-cell lymphoma: a case report and review of the literature. *Ecancermedscience.* 2016;10:634.

10. Erçolak V, Kara O, Günaldı M, Afşar ÇU, Duman BB, Açıklın A, et al. Bilateral primary adrenal non-hodgkin lymphoma. Turk J Haematol.2014;31(2):205-6.
11. Wang J, Sun NC, Renslo R, Chuang CC, Tabbarah HJ, Barajas L, et al. Clinically silent primary adrenal lymphoma: a case report and review of the literature. Am J Hematol. 1998;58(2):130-6.
12. Lee KS, Chung YS, Park KH, Kim HS, Kim HM. A case of primary bilateral adrenal lymphoma with partial adrenal insufficiency. Yonsei Med J. 1999 ;40(3):297-300.
13. Wang JP, Sun HR, Li YJ, Bai RJ, Gao S. Imaging features of primary adrenal lymphoma. Chin Med J (Engl). 2009;122(20):2516-20.
14. Rashidi A, Fisher SI. Primary adrenal lymphoma: a systematic review. Ann Hematol. 2013;92(12):1583-93.