

# Adverse Drug Reactions During COVID-19 Treatment

## COVID-19 Tedavisinde İstenmeyen İlaç Reaksiyonları

Pınar METBULUT<sup>1</sup>, Emine DİBEK MISIRLIOĞLU<sup>1,2</sup>

<sup>1</sup>Ankara City Children's Hospital, Department of Pediatric Allergy and Immunology, Ankara, Turkey

<sup>2</sup>University of Health Science, Ankara City Children's Hospital, Department of Pediatric Allergy and Immunology, Ankara, Turkey



### ABSTRACT

Adverse drug reactions are unintended and harmful reactions to drugs. Coronavirus disease 2019 (Covid-19) has been widely spread. Although many drugs are used in the treatment of COVID-19, there is still no specific treatment with proven reliability and effectiveness and there are many studies to find effective treatment. Attention should be taken regarding the properties, interactions and undesired drug reactions of drugs used in the treatment of COVID-19. The aim of this review is to draw attention to adverse drug reactions of the drugs that are being used in COVID-19 treatment.

**Key Words:** Adverse effect, Covid-19, Drug hypersensitivity, Treatment

### ÖZ

İstenmeyen ilaç reaksiyonları ilaç kullanımında ortaya çıkan istenmeyen, zararlı etkilerdir. Coronavirus hastalığı 2019 (Covid-19) tüm dünyaya yayılmıştır. COVID-19 tedavisinde birçok ilaç kullanılmasına karşın, güvenilirliği ve etkinliği kanıtlanmış spesifik bir tedavi henüz yoktur ve etkili tedaviyi bulmak için çalışmalar devam etmektedir. COVID-19 tedavisinde kullanılan ilaçların özelliklerine, etkileşimlerine ve istenmeyen ilaç reaksiyonlarına dikkat edilmelidir. Bu derlemenin amacı COVID-19 tedavisinde kullanılan ilaçların istenmeyen ilaç reaksiyonlarına dikkat çekmektir.

**Anahtar Kelimeler:** Yan etki, Covid-19, İlaç hipersensitivite, Tedavi

### INTRODUCTION

A cluster of acute respiratory illness, known as novel coronavirus (2019-nCoV) occurred in Wuhan and spread all over the world. The COVID-19 pandemic is widespread in our country as well as all over the world. Although many drugs are used in the treatment of COVID-19, there is still no specific treatment with proven reliability and effectiveness and there are many studies to find effective treatment. Attention should be taken regarding the properties, interactions and undesired drug reactions of drugs used in the treatment of COVID-19. Side effects and drug hypersensitivity reactions that occur during the use of drugs are undesirable drug reactions.

### Classification of Adverse Reactions to Drug

Adverse drug reaction (ADR) is a harmful, unintentional and undesired response to a drug which occurs while using in humans for diagnosis, prophylaxis and treatment. ADRs occur in 3-6% of patient admissions and occur in about 10-20% of all hospitalized patients (1). It varies according to age, drug classes and drug prescription habits.

Adverse drug reaction is classified in two types: A-type (predictable) and B-type (unpredictable) reactions. Type A reactions are the result of the pharmacological action of the drug and therefore they are dose-dependent and predictable. They are the most common reactions (70-80%). Type B reactions are unpredictable, usually non-dose-dependent and

METBULUT P : 0000-0001-8823-5960  
DİBEK MISIRLIOĞLU E : 0000-0002-3241-2005

**Conflict of Interest / Çıkar Çatışması:** On behalf of all authors, the corresponding author states that there is no conflict of interest.

**Contribution of the Authors / Yazarın Katkısı:** METBULUT P: Constructing the hypothesis or idea of research and/or article, Reviewing the article before submission scientifically besides spelling and grammar, Taking responsibility in the writing of the whole or important parts of the study. DİBEK MISIRLIOĞLU E: Constructing the hypothesis or idea of research and/or article, Reviewing the article before submission scientifically besides spelling and grammar, Taking responsibility in the writing of the whole or important parts of the study.

**How to cite / Atıf Yazım Şekli :** Metbulut P, Dibek Misirlioglu E. Adverse Drug Reactions During COVID-19 Treatment. Turkish J Pediatr Dis 2020;14(suppl):65-71.

Correspondence Address / Yazışma Adresi:

**Emine DİBEK MISIRLIOĞLU**  
University of Health Science, Ankara City Children's Hospital,  
Department of Pediatric Allergy and Immunology, Ankara, Turkey  
E-posta: edibekm@yahoo.com

Received / Geliş tarihi : 25.06.2020

Accepted / Kabul tarihi : 22.07.2020

Online published : 27.07.2020

Elektronik yayın tarihi

DOI: 10.12956/tchd.757723

seen in sensitive patients. They are representing 15-20% of all ADRs but they are often severe and carry risk for mortality and morbidity (1). The classification of ADR is shown in Figure 1 (2).

Drug hypersensitivity reactions (DHRs) are defined as the emergence of objective symptoms or signs initiated by exposure to a defined drug at a dose tolerated by other people. They are seen in more than 7% of general population (1). DHR can be allergic or non-allergic. Allergic reactions are commonly IgE mediated (type I) and T-cell mediated (type IV). Rarely, they are mediated by cytotoxic (type II) and immune complex (type III). Gell and Coombs classification adapted to drug reactions are shown in Table 1 (3). In non-allergic reactions, immunologic mechanism has not been proved. The mechanism include nonspecific histamin release, bradykinin accumulation, complement activation, arachidonate metabolism alteration and pharmacological interaction (PI mechanism) (1)

### Clinical Phenotype of Drug Hypersensitivity Reactions

Clinical characteristics and timing are used for phenotyping of drug hypersensitivity (3). Drug Hypersensitivity Reactions can be divided into two groups based on the interval between drug intake and the onset of the symptoms. Immediate reactions were defined as those occurring within 1-6 hour after drug intake and non-immediate as occurring any time from 1 hour, commonly after many days of treatment. Immediate reactions can be IgE mediated or non-immunologic mechanism and commonly shows itself with urticaria, angioedema or anaphylaxis. Non-immediate reactions are commonly mediated by type IV allergic reaction or by the PI mechanism and usually show itself with maculopapular exanthems and delayed urticaria. In non-immediate reactions, internal organs can also be affected (1).

The most common manifestation of drug allergy is cutaneous reactions. Many phenotypes can be seen such

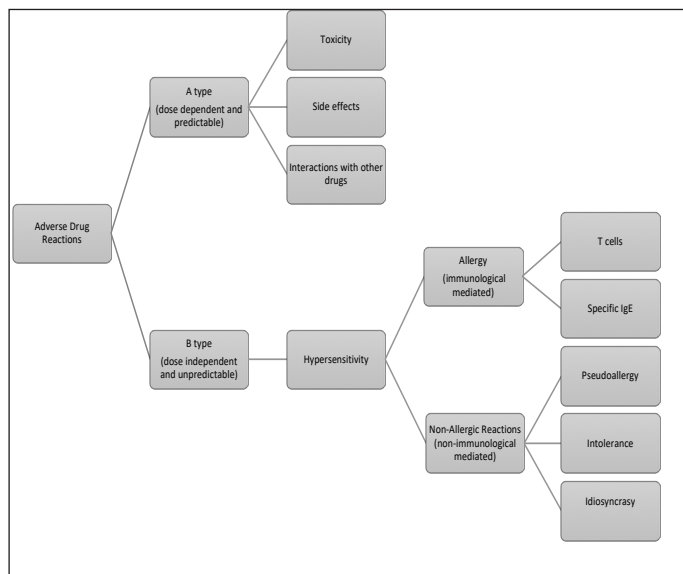


Figure 1: The Classification of Adverse Drug Reaction (2).

as maculopapular exanthems, urticaria, angioedema (4). The typical signs of immediate-type reactions are erythema, urticaria and angioedema. Anaphylaxis is an immediate reaction that involves more than one system; skin (pruritus, urticarial, angioedema, erythema), gastrointestinal system (nausea, vomiting, abdominal pain and/or diarrhea), respiratory system (rhinoconjunctivitis, dyspnea, wheezing and/or coughing) and cardiovascular system (drop of blood pressure, tachycardia, fainting and unconsciousness) (1). The most common manifestation of non-immediate DHR is maculopapular exanthem. Also delayed urticaria and angioedema may be seen. Fixed drug eruption is a non-immediate DHR that is characterised by purplish well demarcated macules. Vasculitis is a non-immediate reaction that is characterised with palpable purpuric macules found mostly in legs. Also fever, arthralgias, lymphadenopathy, headaches, abdominal pain, hematuria or peripheral neuropathy can be seen (1).

In non-immediate reaction, additional to skin rashes, there may be involvement of internal organs (including hepatic, pulmonary, renal and hematologic systems) and the extent of blood eosinophilia. Acute generalized exanthematous pustulosis, drug reaction with eosinophilia and systemic symptoms, fixed drug eruption, photosensitivity are rare (5). The most severe drug reactions are identified as severe cutaneous adverse reactions (SCAR) that contain; Drug Reaction with Eosinophilia and Systemic Symptoms (DRESS or DIHS for Drug Induced Hypersensitivity Syndrome), acute generalized exanthematous pustulosis (AGEP), and Stevens Johnson Syndrome (SJS)/toxic epidermal necrolysis (TEN). SCAR mostly have multiorgan involvement (4).

### Diagnosis and Management of Drug Hypersensitivity Reactions

The diagnostic management should begin with a detailed clinical history that includes description of symptoms, the time interval between symptoms and drug intake, the dose and administration way of drug. The administration of culprit drug must be stopped immediately and must perform detailed physical examination must be performed and check for danger signs such as bullous lesions of mucosal locations and involvement of internal organs. The list of danger signs are shown in Table II (3). Complete blood cell, liver and renal function tests, serum tryptase level must be performed according to the type of reaction.

### Treatment of Drug Hypersensitivity Reactions

The main therapy of DHR is to discontinue the drug. Also monitoring for fever, blood eosinophilia, proteinuria, arthralgia, lymphadenopathy, and hepatitis should be done. Anaphylactic reactions must be treated with adrenaline. Exfoliative syndromes, including SJS and toxic epidermal necrolysis (TEN), and any drug rash involving mucosal surfaces, commonly need hospitalization (6).

**Table I:** Gell and Coombs classification adapted to drug reactions (5).

Type	Type of Immune Response	Pathophysiology	Clinical Symptoms	Chronology of the reaction
I	IgE	Mast cell and basophil degranulation	Anaphylaxis, Urticaria, Angioedema, Bronchospasm	1-6 Hour
II	IgG, Complement	Cytotoxic	Cytopenia	5-15 day
III	IgG, IgM and Complement /FcR	Immun Complex Deposition	Serum Disease, Vasculitis	7-8 day 7-21 day
IVa	Th1 (IFN- $\gamma$ )	Monocytic Inflammation	Eczema	1-21 day
IVb	Th2 (IL-4, IL-5)	Eosinophilic Inflammation	Maculopapular exanthema, DRESS	1 to several days 2-6 week
IVc	Cytotoxic T cel (Perforin, Granzyme)	Keratinocyte Death	Maculopapular, Pustular exanthema fixed drug eruption SJS/TEN	1-2 day 1-2 day 4-28 day
IVd	T cell (IL-8/CCL8)	Neutrophilic Inflammation	AGEP	1-2 day/could be longer

Avoiding the culprit drug and cross reactive drugs are recommended (7). In selected cases, desensitization can be done (7).

### Drugs used in Covid-19 Treatment

Diagnosis and treatment approaches in our country are carried out according to the COVID-19 (SARS-CoV2 Infection) guide created by the Scientific Committee of the Ministry of Health. In this guide, treatment recommendations are based on the evaluation of available evidence, clinical study protocols, and expert opinions in cases of no evidence. In line with the treatment schemes in the COVID-19 guide, hydroxychloroquine, azithromycin, oseltamivir, lopinavir/ritonavir and favipiravir are used in treatment. In addition, the use of tosilizumab (anti-IL6R monoclonal antibody), anakinra (recombinant IL-1R antagonist) are recommended among the patients with macrophage activation syndrome during the course of COVID-19 infection. For coagulation disorders that may develop with MAS and sepsis, heparin treatment is being recommended (8).

### Hydroxychloroquine

Hydroxychloroquine is an antimalarial drug and approved by the U.S. Food and Drug Administration (FDA) for COVID-19 (9). Beside being antimalarial drug, it has been used in the treatment of rheumatic diseases and connective tissue diseases due to its immunomodulatory effect. In COVID-19, treatment mechanisms may include inhibition of viral enzymes, viral DNA and RNA polymerase, viral protein glycosylation, new virus particle transport, and virus release. Other mechanisms may also include ACE2 cellular receptor inhibition, acidification at the surface of the cell membrane inhibiting fusion of the virus, and immunomodulation of cytokine release. It is taken in oral administration (10).

Common side effects are risk of cardiac arrhythmias (QT prolongation) and risk of retinal damage (particularly in long term use) (10). Chloroquine and hydroxychloroquine are highly toxic in overdose that are manifested with cardiovascular collapse and central nervous system toxicity (11). In patients having

hepatic and renal failure, the serum level of hydroxychloroquine may increase, so it must be taken in consideration (12). It should not be used in patients with hereditary galactose intolerance, glucose-galactose malabsorption (12).

### Cardiovascular effects

Hydroxychloroquine treatment can cause significant QT prolongation and increasing risk of Torsade de Pointes (TdP) even at therapeutic doses. Other electrocardiographic changes may develop like T-wave inversion and depression (13). The arrhythmia risk is higher especially in elderly patients with cardiac comorbidity, using other drugs that prolong QT, and with electrolyte disorders. For this reason, it is necessary to make a risk assessment for QT prolongation in patients who are receiving hydroxychloroquine due to COVID-19 and, if it is necessary, decide with a cardiology consultation (8).

The American Heart Association has listed hydroxychloroquine as agent that can cause direct myocardial toxicity and exacerbate underlying myocardial dysfunction (14). Hydroxychloroquine treatment is contraindicated in patients having congenital long QT syndrome and in those who have a prior history of TdP (13).

With using azithromycin treatment, the risk of QT prolongation is increasing. These patients who take the both treatment, must be checked every day with electrocardiogram (ECG). When cardiotoxic effect is seen in ECG, firstly azithromycin treatment must be stopped and later the dosage of hydroxychloroquine must be decreased, if the toxic effect is continuing, hydroxychloroquine must be stopped (12). In a recently published study about Covid 19 patients who had hydroxychloroquine and azithromycin combination treatment, patients had a 15%-20% increased risk of chest pain or heart failure and a twofold increased risk of cardiovascular mortality in the first month of treatment (15). In another study, 191 patients received hydroxychloroquine and 119 also azithromycin treatment for Covid 19. The maximum QTc during treatment was significantly longer in the combination group than the monotherapy group. Seven patients (3.5%) discontinued these medications due to

**Table II:** Danger Signs in Drug Hypersensitivity (5).

Immediate reactions	Non-immediate Reactions
Sudden onset of generalized pruritus	Centropacial edema
Pruritus in palm-soles of feet, genital area, ears and head	Skin blisters, bullae
Dysphonia	Painful skin
Dysphagia	Mucosal involvement
Inspiratory dyspnea	Pustuler exanthem
Cough	Atypical target lesions
Conjonktival hiperemia	Fever >38.5
Reduced blood pressure	Generalized erythema
	Leucopenia, thrombopenia
	Renal dysfunction (urea, creatinin <sup>-</sup> )
	Lymphadenopathia (>2 sites)
	Blood count (eosinophilia, atypical lymphocytes)
	Liver function test (liver transaminase <sup>-</sup> )
	Proteinuria
	Hypocomplementemia

QTc prolongation (16). In two studies, it was shown that both using hydroxychloroquine alone or combination therapy with azithromycin caused QT prolongation (17,18).

In a recently published case report, after the third day of hydroxychloroquine treatment, a 60 year old woman without having cardiac disease, developed a right bundle branch block and prolonged electrocardiographic QT interval (QTc: 631 ms) which then resolved with discontinuation of therapy (19).

In conclusion, based on available data, hydroxychloroquine can cause arrhythmias, atrioventricular block, bundle branch block, QT prolongation and TdP. It must be used in attention with ECG monitoring.

### Ocular effects

The retinal damage risk is increased in patients who take more than 6.5mg/kg/dose per daily, having over 200mg cumulative dosage, older 65 years age, having renal failure and visual acuity below 6/8 (12). Major risk factors for retinopathy are having hydroxychloroquine cumulative dose >1000g, duration of use >5 years, renal impairment, tamoxifen use and having macular disease (20).

In a study focused on ocular adverse effects with hydroxychloroquine various doses, there was no adverse ocular event at 6 week with Hydroxychloroquine treatment at 400mg/day, 800mg/day, and 1,200mg/day dosage (21).

In Covid-19 treatment, hydroxychloroquine is being used for a short time. Therefore no ocular adverse effect is expected if there is no risk factor of host.

### Hypoglycemia

The basis of hypoglycemia effect is including reduced insulin clearance, increased insulin sensitivity and pancreatic insulin

release (11). Using antidiabetics with hydroxychloroquine can cause rarely life threatening loss of consciousness and hypoglycemia (12). If hypoglycemia develops, drug must be stopped and supplemental glucose or parenteral dextrose must be administered as needed (11).

### Skeletal system side effects

In long term use of this drug, it may cause weakness and periodic examination of skeletal muscle and tendon reflexes must be done (12).

### Hematologic

In G6PD patients, it is known that antimalarial drugs are causative of oxidative hemolysis but in some studies it is shown that chloroquine and hydroxychloroquine are less likely to do (11). In a study, 11 rheumatology patients with established G6PD deficiency, hydroxychloroquine-related hemolysis was not experienced over more than 700 months of treatment (22). In G6PD patients, caution must be taken in consideration (10).

### Neuropsychiatric side effects

Hydroxychloroquine can cause a wide spectrum of neuropsychiatric manifestations, including agitation, insomnia, confusion, mania, hallucinations, paranoia, depression, catatonia, psychosis and suicidal ideation. These can occur at all ages, in acute or chronic usage and in patients with and without a history of mental illness. Clinicians should take attention for new or worsening neuropsychiatric symptoms while using in patients who already have mental illness (11).

### Cutaneous side effects

With using hydroxychloroquine, cutaneous reactions may occur. The cutaneous reactions may be rash, pruritus, pigmentation disorders in skin and mucous membranes, hair color changes,

alopecia. It is not recommended in psoriasis and porphyria because they may be exacerbated by using hydroxychloroquine treatment (23).

In newly published case report, in a Covid 19 patient having psoriasis, at the fourth day of hydroxychloroquine treatment, the patient had an exacerbation of silver-scaled psoriatic plaques spread quickly all over the body (24).

### Drug Hypersensitivity Reactions

Hydroxychloroquine generally have safe profiles but cutaneous side effects can occur. It's cutaneous side effects ranges from mild skin reactions to severe cutaneous drug eruptions (25) Chloroquine and hydroxychloroquine have been implicated in severe cutaneous adverse reactions, including SJS, TEN, and DRESS. They should be considered in patients with new-onset fever, exanthem or mucositis in the weeks after the begin of treatment, especially when accompanied by new hematologic abnormalities (such as lymphopenia, eosinophilia or atypical lymphocytosis) and liver or kidney failure even it is a rare condition (11).

Newly, a severe cutaneous drug reaction resembling AGEP triggered by hydroxychloroquine treatment in Covid-19 patient has been documented (26).

### Drug-Drug interactions

Genetic variability in metabolism of these drugs can influence their safety and effectiveness. Both chloroquine and hydroxychloroquine are metabolized by hepatic cytochrome P450 enzyme 2D6 (CYP2D6), the expression of which differs among patients as the result of genetic polymorphisms. This genetic variability influences the response to treatment as well as the risk of adverse events. There are interactions with many drugs such as azithromycin, cimetidine, insulin, antidiabetic drugs-insulin, cyclosporin, moxifloxacin, rifampicin, antiepileptic drugs, antiarrhythmic drugs, rifampicin and niacin etc (27).

### Azithromycin

Azithromycin is an antibacterial. Macrolides may have immunomodulatory effect in pulmonary inflammatory disorders and they can decrease the excessive cytokine production related with respiratory viral infections (10).

The main side effect is cardiac toxicity (QT prolongation). In patients with long QT, hepatic and renal failure, azithromycin should not be used (10). The side effects can be classified as gastrointestinal (vomiting, feeding intolerance, abdominal tenderness, diarrhoea), respiratory (respiratory distress, bronchopulmonary dysplasia), central nervous system (intraventricular hemorrhage, abnormal hearing, PVL), hepatobiliary (elevated transaminase), cardiovascular (patent ductus arteriosus), metabolic (hyperkalemia) (28).

Drug hypersensitivity reactions with macrolides occur in 0.4-3%. Commonly, skin manifestations are being reported. Mostly seen immediate reactions are urticaria, angioedema and

rarely anaphylaxis. Non-immediate reactions are commonly maculopapular rash, exfoliative dermatitis, urticaria, erythema, abdominal pain and respiratory symptoms. Although skin tests are not validated enough for macrolides, the combination of skin tests and provocation test to the culprit drug may lead to confirmation of macrolide allergy (29).

## ANTIVIRAL THERAPY

### Lopinavir/ritonavir

Lopinavir/ritonavir is HIV protease inhibitor. In the past, it was used in MERS-CoV and SARS-CoV treatment. It may bind a key enzyme for coronavirus replication and suppress the activity (10). The safety, efficacy and pharmacokinetic profiles of lopinavir and ritonavir should not be used in newborns younger than 14 days (8). It is contraindicated in liver failure and in heart diseases (ischemic heart disease, cardiomyopathy, long QT). Drug drug interactions are frequent because the P 450 isoform is a CYP3A inhibitor (10). The adverse events in adults who were using lopinavir/ritonavir for HIV disease, are commonly diarrhea (also other gastrointestinal disturbances), headache and skin rash. In children skin rash is the most common adverse event and severe reaction is rare. Also hypercholesterolemia and hypertriglyceridemia are seen commonly (30). It can lead to prolonged cardiac conduction defects and QT interval, 2nd and 3rd degree AV block (30). In a recently published study about the use of lopinavir/ritonavir in Covid 19 patients, there was no significant difference of adverse drug effects in liver toxicity and side effects between control and patient group (31).

### Favipiravir

Favipiravir is a purine nucleic acid analog that is used for influenza and Ebola in the past. In clinical trials, it showed a significant reduction of viral RNA load and increment in clinical improvement in coronavirus patients (32).

The adverse reactions are commonly diarrhea, an asymptomatic increase of blood uric acid and transaminases, and a decrease in the neutrophil counts. Some studies showed that favipiravir affects the hepatic drug metabolizing enzymes and causes acetaminophen level to increase. When combined with favipiravir, the recommended maximum daily doses of acetaminophen are 3g (32). In a recently published study of Covid 19 patients who were treated with favipiravir or lopinavir/ritonavir treatment, side effects were significantly lower in favipiravir treatment group. Diarrhea was the most common side effect in Covid 19 patients who were treated with favipiravir (33).

### Oseltamivir

Oseltamivir is a neuraminidase inhibitor that is commonly used in influenza. The most frequently reported adverse events are nausea, diarrhea, vomiting and headache (34). Rare adverse events include serious skin reactions, cardiac arrhythmias, and neuropsychiatric episodes. The neuropsychiatric side effects included delirium, suicidal events, panic attacks, delusions and

disturbances in consciousness (35). No studies showing the side effect of oseltamivir treatment in coronavirus have been reported yet.

### Biological Agents

During the COVID-19 infection, it was observed that the macrophage activation syndrome (MAS) could develop, with or without signs of sepsis and ARDS, and these patients were reported to benefit from anti-cytokine treatments. Based on a few patient studies, tosilizumab and anakinra has been reported to have a positive effect on COVID-19-associated MAS. The efficacy of tosilizumab, other IL-6 blocker and IL-1 blocker anakinra drug in serious course COVID-19 disease is being investigated by controlled clinical studies (8).

Hypersensitivity reactions to biologic agents have been classified as infusion-related reactions, cytokine-release reactions, type I (IgE/non-IgE), type III, and delayed type IV reactions (36). The infusion-related and cytokine-release reactions include fever, tachycardia, hypertension, dyspnea, nausea, vomiting, and syncope that commonly occurs at first application (36).

### Tosilizumab

Tosilizumab is an IL-6 receptor inhibitor monoclonal antibody. Indicated for the treatment of rheumatoid arthritis, giant cell arteritis, polyarticular (>2 years) and systemic (>2 years) juvenile idiopathic arthritis and cytokine release syndrome (10).

The risk of gastrointestinal perforation and hepatotoxicity is important in using tosilizumab. It should be used with caution in patients with thrombocytopenia and neutropenia (10).

There infusion related reactions may be seen (10). The infusion related reactions includes fever, tachycardia, hypertension, dyspnea, nausea, vomiting, and syncope and commonly happens at first administration. There have been published children cases who had anaphylaxis with tosilizumab treatment (36).

### Anakinra

Anakinra is an IL-1 receptor antibody. The most common adverse effect is a local reaction at injection site (37). A case who had anaphylaxis with anakinra, continued treatment with canakinumab desensitization was reported (38).

## CONCLUSION

Besides adverse drug effects and drug-drug interactions, hypersensitivity reactions may develop with drugs used during Covid-19 therapy. Physician should be careful in this regard during the follow-up of Covid-19 patients. In case of drug hypersensitivity reaction; discontinuing of the drug, treatment of the developing reaction and making an appropriate and safe treatment plan for the disease are important.

## REFERENCES

1. Dona I, Salas M, Perez-Sanchez NI, Aguilar C, Torres MJ. Phenotypes and Natural Evolution of Drug Hypersensitivity. *Curr Treat Options Allergy* 2019;6:27-41.
2. Dona I, Caubet JC, Brockow K, Doyle M, Moreno E, Terreehorst I, et al. An EAACI task force report: recognising the potential of the primary care physician in the diagnosis and management of drug hypersensitivity. *Clin Transl Allergy*. 2018 May 10;8:16. doi: 10.1186/s13601-018-0202-2.
3. Fernandez J, Dona I. Diagnosing and managing patients with drug hypersensitivity. *Expert Rev Clin Immunol* 2018;14:29-41
4. Muraro A, Lemanske R, Castells M, Torres MJ, Khan D, Simon HU, et al. Precision Medicine in Allergic Disease-Food Allergy, Drug Allergy, and Anaphylaxis- PRACTALL document of the European Academy of Allergy and Clinical Immunology and the American Academy of Allergy, Asthma and Immunology. *Allergy* 2017;72:1006-21
5. Demoly P, Adkinson NF, Brockow K, Castells M, Chiriac AM, Greenberger PA, et al. International Consensus on drug allergy. *Allergy* 2014;69:420-37.
6. Gomes ER, Brockow K, Kuyucu S, Saretta F, Mori F, Blanca-Lopez N, et al. Drug hypersensitivity in children: report from the pediatric task force of the EAACI Drug Allergy Interest Group. *Allergy* 2016:149-61.
7. Hausmann O. *Drug Allergy. Middleton's Allergy Principles and Practice*. 8th edition. Philadelphia. Elsevier 2014:1274-1295
8. [https://covid19bilgi.saglik.gov.tr/depo/rehberler/COVID-19\\_Rehberi.pdf](https://covid19bilgi.saglik.gov.tr/depo/rehberler/COVID-19_Rehberi.pdf)
9. Food and Drug Administration (FDA). Coronavirus disease 2019 (COVID-19). 2020. <https://www.fda.gov/emergency-preparedness-and-response/counterterrorism-and-emerging-threats/coronavirus-disease-2019-covid-19>.
10. Smith T, Bushek J, Prosser T, COVID-19 Drug Therapy. Elsevier 2020.
11. Juurlink D, Safety consideration with chloroquine, hydroxychloroquine and azithromycin in the management of SARS-CoV-2 infection. *CMAJ* 2020.
12. <https://khgmstokyonetimdb.saglik.gov.tr/TR,64702/hidroksiklorokin-sulfat-200-mg-film-tablet---covid-19-sars-cov2-enfeksiyonu-tedavisinde-kullanilacak-ilaclara-iliskin-bilgilendirme.html>
13. Naksuk N, Lazar S, Peeraphatdit TB. Cardiac safety of off-label COVID-19 drug therapy: a review and proposed monitoring protocol. *Eur Heart J Acute Cardiovasc Care*. 2020;9:215-21.
14. Page RL, O'Bryant CL, Cheng D, Dow TJ, Ky B, Stein CM, et al. Drugs that may cause or exacerbate heart failure. *Circulation* 2016; 134: e32-e69.
15. Lane JCE, Weaver J, Kostka K, et al. Safety of hydroxychloroquine, alone and in combination with azithromycin, in light of rapid wide-spread use for COVID-19: a multinational, network cohort and self-controlled case series study. *medRxiv* 2020. doi.org/10.1101/2020.04.08.20054551.
16. Saleh M, Gabriels J, Chang D, Kim BS, Mansoor A, Mahmood E, et al. The Effect of Chloroquine, Hydroxychloroquine and Azithromycin on the Corrected QT Interval in Patients with SARS-CoV-2 Infection. *Circ Arrhythm Electrophysiol*. 2020 Apr 29. Doi :10.1161/CIRCEP.120.008662. [Epub ahead of print]
17. Bessière F, Rocchia H, Delinière A, Charrière R, Chevalier P, Argaud L, et al. Assessment of QT Intervals in a case series of patients

- with coronavirus disease 2019 (COVID-19) infection treated with hydroxychloroquine alone or in combination with azithromycin in an intensive care unit. *JAMA Cardiol* 2020; e201787. doi: 10.1001/jamacardio.2020.1787.
18. Mercurio NJ, Yen CF, Shim DJ, Maher TR, McCoy CM, Zimetbaum PJ, et al. Risk of QT interval prolongation associated with use of hydroxychloroquine with or without concomitant azithromycin among hospitalized patients testing positive for coronavirus 2019 (COVID-19) infection. *JAMA Cardiol* 2020;e201834. doi:10. 1001/jamacardio.2020.1834.
  19. Asli R, Abdullah MS, Chong PL, Metussin D, Momin RN, Mani BI, et al. Case Report: Right Bundle Branch Block and QTc Prolongation in a Patient with Novel Coronavirus Disease (COVID-19) Treated with Hydroxychloroquine. *Am J Trop Med Hyg* 2020 May 7. doi: 10.4269/ajtmh.20-0376. [Epub ahead of print]
  20. Yusuf IH, Sharma S, Luqmani R, Downes SM. Hydroxychloroquine retinopathy. *Eye (Lond)* 2017;31:828-45.
  21. Furst DE, Lindsley H, Baethge B, Botstein GR, Caldwell J, Dietz F, et al. Dose-loading with hydroxychloroquine improves the rate of response in early, active rheumatoid arthritis: a randomized, double-blind six-week trial with eight-teen-week extension. *Arthritis Rheum* 1999;42:357-65.
  22. Mohammad S, Clowse MEB, Eudy AM, Schreiber LGC. Examination of hydroxychloroquine use and hemolytic anemia in G6PDH-deficient patients. *Arthritis Care Res (Hoboken)* 2018;70:481-5.
  23. <http://products.sanofi.ca/en/plaquenil.pdf>
  24. Randhawa A, Wylie G. A case of an acute cutaneous drug reaction with hydroxychloroquine. *Scott Med J* 2018;63:91-4.
  25. Schwartz RA, Janniger CK. Generalized pustular figurate erythema a newly delineated severe cutaneous drug reaction linked with hydroxychloroquine. *Dermatol Ther* 2020:e13380. doi: 10.1111/dth.13380.
  26. Kutlu Ö, Metin A. A case of exacerbation of psoriasis after oseltamivir and hydroxychloroquine in a patient with COVID-19: Will cases of psoriasis increase after COVID-19 pandemic?. *Dermatol Ther* 2020 Apr 7:e13383. doi: 10.1111/dth.13383.
  27. <https://dosyamerkez.saglik.gov.tr/Eklenti/36979,covid---19-tedavisinde-kullanilan-ilaclar---ilac-etkilesimleripdf.pdf?0>
  28. Smith C, Egunsola O, Choonara I, Kotecha S, Jacqz-Aigrain E, Sammons H. Use and safety of azithromycin in neonates: a systematic review. *BMJ* 2015;5:e008194. doi: 10.1136/bmjopen-2015-008194.
  29. Barni S, Butti D, Mori F, Pucci N, Rossi ME, Cianferoni A, et al. Azithromycin is more allergenic than clarithromycin in children with suspected hypersensitivity reaction to macrolides. *J Investig Allergol Clin Immunol* 2015;25:128-32.
  30. Cvetkovic RS, Goa KL. Lopinavir/ritonavir: a review of its use in the management of HIV infection. *Drugs* 2003;63:769-802.
  31. e XT, Luo YL, Xia SC, Sun QF, Ding JG, Zhou Y, et al. Clinical efficacy of lopinavir/ritonavir in the treatment of Coronavirus disease 2019. *Eur Rev Med Pharmacol Sci* 2020;24:3390-6.
  32. Du YX, Chen XP. Favipiravir: Pharmacokinetics and Concerns About Clinical Trials for 2019-nCoV Infection. *Clin Pharmacol Ther* 2020 Apr 4. doi: 10.1002/cpt.1844.
  33. Cai Q, Yang M, Liu D, Chen J, Shu D, Xia J, et al. Experimental Treatment with Favipiravir for COVID-19: An Open-Label Control Study. *Engineering (Beijing)* 2020 Mar 18. doi: 10.1016/j.eng.2020.03.007.
  34. Mitha E, Krivan G, Jacobs F, Nagler A, Alrabaa S, Mykietiuik A, et al. Safety, Resistance, and Efficacy Results from a Phase IIIb Study of Conventional- and Double-Dose Oseltamivir Regimens for Treatment of Influenza in Immunocompromised Patients. *Infect Dis Ther* 2019;8:613-26.
  35. Dalvi PS, Singh A, Trivedi HR, Mistry SD, Vyas BR. Adverse drug reaction profile of oseltamivir in children. *J Pharmacol Pharmacother* 2011;2:100-3.
  36. Soyer O, Demir S, Bilginer Y, Batu ED, Sonmez HE, Arıcı ZS, et al. Severe hypersensitivity reactions to biological drugs in children with rheumatic diseases. *Pediatr Allergy Immunol* 2019;30:833-40.
  37. Brucato A, Imazio M, Gattorno M, Lazaros G, Maestroni S, Carraro M, et al. Effect of Anakinra on Recurrent Pericarditis Among Patients With Colchicine Resistance and Corticosteroid Dependence: The AIRTRIP Randomized Clinical Trial. *JAMA* 2016;316:1906-12.
  38. Aguiar CL, Pan M, Adams A. Anaphylaxis to anakinra in a pediatric patient with systemic juvenile idiopathic arthritis successfully treated with canakinumab: a case-based review. *Clin Rheumatol* 2015;34:1821-4.