



## Transarterial embolization of acute gastrointestinal bleeding

Ayşegül İDİL SOYLU<sup>1,\*</sup>, Fatih UZUNKAYA<sup>1</sup>, Ümit BELET<sup>2</sup>, Hüseyin AKAN<sup>1</sup>

<sup>1</sup>Department of Radiology, Faculty of Medicine, Ondokuz Mayıs University, Samsun, Turkey

<sup>2</sup>Department of Radiology, Tepecik Training and Research Hospital, İzmir, Turkey

Received: 28.06.2020

Accepted/Published Online: 04.12.2020

Final Version: 18.03.2021

### Abstract

Transarterial embolization (TAE) is a minimally invasive treatment method developed alternative to surgery for acute gastrointestinal bleeding (AGIB). The aim of this study was to evaluate the efficacy and outcome of TAE in AGIB patients. The data of 30 patients who underwent TAE with complaint of AGIB between January 2007- May 2020 was collected retrospectively. The etiology of hemorrhage, localization and type of lesion, embolizing agent used, and postprocedural complications were recorded. Lesions were classified as pseudoaneurysm (PA), extravasation, pathological tumor vascularity and vasospasm. A total of 22 patients, 5 females, were included in the study. The most common underlying cause was tumors (n=15, 50%). The most common lesion detected on angiograms was pathological tumor vascularity. Embolizing agents used were N-butyl-2-cyanoacrylate in five patients, coils in three patients, polyvinyl alcohol particles in six patients and microsphere in seven patients. The technical success rate was 90.9%, and two patients developed rebleeding in the early postprocedural period. TAE is a safe, effective and minimally invasive method in emergency treatment of patients with AGIB.

**Keywords:** transarterial embolization, acute gastrointestinal bleeding, embolic agents

### 1. Introduction

Acute gastrointestinal bleeding (AGIB) is a life-threatening severe emergency condition (Manning-Dimmitt et al., 2005). Massive bleeding can lead to hemodynamic instability, hemorrhagic shock, and even death, so the lesion that causes bleeding needs to be detected and treated quickly (Peynircioğlu et al., 2011; Chan et al., 2015). Arterial angiography was used for the first time in 1963 by Nusbaum in the diagnosis of AGIB (Nusbaum et al., 1969). Rösch et al. developed transarterial embolization (TAE) in the treatment of AGIB in 1972 (Rösch et al., 1972). Rapid development in interventional radiological techniques and materials has enabled AGIB to be treated quickly and effectively with angiographic methods. In patients whom bleeding can't be stopped with conservative or endoscopic treatment, TAE is a minimally invasive treatment alternative to surgery (Walker et al., 2012; Loffroy, 2013).

In this study, we aimed to investigate retrospectively the arteriographic findings and the effectiveness of the treatment in cases that we performed TAE due to AGIB in our interventional radiology unit.

### 2. Materials and methods

Patients who underwent angiography with the diagnosis of AGIB between January 2007 and June 2020 in the

interventional department of our hospital were retrospectively screened. The institutional Ethical Committee of the Ondokuz Mayıs University has approved this retrospective study, and the procedures were in accordance with the ethical standards.

Etiology of gastrointestinal bleeding, localization of haemorrhage, embolic agents used and postoperative complications were recorded. Pathologic vascular findings on digital subtraction angiography (DSA) were grouped as extravasation, pseudoaneurysm (PA), pathological tumor vascularity and vasospasm. Cessation of bleeding on postembolization angiograms and hemodynamic stability were described as technical success. Patients were evaluated for recurrence of haemorrhage within the 30-day postprocedural period.

#### 2.1. Embolization procedure

Written informed consent was obtained from all patients before the procedure. Following the monitorization of patient, a 5F introducer sheath was placed into common femoral artery. Celiac trunk, superior mesenteric artery (SMA) and inferior mesenteric artery (IMA) were catheterized by 5F Simmons-2 (Terumo, Tokyo, Japan) or Cobra (Cook, Bloomington, IN) catheter selectively. A 3F microcatheter (Renegade, Boston

\* Correspondence: a.isoylu@gmail.com

Scientific, USA) or Echelon 10 microcatheter (ev3 Endovascular, Plymouth, MN, USA) were used for embolization according to the detected lesion and the nature of the embolizing agent to be used. All embolization procedures were done under fluoroscopy in order to prevent off-target embolization. N-butyl-2-cyanoacrylate (Histoacryl; B. Braun Melsungen AG, Melsungen, Germany), polyvinyl alcohol (PVA) particles (Contour; Boston Scientific, Cork, Ireland) (Contour SE®, Boston Scientific, Nattick, MA, US ve BeadBlock®, Biocompatibles, Farnham, United Kingdom), microsphere (Embosphere Microspheres®, BioSphere Medical, Rockland, MA) and detachable coils (GDC coils; Boston Scientific) were used as embolizing agents. Cyanoacrylate was used in combination with ionized oil (Lipiodol Ultra Fluide; Guerbet, Roissy, France) for both visibility and embolizing effect (the ratio of cyanoacrylate /iodized oil was 1:2, 1:3 or 1:8). Results for the quantitative variables were expressed as the mean and standard deviation (SD), and the results for the categorical variables were shown in terms of frequencies and percentages.

### 3. Results

Thirty patients with AGIB were included in the study. Five of them were female and the mean age was 56.5±16.3 (aged between 20-81). There was no hemorrhagic lesion detected by DSA in seven patients. Twenty-three lesions were detected and embolized.

When patients were evaluated according to the etiology of bleeding; it was due to gastroduodenal ulcer in seven patients, gastric carcinoma in eight patients, iatrogenic bleeding in three patients, pancreatic cancer in two patients, secondary to other tumors in five patients, diverticulitis in three patients, pancreatitis in one patient and amyloid-related bleeding in one patient. We identified 8 pseudoaneurysm, 10 tumor vascularity, five contrast extravasation and seven vasospasms (Table 1).

**Table 1.** GIS bleeding etiology and angiography findings

Cause (n)	Contrast extravazation	Pseudoaneurysm	Tumor vascularity	Vasospazm
Gastric or duodenal ulcer (4)	2	1		2
Gastric carsinom (5)		2	4	
Tumor bleeding (7)		3	6	3
Iatrogenic (3)	1	1		1
Diverticulite (1)	1			
Pankreatit (1)		1		1
Amyloid angiopathy (1)	1			

Eight gastroduodenal artery, five left gastric artery, six SMA branches, one splenic artery, one right gastric artery, one left gastroepiploic artery and one inferior pancreaticoduodenal artery were embolized. Embolization could not be performed in one patient because catheterization could not be achieved

secondary to tortiosity and vasospasm although angiography revealed a bleeding focus in the right gastric artery. In one patient, front-back door technique was used to cut the retrograde flow and both the inferior pancreaticoduodenal artery and the left gastric artery were embolized. Cyanoacrylate was used (the ratio of cyanoacrylate /iodized oil was 1:2, 1:3 or 1:8) in five patients, coil in three patients, PVA (in sizes of 500-700 microns) in six patients, and microsphere in eight patients as embolizing agents (Table 2). TAE technical success was 90.9% and recurrent bleeding occurred only in two patients. None of the patients experienced intestinal ischemia or duodenal stenosis during the postprocedural period

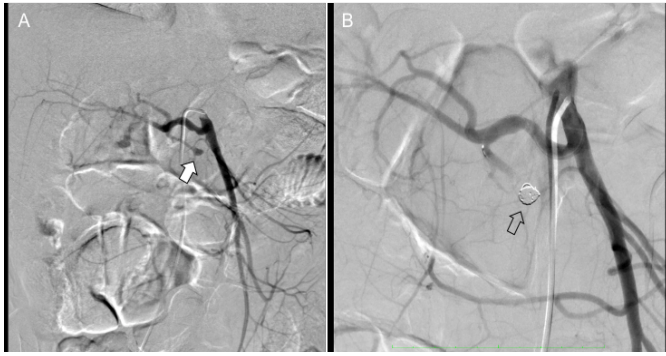
**Table 2.** Clinical, angiographic characteristics of patients undergoing trans arterial embolization for AGIB

Characteristics	Value
Patients, n	30
Age (years)	56.5±16.3 (20-81)
Male, n (%)	25 (83.3)
Digital subtraction angiography, n	
DSA positive patients, n (%)	23 (76.6%)
DSA negative patients, n (%)	7 (23.3%)
Localization (n=23)	
Gastroduodenal artery, n (%)	8 (34.8%)
Left gastric artery, n (%)	5 (21.7%)
Superior mesenteric artery branches, n (%)	6 (26%)
Splenic artery, n (%)	1 (4.3%)
Left gastroepiploic artery, n (%)	1 (4.3%)
Right gastric artery, n (%)	1 (4.3%)
Inferior pancreaticoduodenal artery, n (%)	1(4.3%)
Embolization agents (n=22)	
Microspheric embolizing agent, n (%)	8 (36.3%)
Cyanoacrylate, n (%)	5 (21.7%)
PVA, n (%)	6 (527.2%)
Coil, n (%)	3(13.6%)
Successful treatment frequency (n=22)	
Cessation of bleeding, n (%)	20 (90.9%)
Rebleeding, n (%)	2 (9.09%)

### 4. Discussion

Annual incidence of AGIB is 20 to 150 per 100,000 population and upper gastrointestinal bleeding is about four to six times more common than lower gastrointestinal bleeding (Manning-Dimmitt et al., 2005; Arber et al., 1994). Mortality rates in AGIB range between 3.6 and 19% and increase up to 40% in case of massive bleeding (Frattaroli et al., 2009).

AGIB often develops secondary to gastric-duodenal ulcer, diverticulitis, Mallory-Weiss syndrome, erosive gastritis, duodenitis, reflux esophagitis, pancreatitis, chronic inflammatory bowel disease, angiodysplasia, tumors of the gastrointestinal tract, iatrogenic and trauma (Manning-Dimmitt et al., 2005; Hreinsson et al., 2013; Barnert et al., 2009). Although the most common cause of AGIB is ulcers, it is noteworthy that tumoral etiology is more common in patients scheduled for endovascular treatment (Shi et al., 2017). Similarly, in our study, AGIB patients with tumoral causes were more common. Ulcers, on the other hand, took the second place in etiology (Fig 1).



**Fig. 1.** CTA of a 47-year-old man who presented with massive hematochezia due to duodenal ulcer. Selective hepatic artery angiography showed a PA arising from the gastroduodenal artery (A). After the lesion was super selectively catheterized, the PA embolized with coil (B)

This situation was related to the treatment of bleeding caused by ulcers frequently with endoscopic interventions. Hemorrhage of peripancreatic arteries caused by pancreatitis or pancreatic tumor is a rare cause of AGIB. In two of our cases, bleeding was secondary to erosion caused by the pancreatic mass in the gastroduodenal artery and in 1 case, it was due to erosion caused by pancreatitis in the splenic artery and posterior of the stomach. All three cases were successfully treated with the endovascular method. The sensitivity of arteriography is approximately 90% for upper gastrointestinal bleeding and 86% for lower gastrointestinal bleeding, respectively (Lee et al., 2004). DSA enables detection of bleeding in patients with blood loss rates of 0.5-1 mL/min (Nusbaum et al., 1969). Direct angiographic findings of active GI bleeding are contrast media extravasation and pseudoaneurysm (Walker et al., 2012). In our study, 18 of 22 patients underwent embolization based on direct angiography findings. Intermittent course of AGIB can lead to negative angiographic results (Sos et al., 1978; Eriksson et al., 2006).

In cases where direct findings can't be detected, vasospasm and irregularity in the suspected area are considered as indirect findings. In a study with embolization series of 75 patients by Aina et al. (2001) empirical embolization was performed based on angiography findings in 61.3% of patients and endoscopy findings in 38.7%. It was reported that blind embolization could be performed in case of clinical necessity because there was no difference in bleeding recurrence between both groups. Padia et al. (2009) reported that arterial embolization was equally effective in patients with or without contrast extravasation in their study comparing embolization results in 36 patients with extravasation in angiography due to bleeding in the upper gastrointestinal tract and 72 patients without extravasation. In four of our cases, empirical embolization was performed based on endoscopy findings and vasospasm although there was no lesion in direct angiography and there was no bleeding in the follow-up.

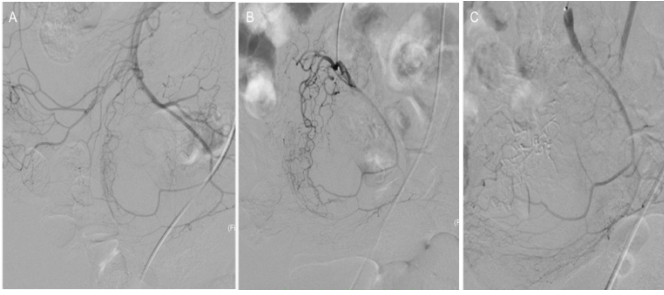
In a meta-analysis performed by Loffroy and Guiu, the technical success rate of TAE was reported as 93% and

rebleeding rate as 25% in upper GIB (Loffroy et al., 2009). The technical success rate of TAE in lower GIB was reported as 82% and rebleeding rate as 12% in the meta-analysis conducted by Weldon et al. (2008). In our study, the success rate of TAE due to AGIB was 90.9% and rebleeding rate was 9.09% and these rates were compatible with the literature. In the study of Loffler et al. (2009) investigating the causes of early rebleeding in AGIB patients who could not be treated endoscopically, coagulation disorders and the use of coils as the only embolic agent were reported to be the independent predictors of rebleeding. Aina et al. (2001) also determined that the presence of a coagulation disorder and the use of coils as the only embolic agent were associated with early rebleeding after an embolization procedure.

In our study, rebleeding that developed after gastroduodenal artery embolization in a patient with AGIB secondary to gastric ulcer may be related to the use of only coils in embolization and the absence of front-back door embolization. In another patient who experienced rebleeding, we think that both previous hemicolectomy surgery and the presence of acute myeloblastic leukemia as a comorbidity caused bleeding again.

Various embolizing agents have been used for embolization including gelatin spongostan, PVA, cyanoacrylate, onyx, coil and combinations of these (Loffroy et al., 2015; Širvinskis et al., 2017; Shi et al., 2017). The effect of embolic agent type on clinical results is controversial and there is no consensus on the selection of embolic agent in the literature. Particular agents such as PVA and microsphere are recommended for tumor embolization's using flow dynamics. Larger (> 500  $\mu$ m) particles should be preferred to reduce the risk of ischemia (Lang, 1992). In a study which the treatment results of acute nonvariceal upper gastrointestinal bleeding with cyanoacrylate were retrospectively evaluated, bleeding was ended in 14 of 16 patients and it was reported that cyanoacrylate was an effective embolizing agent (Lee et al., 2007).

In a similar study by Jae et al., it was demonstrated that cyanoacrylate was a very effective and safe agent, especially when it was not possible to advance the microcatheter to the bleeding site and in the presence of coagulopathy (Jae et al., 2007). Low risk of intestinal ischemia is an important advantage of the coils due to the preservation of the distal arterial bed (Padia et al., 2009). In our study, the most common etiological cause was malignancy and PVA, microsphere or cyanoacrylate were preferred for the embolization of the tumor vascular bed (Fig. 2). Coil was used as an embolizing agent in three patients with pseudoaneurysm on the background of gastroduodenal ulcer. In addition to acute ischemia that may develop after embolization, duodenal stenosis secondary to avascular necrosis caused by severe hypoxia in the long-term period is another important complication (Walsh et al., 1999; Whitaker and Gregson, 1993).



**Fig. 2.** A 56-year-old woman presented with persistent melena. Angiography of the superior mesenteric artery shows the feeding arteries of the liposarcoma (A). A super selective microcatheter is placed in the right ileocolic artery for embolization (B). Microsphere was injected under continuous fluoroscopy. Angiography after TAE shows disappearance of the tumor enhancement (C)

In a study evaluating the long-term outcomes and complications of TAE in duodenal ulcer bleeding, duodenal stenosis developed in seven (25%) of 28 patients when cyanoacrylate was mostly used, eight months to seven years after embolization of terminal vessels (Lang, 1992). In our series, duodenal stenosis was not detected in any patient who

## References

1. Aina R., Oliva V.L., Therasse E., Perreault P., Bui B.T., Dufresne M.P., Soulez G., 2001. Arterial embolotherapy for upper gastrointestinal hemorrhage: outcome assessment. *J. Vasc. Interv. Radiol.* 12(2), 195-200.
2. Arber N., Tiomny E., Hallak A., Santo M., Moshkowitz M., Konikoff F.M., Shumla V., Rozen P., Gilat T., Rattan J. 1994. An eight-year experience with upper gastrointestinal bleeding: diagnosis, treatment and prognosis. *J. Med.* 25, 261–269.
3. Barnert, J., Messmann, H., 2009. Diagnosis and management of lower gastrointestinal bleeding. *Nat. Rev. Gastroenterol. Hepatol.* 6, 637-646.
4. Chan, V., Tse, D., Dixon, S., Shrivastava, V., Bratby, M., Anthony, S., Patel, R., Tapping, C., Uberoi, R., 2015. Outcome following a negative CT Angiogram for gastrointestinal hemorrhage. *Cardiovasc. Intervent. Radiol.* 38, 329–335.
5. Eriksson, L.G., Sundbom, M., Gustavsson, S., Nyman, R., 2006. Endoscopic marking with a metallic clip facilitates transcatheter arterial embolization in upper peptic ulcer bleeding. *J. Vasc. Interv. Radiol.* 17, 959-964.
6. Frattaroli, F.M., Casciani, E., Spoletini, D., Poletini, E., Nunziale, A., Bertini, L., Vestri, A., Gualdi, G., Pappalardo, G., 2009. Prospective study comparing multi-detector row CT and endoscopy in acute gastrointestinal bleeding. *World. J. Surg.* 33(10), 2209–2217.
7. Hreinsson, J.P., Kalaitzakis, E., Gudmundsson, S., Björnsson, E.S., 2013. Upper gastrointestinal bleeding: incidence, etiology and outcomes in a population-based setting. *Scand. J. Gastroenterol.* 48, 439-447.
8. Jae, H.J., Chung, J.W., Jung, A.Y., Lee, W., Park, J.H., 2007. Transcatheter arterial embolization of nonvariceal upper gastrointestinal bleeding with N-butyl cyanoacrylate. *Korean. J. Radiol.* 8(1), 48-56.
9. Lang, E.K., 1992. Transcatheter embolization in management of hemorrhage from duodenal ulcer: long-term results and complications. *Radiology.* 182 (3), 703-707.
10. Lee, C.W., Liu, K.L., Wang, H.P., Chen, S.J., Tsang, Y.M., Liu, H.M., 2007. Transcatheter arterial embolization of acute upper gastrointestinal tract bleeding with N-butyl-2-cyanoacrylate. *J. Vasc. Interv. Radiol.* 18(2), 209-216.
11. Lee E.W., Laberge J.M., 2004. Differential diagnosis of bleeding. *Tech.Vasc. Interv. Radiol.* 7(3), 112–122.
12. Loffroy, R., 2013. Management of nonvariceal upper gastrointestinal bleeding resistant to endoscopic hemostasis: will transcatheter embolization replace surgery? *Eur. J. Gastroenterol. Hepatol.* 25, 118.
13. Loffroy, R., Favelier, S., Pottecher, P., Estivalet, L., Genson, P.Y., Gehin, S., Cercueil, J.P., Krausé, D., 2015. Transcatheter arterial embolization for acute nonvariceal upper gastrointestinal bleeding: Indications, techniques and outcomes. *Diagn. Interv. Imaging.* 96 (7-8), 731-744.
14. Loffroy, R., Guiu, B., 2009. Role of transcatheter arterial embolization for massive bleeding from gastroduodenal ulcers. *World. J. Gastroenterol.* 15(47), 5889–5897.
15. Loffroy, R., Guiu, B., D'Athis, P., Mezzetta, L., Gagnaire, A., Jouve, J.L., Ortega-Deballon, P., Cheynel, N., Cercueil, J.P., Krausé, D., 2009. Arterial embolotherapy for endoscopically unmanageable acute gastroduodenal hemorrhage: Predictors of early rebleeding. *Clin. Gastroenterol. Hepatol.* 7(5), 515-523.
16. Manning-Dimmitt, L.L., Dimmitt, S.G., Wilson, G.R., 2005. Diagnosis of gastrointestinal bleeding in adults. *Am. Fam. Physician.* 71, 1339-1346.
17. Nusbaum, M., Baum, S., Blakemore, W.S., 1969. Clinical experience with the diagnosis and management of gastrointestinal hemorrhage by selective mesenteric catheterization. *Ann. Surg.* 170 (3), 506–514.
18. Padia, S.A., Geisinger, M.A., Newman, J.S., Pierce, G., Obuchowski, N.A., Sands, M.J., 2009. Effectiveness of coil embolization in angiographically detectable versus non-detectable sources of upper gastrointestinal hemorrhage. *J. Vasc. Interv. Radiol.* 20(4), 461-466.
19. Peynircioğlu, B., Erkuş, F., Cil, B., Ciftçi, T., Durhan, G., Balkancı, F., 2011. Mesenteric angiography of patients with gastrointestinal tract hemorrhages: a single center study. *Diagn.*

underwent gastroduodenal artery embolization. This may be due to the short follow-up period, as well as not using cyanoacrylate in gastroduodenal artery embolizations. Also, none of the patients had intestinal infarction or off-target embolization in our study.

AGIB requires a multidisciplinary approach that gastroenterologists, surgeons, and interventional radiologists should act together. TAE is an effective, reliable and minimally invasive treatment method in AGIB treatment. In order to increase the success rate of the procedure and avoid possible complications, interventional radiologists should have sufficient information about the flow dynamics in the targeted artery, the properties of the embolic agents and the mechanism of occlusion.

## Conflict of interest

None.

## Acknowledgments

None.

- Interv. Radiol. 17, 368–373.
20. Rösch, J., Dotter, C.T., Brown, M.J., 1972. Selective arterial embolization. A new method for control of acute gastrointestinal bleeding. *Radiology*. 102, 303–306.
  21. Shi, Z.X., Yang, J., Liang, H.W., Cai, Z.H., Bai, B., 2017. Emergency transcatheter arterial embolization for massive gastrointestinal arterial hemorrhage. *Medicine (Baltimore)*. 96(52), e9437.
  22. Širvinskas, A., Smolskas, E., Mikelis, K., Brimienė, V., Brimas, G., 2017. Transcatheter arterial embolization for upper gastrointestinal tract bleeding. *Wideochir. Inne. Tech. Maloinwazyjne*. 12(4), 385-393.
  23. Sos, T.A., Lee, J.G., Wixson, D., Sniderman, K.W., 1978. Intermittent bleeding from minute to minute in acute massive gastrointestinal hemorrhage: arteriographic demonstration. *AJR. Am. J. Roentgenol*. 131, 1015– 1017.
  24. Walker, T.G., Salazar, G.M., Waltman, A.C., 2012. Angiographic evaluation and management of acute gastrointestinal hemorrhage. *World. J. Gastroenterol*. 18, 1191–1201.
  25. Walsh, R.M., Anain, P., Geisinger, M., Vogt, D., Mayes, J., Grundfest-Broniatowski, S., Henderson, J.M., 1999. Role of angiography and embolization for massive gastroduodenal hemorrhage. *J. Gastrointest. Surg*. 3(1), 61-65.
  26. Weldon, D.T., Burke, S.J., Sun, S., Mimura, H., Golzarian, J., 2008. Interventional management of lower gastrointestinal bleeding. *Eur. Radiol*. 18, 857–867.
  27. Whitaker, S.C., Gregson, R.H., 1993. The role of angiography in the investigation of acute or chronic gastrointestinal haemorrhage. *Clin. Radiol*. 47(6), 382-388.