

Bir Çocuk Hastada Foley Sonda ile Özofagustan Yabancı Cisim Çıkarılmasının Nadir Bir Komplikasyonu: Özofagus Rüptürü

A Rare Complication of Foreign Body Removal from the Oesophagus by Foley Catheter in A Child: Esophageal Rupture

Tugay TARTAR¹, Unal BAKAL¹, Mehmet SARAC¹, Yesim EROGLU², Ahmet KAZEZ¹

¹ Fırat University Faculty of Medicine, Department of Pediatric Surgery, Elazığ, Turkey

² Fırat University Faculty of Medicine, Department of Radiology, Elazığ, Turkey

Özet

Özofagus yabancı cisimlerinde (YC) tanı ve tedavinin gecikmesi morbidite ve mortaliteyi artırır. Tanıda anamnez, radyolojik görüntüleme ve endoskopi önemlidir. Dokuz aylık erkek hasta bir saat önce madeni para yutma şikayetiyle hastaneye başvurmuş. Akciğer grafisinde özofagus 2. darlıkta görülen YC foley sonda ile çıkarılmış. YC'nin çıkarılmasından 6 saat sonra boyun ve göğüs kısmında şişlik gelişmesi üzerine acil servise başvurdu. Fizik muayenede toraks ön duvarında cilt altı krepitasyon mevcuttu. Özofagografide kontrast maddenin özofagus sağ lateralden göğüs boşluğuna kaçtığı görüldü. Skopi eşliğinde nazogastrik sonda takıldı, orali kapatıldı ve antibiyoterapi başlandı. Konservatif takibin 7. gününde genel durumunun bozulması ve floroskopide kontrast madde kaçığının devam etmesi üzerine torakotomi ile özofagus primer onarımı yapıldı. Sonuç olarak, Özofagus YC'lerinin çıkarılmasında foley sonda kullanımı ciddi komplikasyona yol açabilir.

Anahtar kelimeler: Özofagus, Yabancı cisim, Foley sonda, Rüptür

Abstract

Delay in diagnosis and treatment of esophageal foreign bodies (FBs) increase morbidity and mortality. Anamnesis, radiological imaging and endoscopy are important in the diagnosis. A nine-month-old male patient was admitted to the hospital with complaint of swallowing a coin an hour ago. Chest x-ray image detected the FB in the 2nd narrowing of the oesophagus, and the FB was removed using a Foley catheter. Six hours after removal of the FB, the patient was re-admitted to the emergency service upon development of puffiness in the neck and chest. Physical examination revealed subcutaneous crepitation on the anterior wall of the chest. Esophagography revealed that the contrast agent leaked from the right lateral of the oesophagus into the chest cavity. The nasogastric tube was inserted, the oral nutrition was stopped and antibiotherapy was started. Primary oesophagus repair was performed via thoracotomy on the 7th day of conservative follow-up upon the deterioration of the general condition and continuing leakage of contrast agent as observed in the fluoroscopy. In conclusion, The use of Foley catheter in the removal of esophageal FBs may lead to serious complications such as rupture.

Keywords: Esophagus, Foreign body, Foley catheter, Rupture

Yazışma Adresi: Tugay TARTAR, Fırat Üniversitesi Tıp Fakültesi, Çocuk Cerrahi ABD, Elazığ, Türkiye

Telefon: +0 506 632 01 00 Mail: tugaytartar@gmail.com

ORCID No (Sırasıyla): 0000-0002-7755-4736, 0000-0002-5140-8618, 0000-0003-3636-4810, 0000-0003-0440-3555

Geliş Tarihi: 25.11.2020

Kabul Tarihi: 11.12.2020

DOI: 10.17517/ksutfd.831382

INTRODUCTION

Esophageal foreign bodies (EFBs) are common in infancy and play-age childhood (1). They can cause severe morbidity and mortality unless diagnosed and treated on time and using the appropriate method. EFBs constitute 28–68% of all gastrointestinal foreign bodies (2). The use of Foley catheter, which is an alternative treatment approach for EFB removal, has been increasing in recent years (3).

The present case has been studied herein to highlight the complications that may develop because of the use of the Foley catheter for EFB removal.

CASE PRESENTATION

A nine-month-old male patient was admitted to the local hospital an hour after swallowing a coin (a 10 kuruş coin). The chest X-ray showed a foreign body (FB) in the 2nd narrowing of the oesophagus (**Figure 1**). The patient was discharged after the FB was removed using a Foley catheter. Approximately 6 hours after the FB removal, swelling developed in the neck and chest of the patient, and the family contacted the emergency room of a tertiary hospital. Physical examination revealed subcutaneous crepitation in the neck, shoulder and on the anterior chest wall. The lung sounds were bilaterally coarse. Oxygen saturation was between 90% and 95%, and the white blood cell count was $15.50 \times 10^3/\mu\text{L}$. No marked features were observed in other laboratory parameters and blood gas. The chest X-ray showed significant subcutaneous emphysema. Thoracic computed tomography also revealed subcutaneous emphysema on the anterior wall of the neck and chest, and pneumomediastinum reaching 3 cm in the widest place that applied pressure to the heart in the mediastinal area. Oesophageal integrity was disturbed and the adjacent air values continued in fine calibration and irregularly up to the subcarinal area (**Figure 2**). Oesophagography showed a leakage of contrast agent from the right lateral of the oesophagus to the chest cavity (**Figure 3**). A nasogastric catheter was inserted into the patient's nose under the guidance of scopy, oral intake stopped, and antibiotic therapy was started. Conservative follow-up in intensive care unit (ICU) was planned. On the 7th day of the follow-up in

ICU, upon decreasing the oxygen saturation, fever, continuing leakage in the control esophagography, it was decided to surgery. During the right-lateral thoracotomy, an approximately 2.5-cm-long full-thickness defect of the oesophagus was observed and repaired primarily. On postoperative day 14,

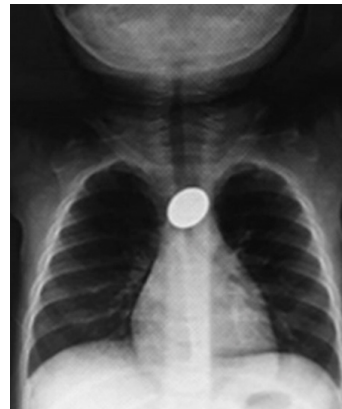

Figure 1. Foreign body in the 2nd narrowing of the esophagus in the chest X-ray.

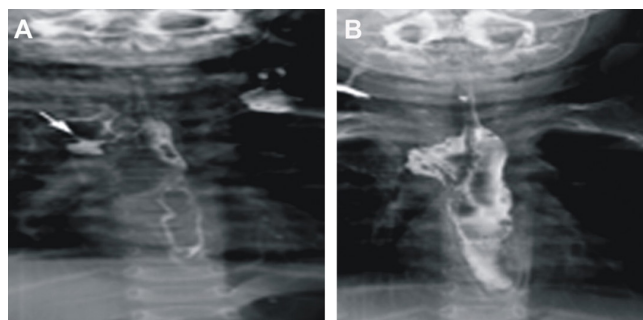


Figure 2A. Axial computed tomography of the chest showed widespread subcutaneous emphysema in the neck and between soft tissues (arrow). **B.** Axial computed tomography of the chest showed intense mediastinal air (emphysema) in the precardiac area in the mediastinal (arrow). **C.** Computed tomography of the chest without coronal contrast showed an inserted nasogastric catheter. Additionally, there was a defect in the right wall of the oesophagus in the thoracic oesophagus proximal (arrow).

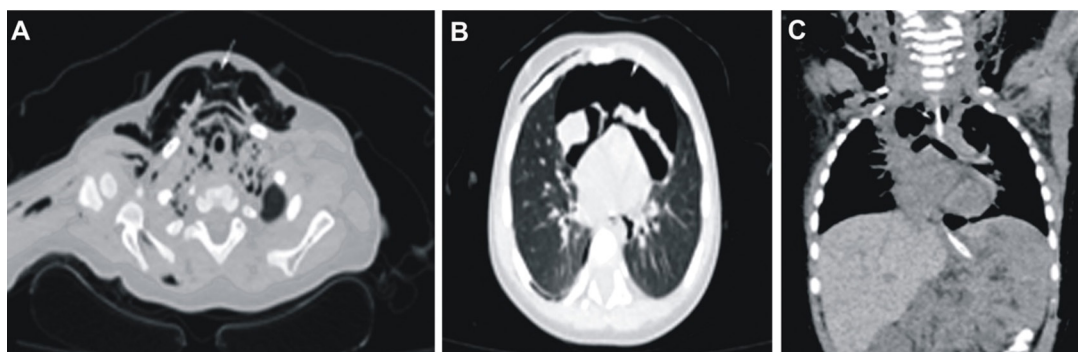


Figure 3. The oesophagography image showed extralumination of the contrast agent administered in the thoracic oesophageal proximal into the mediastinal area (arrow).

feeding was started through the nasogastric tube, and on day 21 after surgery the nasogastric tube was removed and oral feeding was started. The patient was discharged on postoperative day 26. During the check-up examination in postoperative month 3, it was observed that the contrast agent reached the stomach smoothly from the oesophageal lumen and there was no leakage. There were no complications in the postoperative 6-month follow-up. Written informed consent was obtained from the patient's parent who participated in this study.

DISCUSSION

As the oesophagus is the narrowest part of the upper gastrointestinal tract, FBs are often stuck in this organ. EFB is particularly common in children under 6 years of age (1). The most commonly swallowed FBs are metal coins and pieces of toys (1,4).

Anamnesis, radiological imaging and endoscopy are important for EFB diagnosis (5). This diagnosis is difficult via physical examination. The most common complaints in the early stages are coughing, wheezing, increased secretion, and a feeling of something being stuck. In later stages, recurrent lung infections and clinical images similar to bronchial asthma may develop (6,7). Patients may also develop respiratory distress owing to tracheal pressure, aspiration as a result of vomiting and cardiac arrest (3,8).

Treatment of oesophageal FBs is urgent because of the narrow oesophageal passage, complications in the attempts due to edema, perforation of the oesophagus and the risk of aspiration (3,9). Today, the standard treatment for EFB removal is rigid oesophagoscopy (1-5), as it is the easiest and most reliable method. Rigid oesophagoscopy enables for the visible and controlled removal of the mostly (90-99%) EFBs (1). In addition, defecation of the FB by pushing it into the stomach or its surgical removal, flexical oesophagoscopy and McGill clamp use in upper oesophageal FBs are other methods used in treatment (4). Currently, particularly in cases where operating room conditions are not met, respiratory distress occurs; hence, the nasally-inserted Foley catheter can be used to remove the EFB in such cases (3). In the first use of the Foley catheter, the aim was to push the FB into the stomach. However, currently, the Foley catheter is often used to remove a FB (3). Foley probe use is recommended in cases where the FB has remained for less than 24 h in the oesophagus, does not cause complete obstruction, respiratory distress, and in cases that do not include previous oesophagus surgery, the patient is not in infancy and where the ingested FB is known (10). In the case presented herein, FB removal using Foley catheter was not performed with fluoroscopy as the concerned patient was in infancy.

Complications such as oesophageal perforation, oesophagitis, respiratory distress and aspiration may arise because of FB removal using the Foley catheter (11). The most important reason for the development of complications is the uncontrolled and blind manner of performing interventions.

Although it is reported that Foley catheter use should be performed in a controlled manner under the guidance of fluoroscopy, routine use of it is not recommended (11).

Fluoroscopy examinations with a contrast agent are important for detecting complications (9). In our case, wherein examination was not performed through fluoroscopy using a contrast agent after the procedure, the diagnosis was delayed. It was reported that morbidity with rigid oesophagoscopy was less than 1%, the risk of perforation was 0.34% and the mortality was 0.05% (12). Its main advantage is that it allows the visualization and removal of the FB in a controlled manner and the exposure of the damage to the oesophagus along with additional pathologies of the FB. No information on the complication rates due to the use of Foley catheter were found in the literature.

As a conclusion, rigid oesophagoscopy, which can be accessed in almost every healthcare center currently, is the most reliable method of treating EFB. We believe that the use of Foley catheter to remove the FB from the oesophagus should not be preferred because it can cause life-threatening complications especially in infancy.

Conflict of Interest and Financial Status: Our study has not been financed by an institution and institution. In this study, there is no conflict of interest among the authors on any subject.

Author Contribution: All authors contributed equally to the article.

REFERENCES

1. Çelik S, Aydemir B, Tanrikulu H, Okay T, Doğusoy I. Esophageal foreign bodies in children and adults: 20 years experience (abstract in English). *Ulus Travma Acil Cerrahi Derg.* 2013;19(3):229-34.
2. Aydın Y, Ulaş AB, Kaynar H. Esophageal foreign bodies (abstract in English). *Toraks Cerrahisi Bülteni.* 2011;4:254-9.
3. Kaya F, Çiftçi İ, Seçkin AN. A rare method for taking the swallowed foreign bodies out of the children (abstract in English). *Selçuk Tıp Derg.* 2014;30(2):79-81.
4. Köseoğlu B, Bakan V, Bilici S, Önem Ö, Katı İ, Demirtaş İ. Çocukluk çağı gastrointestinal yabancı cisimlerinin tedavisi. *Van Tıp Derg.* 2001;8(2):47-53.
5. Çobanoğlu U, Aşker S, Sayır F. Esophageal foreign bodies. *J Clin Anal Med.* 2014;5(suppl 2):234-9.
6. Büyükyavuz İ. Çocukluk çağında yabancı cisim aspirasyonları. *Klinik Pediatri.* 2003;2(2):47-51.
7. Gmeiner D, von Rahden BH, Meco C, Hutter J, Oberacher G, Stein HJ. Flexible versus rigid endoscopy for treatment of foreign body impaction in the esophagus. *Surg Endosc.* 2007;21(11):2026-9.
8. Waltzman M. Management of esophageal coins. *Pediatr Emerg Care.* 2006;22:367.
9. İnci İ, Özçelik C, Ülkü R, Eren N. Esophageal foreign bodies: analysis of 682 patients (abstract in English). *GKDC Dergisi.* 1999;7:148-52.
10. T-Ping C, Nunes CA, Guimarães GR, Vieira JPM, Weckx LLM, Borges TJA. Accidental ingestion of coins by children: management at the ENT Department of the João

- XXIII Hospital. *Braz J Otorhinolaryngol.* 2006;72:470-4.
11. Uyemura MC. Foreign body ingestion in children. *Am Fam Physician.* 2005;72:287.
 12. Athanassiadi K, Gerazounis M, Metaxas E, Kalantzi N. Management of esophageal foreign bodies: a retrospective review of 400 cases. *Eur J Cardiothorac Surg.* 2002;21:653-6.