

## Numb Chin Syndrome: A Sign of Lung Adenocarcinoma

### Uyuşuk Çene Sendromu: Akciğer Adenokarsinomunun Bir İşareti

Hüseyin GÜLCAN<sup>1\*</sup>, Uğur GÜLŞEN<sup>1</sup>

<sup>1</sup>Zonguldak Bülent Ecevit University Faculty of Dentistry Department of Oral and Maxillofacial Surgery, Zonguldak, Turkey

### Ö Z E T

**Amaç:** Duyusal bir nöropati olan ve kaybı zamanda mental nöropati olarak da bilinen uyuşuk çene sendromu (UÇS), alt dudak, diş eti ve ağız mukozasında parestezi ya da his aynı ile karakterizedir. Bu durum, malignitelerle ilişkili olabileceğinden endişe verici olarak kabul edilmektedir. **Olgu:** 34 yaşında kadın hasta sağ alt dudakta parestezi şikayeti ile kliniğe başvurdu. Radyografik incelemede inferior alveolar siniri içine alan bir litik lezyon tespit edildi. Lokal anestezi altında biyopsi yapıldı. Örneğin histopatolojik incelemesinin ardından adenokarsinom tanısı konuldu. Hasta daha sonra onkoloji bölümüne yönlendirildi. İncelemeler sonucunda birincil nedenin akciğer adenokarsinomu olduğu tespit edildi. **Sonuç:** Bu vaka raporu UÇS'li hastaların çok dikkatli değerlendirilmesi gerektiğini vurgulamaktır çünkü bu durum bir sistemik malignitenin belirtisi olabilmektedir.

**Anahtar Kelimeler:** Akciğer Adenokarsinomu, Kanser, Malignite, Tümörler, Uyuşukluk

Alınış / Received: 19.12.2020 Kabul / Accepted: 01.02.2021 Online Yayınlanma / Published Online: 25.04.2021

### ABSTRACT

**Objective:** Numb chin syndrome (NCS), which is a sensory neuropathy and also known as mental neuropathy, is characterized by paresthesia or decreased sensation in lower lip, gingiva and oral mucosa. This condition is regarded as worrisome because it may be associated with malignancies. **Case:** A 34-year-old female patient referred to the clinic with complaint of paresthesia in right lower lip. A lytic lesion involving the inferior alveolar nerve was detected on radiographic examination. Biopsy was done under local anesthesia. After the histopathological examination of the sample the diagnosis of adenocarcinoma was made. The patient was then referred to the department of oncology. As a result of the examinations, it was found that the primary cause was lung adenocarcinoma. **Conclusion:** This case report emphasizes that patients with NCS should be evaluated very carefully because this condition may be a symptom of a systemic malignancy.

**Keywords:** Adenocarcinoma of Lung, Cancer, Malignancy, Numbness, Tumors



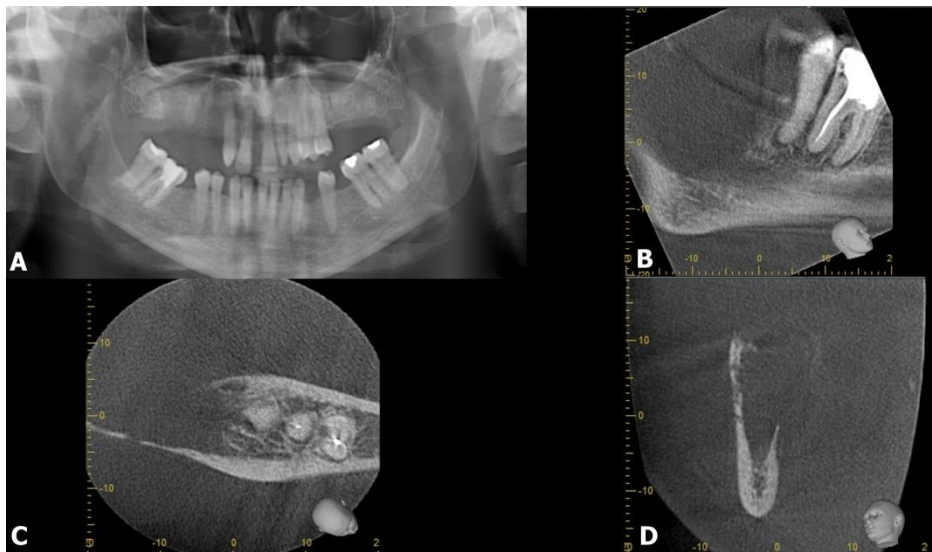
## 1. Introduction

For people who have experienced local anesthesia on the dentist's chair, a symptom that seems harmless, such as numbness in the jaw, sometimes reflects an underlying malignancy (1). Numb chin syndrome (NCS) is an uncommon cranial neuropathy. It is a condition manifested by sensory disturbances (anesthesia, hypoesthesia or paresthesia) along the distribution of the mental nerve or inferior alveolar nerve (2). Different sensations along the cutaneous distribution of the mental branch of the trigeminal nerve may occur as a result of injuries during anesthesia, fractures, osteotomies and osteotomies. Less commonly, it can result from infections of masseteric space, benign intra-osseous cystic lesions or locally invasive intraoral malignancies (3). Although many etiological factors have been reported, the most worrying issue is that this condition is associated with systemic malignancies (4).

Metastasis to the oral cavity can occur both bones and soft tissues, and this constitutes only 1% of all oral malignancies. In contrast to this low rate, this is clinically very important because it points out a common metastatic disease and an unfavorable prognosis (5).

Galán Gil *et al.* (4) analyzed 136 cases with NCS in systematic review and reported that the most related malignancy with NCS was breast cancer (40,4%), followed by lymphomas (20,5%), prostate cancer (6,6%), leukemia (5,1%), myeloma/plasmocytoma (3,8%), lung cancer (2,9%), Hodgkin's disease (2,9%) and sarcoma (2,9%).

Numb chin is an important indicator of oral metastasis. However, it can also be seen as a result of dental and systemic pathologies (5). Aim of this study is to draw attention to the fact that a numbness in the jaw that is ignored considering that it is due to dental causes may be a sign of a systemic malignancy.

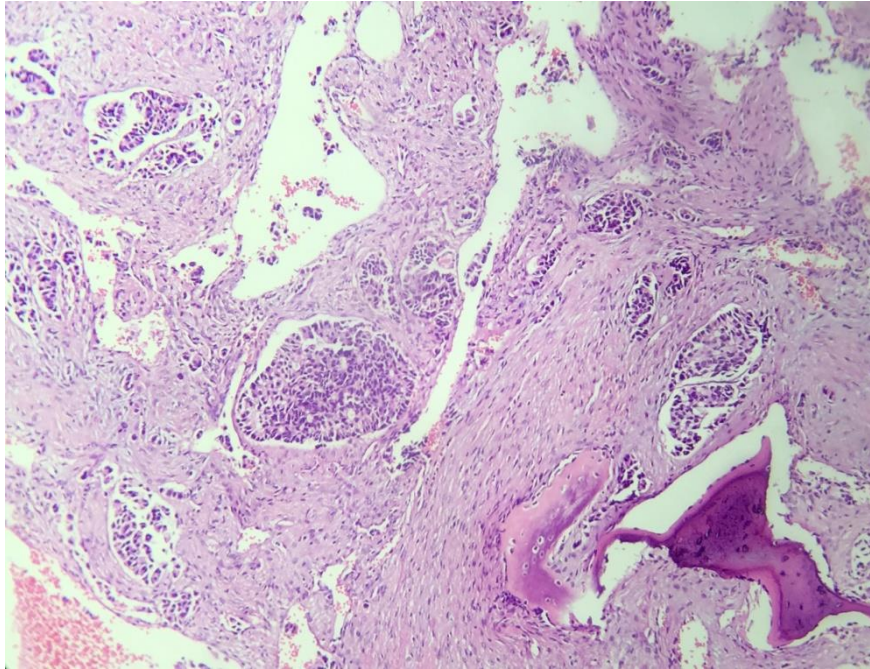


**Figure 1.** No obvious lesion in panoramic radiography (A) of patient with numbness in the right lower lip. Cone beam computerized tomography scans: sagittal (B), axial (C), coronal (D) showed osteolytic lesion involving the inferior alveolar nerve.

## 2. Case Report

A 34-year-old female patient referred to XXX with numbness in right lower lip. Although there was no obvious lesion on panoramic radiography, cone beam computerized tomographic evaluation showed a large lytic lesion involving the inferior alveolar nerve in the right posterior region of the mandible (Figure 1). Written informed consent was obtained from the patient. Biopsy was done under local anesthesia. Histopathological evaluation showed invasive carcinoma which showed infiltration within desmoplastic stroma and among bone trabeculae. The tumor consisted of atypical epithelial cells showing glandular array. Vacuolization in some cell cytoplasm and mucin in some gland lumens were seen.

The tumor showed perineural invasion (Figure 2). After the examination, she was diagnosed with adenocarcinoma. The patient was referred to the department of oncology. After the examinations, it was seen that the primary cause was lung adenocarcinoma. The treatment of the patient was started in this department but after approximately 4 months, the patient deceased.



**Figure 2.** Histological sample shows a malignant tumor consisting of atypical epithelial cells with cribriform and tubule-like array infiltrating into the bone and connective tissue (HEEx100).

### 3. Discussion

Primary cancers of lung, breast, kidney and bone are the most common sources of metastatic tumors of the oral cavity. While the breast is the primary tumor site that metastasizes to the jaw bones, the most common cancer that metastasizes to the oral soft tissues is the lungs (6). In this case, the source of metastasis is the lungs.

NCS is an important marker showing the progression and relapse of insidious cancers (7). NCS is usually seen unilaterally, but it can also be seen bilaterally (1,8). In this case, NCS was seen unilaterally. Galán Gil *et al.* (4) stated that NCS had an unfortunate prognosis due to 78,5% mortality rate and average survival time of 6,9 months.

The most common causes of this syndrome are dental causes such as iatrogenic conditions, tooth root infections, osteomyelitis of the mandible (acute and chronic), odontogenic and non-odontogenic tumors and mandibular cysts. Other causes are neoplasms, malignant more commonly than benign, metastatic more commonly than primary (9). In addition, NCS was found to be associated with inflammatory, infectious, immune and pharmaceutical etiologies including lupus, HIV, sarcoidosis and biphosphonate therapy (10). In this case, the cause of NCS is metastasis of lung adenocarcinoma to mandible.

### 4. Conclusion

In presence of NCS, the physician should search for a neoplasia. NCS is a harbinger of progression or relaps and indicator of poor prognosis in patients with a malignancy. Therefore, this is an important symptom that should not be underestimated.

## References

- [1] Bruyn RP, Boogerd W. The numb chin. *Clin Neurol Neurosurg.* 1991;93(3):187-93.
- [2] Colella G, Giudice A, Siniscalchi G, Falcone U, Guastafierro S. Chin numbness: a symptom that should not be underestimated: a review of 12 cases. *Am J Med Sci.* 2009;337(6):407-10.
- [3] Eppley BL, Snyders RV, Jr. Mental neuropathy as a sign of distant malignancy: report of cases. *J Oral Maxillofac Surg.* 1992;50(10):1117-9.
- [4] Galán Gil S, Peñarrocha Diago M, Peñarrocha Diago M. Malignant mental nerve neuropathy: systematic review. *Med Oral Patol Oral Cir Bucal.* 2008;13(10):E616-21.
- [5] Aerden T, Grisar K, Neven P, Hauben E, Politis C. Numb chin syndrome as a sign of mandibular metastasis: A case report. *Int J Surg Case Rep.* 2017;31:68-71.
- [6] Hirshberg A, Shnaiderman-Shapiro A, Kaplan I, Berger R. Metastatic tumours to the oral cavity - pathogenesis and analysis of 673 cases. *Oral Oncol.* 2008;44(8):743-52.
- [7] Balamurugan N, Arathisenthil SV, Senthilkumaran S, Thirumalaikolundusubramanian P. Numb chin syndrome: A harbinger of tumor progression or relapse. *Am J Emerg Med.* 2017;35(5):805.e1-.e2.
- [8] Hiraki A, Nakamura S, Abe K, Takenoshita Y, Horinouchi Y, Shinohara M, et al. Numb chin syndrome as an initial symptom of acute lymphocytic leukemia: report of three cases. *Oral Surg Oral Med Oral Pathol Oral Radiol Endod.* 1997;83(5):555-61.
- [9] Bar-Ziv J, Slasky BS. CT imaging of mental nerve neuropathy: the numb chin syndrome. *AJR Am J Roentgenol.* 1997;168(2):371-6.
- [10] Smith RM, Hassan A, Robertson CE. Numb Chin Syndrome. *Curr Pain Headache Rep.* 2015;19(9):44.