

Frequency of Sacral Dymorphism Findigs in Mugla Region

Muğla Bölgesinde Sakral Dismorfizm Bulgularının Sıklığı

Rabia Mihriban KILINÇ¹, Cem Yalın KILINÇ², Fatih İlker CAN², Emre GÜLTAÇ², İsmail Gökhan ŞAHİN², Nevres Hürriyet AYDOĞAN²

¹Mugla Sıtkı Kocman University, School of Medicine, Department of Radiology, Mugla

²Mugla Sıtkı Kocman University, School of Medicine, Department of Orthopedic and Traumatology, Mugla

Abstract

This retrospective study aims to reveal the prevalence of sacral dymorphism, the proportion of its findings and signs and its clinical importance in pelvic surgeries. 1753 nontraumatic pelvic and lower abdominal CT images were analyzed to reveal the sacral abnormal anatomy and dymorphic signs in nontraumatic patients. Of the patients included in the study; S1-S2 residual disc in 879 (50.60%), the presence of mammillary body or mammillary process in 209 (12%), acute ascending descent in 182 (10.47%), tongue-in-groove sign in 178 (10.25%), deformity in the neural foramen in 168 (9.67%), and collinearity in 121 patients (7%) were detected. The parameters of non-circular amorphous first sacral foramen and lumbosacral disc distance being close to the iliac wing (collinearity) parameters were statistically significantly higher in women than in men ($p=0.027$; $p=0.005$). There was no statistically significant correlation between non-circular amorphous first sacral foramen and collinearity parameters and gender ($\phi=0.149$, $p=0.027$; $\phi=-0.188$, $p=0.005$). Noncircular amorphous first sacral foramen and residual disc distance between S1 and S2 were found to be statistically significantly higher in the cases ($p=0.039$). Sacral dymorphism is an abnormal anatomy that is seen much more common than it is thought in the population and plays an important role in clinical interventions. Keeping this anatomical difference in mind during surgical procedures involving sacrum reduces the possibility of encountering unwanted complications.

Keywords: Abnormal Sacrum, Pelvic Surgery, Pelvic Trauma, Sacral Dymorphism

Öz

Retrospektif olarak gerçekleştirilen bu çalışma, sakral dismorfizm prevalansını, bulgu ve belirtilerinin oranını, pelvik cerrahilerdeki klinik önemini ortaya koymayı amaçlamaktadır. Postravmatik dönemde olmayan hastalarda sakral anormal anatomi ve sakrumun dismorfik bulgularını ortaya çıkarmak için 1753 hastanın pelvik ve alt abdominal BT görüntüleri analiz edildi. Çalışmaya dahil edilen hastalardan; 879' unda (%50.60) S1-S2 rezidüel disk, 209'unda (%12) mamiller cisim veya mamiller proses varlığı, 182'sinde akut sakral iniş (%10.47), 178'inde tongue in groove işareti (%10.25), 168'inde deforme nöralforamen morfolojisi (%9.67) ve 121 hastada ise kolinearite (%7) tespit edildi. Kadınlarda dismorfik birinci sakralforamen ve colinearty erkeklerle göre istatistiksel olarak anlamlı derecede yükseldi ($p=0.027$; $p=0.005$). Dismorfikbirinci sakralforamen ile colinearty parametreleri ve cinsiyet arasında istatistiksel olarak anlamlı bir ilişki yoktu ($\phi=0.149$, $\phi=-0.188$). Dismorfikbirinci sakralforamen ve S1 ile S2 arasındaki rezidüel disk mesafesi olgularda istatistiksel olarak anlamlı yüksek bulundu ($p=0.039$). Sakraldismorfizm, toplumda düşünüldüğünden çok daha sık görülen ve klinik müdahalelerde önemli rol oynayan anormal bir anatomik görünümdür. Sakrum içeren cerrahi işlemler sırasında bu anatomik farklılığın akılda tutulması, istenmeyen komplikasyonlarla karşılaşma olasılığını azaltır.

Anahtar Kelimeler: Anormal Sakrum, Pelvik Cerrahi, Pelvik Travma, Sakral Dismorfizm

Introduction

The first knowledge about sacral dymorphism has begun to be revealed by studies conducted in patients with chronic pain in the lumbosacral region and pelvic fractures (1). Surgery in sacrum fractures can be performed for indications such as unstable pelvic fractures, the presence of neurological deficits, the distortion of the spinal axis, the development of pseudoarthrosis after conservative treatment and also for decompression (2). Posterior percutaneous transiliac plate fixation (PPTPF), percutaneous sacroiliac screw fixation (PSVF) and

posterior sacral bar applications are some of the techniques used in unstable pelvic ring fractures (2).

Studies have reported that percutaneous iliosacral screw fixation not only provides an appropriate reduction but also a stable fixation (3-9). Successful application of the method reduces mortality and morbidity due to iatrogenic injury (10). However, it is necessary to perceive the posterior pelvic anatomy and its variations in order to perform the procedure safely. The area, where the screws are applied, is a bone corridor and there are important neurovascular structures in its immediate vicinity. The highest risk of these structures belongs to the sacral nerve roots. Beyond the sacral nerve roots, the L5 nerve root is also at risk. Therefore, the screws should not damage the cortex around the bone corridor (11-16). Sacral dymorphism is an anatomical variation that causes complications by changing the shape and angle of this bone corridor.

Sacral dymorphism appears highly common and affects 30-40% of the population (17). Radiographic findings of sacral dymorphism are; a) Close distance from lumbosacral disc to the iliac wing (collinearity) b) oblique residual transverse process in the sacral wing (mammillary process) c) non-circular amorphous first sacral foramen d) residual disc distance between S1-S2 e) acute sacral alar drop

	ORCID No
Rabia Mihriban KILINÇ	0000-0002-6845-5496
Cem Yalın KILINÇ	0000-0003-2568-0500
Fatih İlker CAN	0000-0001-5880-5336
Emre GÜLTAÇ	0000-0003-1943-2199
İsmail Gökhan ŞAHİN	0000-0002-6274-6102
Nevres Hürriyet AYDOĞAN	0000-0002-1837-2676

Başvuru Tarihi / Received: 04.01.2021

Kabul Tarihi / Accepted : 26.04.2021

Adres / Correspondence : Cem Yalın KILINÇ
Mugla Sıtkı Kocman University, School of Medicine, Department of Orthopedic and Traumatology, Mugla
e-posta / e-mail : cykilinc@gmail.com

f) the presence of undular sacral articulation (tongue-in-groove sign). These findings not only affect the shape and angle of the screw corridor, but may also cause confusion on the fluoroscopic images during the operation (18).

Our aim in this study is to determine the proportion of sacral dysmorphism findings in our region and to draw attention to the issues that should be considered during surgery in patients with sacral dysmorphism. Since our region is a holiday resort region, the population increases significantly especially in summer and accordingly, many trauma cases are encountered. Most of these incidents are caused by high-energy car accidents and pelvic ring injuries are also very common. Therefore, the possibility of sacral dysmorphism should be kept in mind by surgeons as this situation may completely affect the surgery. To the best of our knowledge in the literature, there is a few studies about sacral dysmorphism in Turkey.

Material and Method

In our study, all computerized tomography (CT) examinations involving the lower abdomen (abdominopelvic CT, pelvic CT) taken between October 2019 and January 2020 at the MuğlaSıtkıKoçman University Training and Research Hospital were retrospectively evaluated in terms of sacral dysmorphism findings. CT examinations were performed in routine algorithm (axial plane, 5 mm slice thickness) with dual core Siemens Definition Flash (Siemens Healthcare, Germany) tomography device with 128 detectors. The images were transferred and processed on the Syngo Via workstation. Approval was obtained from the local ethics committee of our faculty for the study.

Patients over eighteen years old and who had a complete pelvis tomography were included in this study. However, the patients with lumbosacral fractures that may affect the evaluation of sacrum morphology, patients with implants that would make the evaluation of lumbosacral distance difficult and patients with severe osteoporosis that could affect the quality of the 3-dimensional (3D) images were excluded from this study. Age, gender, and the indications for CT imaging were noted for each patient in each report.

From all tomography examinations, sagittal and angulated coronal reformatted images and 3D images of bone structures were created at the workstation. Vascular structures enhanced in contrast were removed from the images for a better evaluation quality. 3D images were rotated on the axial axis for evaluation of the presence of mammillary bodies, the shape of the S1-S2 neural foramina, the presence of acute alar slope, the colinearity of the upper edge of the sacrum with the iliac wings. Residual S1 and S2 were also evaluated from sagittal-coronal

reformatted images (in sagittal sections passing through the mid-vertebra corpus). In addition, the tongue-in-groove finding was evaluated with coronal reformatted images inclined along the vertical axes of S1 and S2 vertebrae. Figures 1,2,3 and 4 show findings of sacral dysmorphism. Evaluations were made by a radiologist. Findings were noted as present or absent.

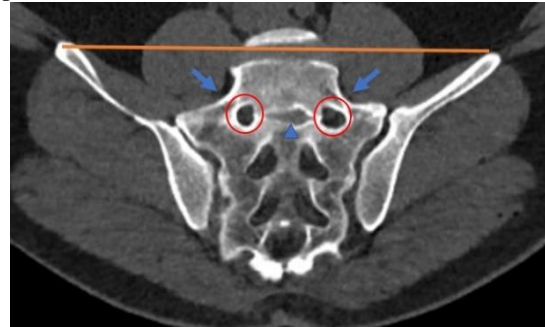


Figure 1. CT tomographic signs of sacral dysmorphism. In angulated coronally reformatted CT image of a dysmorphic sacrum demonstrating an acute alar slope (arrows), irregular neural tunnel exit with an irregularly round foramen (circles), a residual disk space is visualized between the dysmorphic upper and second sacral segments (arrowhead), colinearity (orange line)

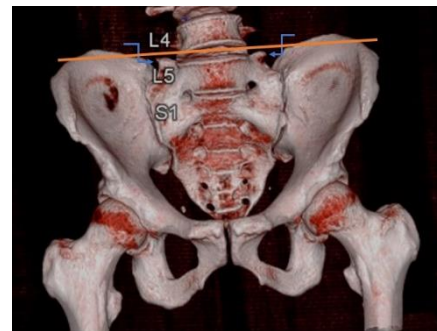


Figure 2. In three dimensional volume rendering CT view; mammillary processes in the alar region (curved arrows), colinearity (orange line)

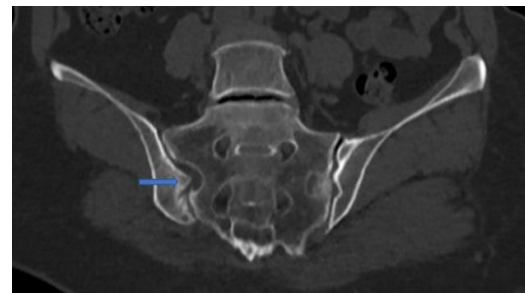


Figure 3. In coronally reformatted CT image; tongue in Groove morphology (long arrow)

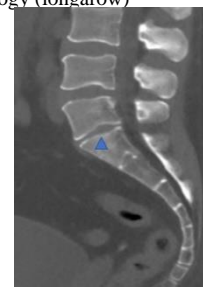


Figure 4. In sagittal reformatted CT image residual disc (arrowhead)

Statistical analyses were performed using SPSS v.21.0 software (SPSS Inc., IBM Corporation, Armonk, New York, USA) and power analysis was performed using G-Power v.3.1.9.4 software (Franz Faul, Universität Kiel, Germany). Before the study, power analysis was performed and the required sample size was determined for each group at 80% power ($d=0.8$) and 5% significance level ($p < 0.05$). Data in homogenous variance with normal distribution were examined with parametric test also mean and standard deviation was used for descriptive statistics. For categorical variables, Chi-square test was applied. The correlations were evaluated with Phi coefficient.

Results

Within this study, 1783 patients who had whole abdominal or pelvic CT examination between October 2019 and January 2020 were evaluated. Inclusion criteria included an age over eighteen years and imaging included entire pelvis. Exclusion criteria for the study can be stated as; the nonpresence of pelvic fractures (16 patients), the presence of implants in the lumbosacral area (13 patients), non-closure of the epiphyseal plates (4 patients), scoliosis above 20 degrees in the lumbar region (3 patients), spina bifida (4 patients), severe degeneration and bone deformation affecting the anatomical evaluation (7 patients). Consequently, 1737 patients were evaluated for the presence of sacral dysmorphism findings.

Tomography examinations were performed with the diagnosis of trauma, urinary stone disease, cancer follow-up, and abdominal pain. 74% of the CT studies were for the whole abdomen, 26% were for the pelvis. 82% of the CT evaluations were performed with contrast and 18% without contrast.

The mean age of the patients was calculated as 49.5 ± 17.4 years (18-90 years). 698 (42%) of the patients were female and 965 (58%) were male.

Of the patients included in the study; S1-S2 residual disc in 879 (50.60%), the presence of mammillary body or mammillary process in 209 (12%), acute ascending descent in 182 (10.47%), tongue-in-grove sign in 178 (10.25%), deformity in the neural foramen in 168 (9.67%), and colinearty in 121 patients (7%) (Table 1) were detected.

Table 1. Frequency of sacral dysmorphism findings

Sacral dysmorphism findings	Frequency	%
S1-S2 residual disc	879	50.60
Mammillary process	209	12
Acute ascending descent	182	10.48
Tongue-in-grove sign	178	10.25
Deformity in the neural foramen	168	9.67
Colinearty	121	7
Total	1737	100

As gender dissociation, the parameters of non-circular amorphous first sacral foramen and lumbosacral disc distance being close to the iliac

wing (colinearty) parameters were statistically significantly higher in women than in men ($p=0.027$; $p=0.005$). There was no statistically significant correlation between non-circular amorphous first sacral foramen and colinearty parameters and gender ($\phi=0.149$, $\phi=-0.188$) (Table 2).

Noncircular amorphous first sacral foramen and residual disc distance between S1 and S2 were found to be statistically significantly higher in the cases ($p=0.039$). There is no statistically significant correlation between residual disc length and non-circular amorphous first sacral foramen ($\phi=0.192$) (Table 2).

Table 2. Statistical data

	Gender	
	p value (χ^2)	Phi value
S1-S2 residual disc	0.027	0.149
Colinearty	0.005	-0.188
Acute ascending descent	0.469	0.490
Tongue-in-grove sign	0.062	-0.126
Deformity in the neural foramen	0.176	0.112
Mammillary process	0.574	0.058
First sacral foramen / residual disc distance between S1 and S2	0.039	0.192

Discussion

As the variety and amount of surgeries performed on patients with pelvic trauma increased, the necessity to understand the importance of anatomical differences of sacrum has also increased.

Sacral anatomy and lumbar spine association plays an important role as it may be related with lumbar back pain, coccydynia and even pelvic trauma mechanism. Therefore, understanding atypical lumbar and sacral anatomy is decisive for preoperative planning for pelvic trauma surgeries, spinal deformity reconstructions and sacroiliac joint approaches.

Although there is a wide spectrum of values in the literature regarding the prevalence of sacral dysmorphism, it is generally agreed by most authors that it has an incontrovertible high prevalence.

In a study performed by Joseph et al. in an adult patient group, the prevalence of sacral dysmorphism was found to vary between 30% and 40% (18). According to Weigelt et al. the prevalence of the dysmorphic sacral signs in total 269 CT scans, ranged from 5% (collinearity) to 70% (residual sacral disk space) and only 15% did not appear any sign of sacral dysmorphism. In a study of Kaiser et al., the prevalence was found varying between 28% and 53% (19). In our tomographic study, sacral dysmorphism rates were observed varying between 7% and 50.6% of the patients. While Kaiser et al. conducted this study in 104 nontraumatic pelvis, our study examined 1737 nontraumatic pelvis patients.

In a research achieved by Matson et. al, sacral abnormal anatomy was showed to play an important role in in evaluation of lower back pain, sacroiliac fusion, and pelvic trauma as it may cause neurological damage when the traditional screw placement zone is used (1).

Chung et al. also conducted a study emphasizing the importance of sacral abnormal anatomy in pelvic surgeries. They specified that sacral dysmorphism can cause inaccurate screw placement which may cause neurological damage. The CT data of 112 cadavers were investigated and the ideal placement of sacral screws were measured. According to their study, cortical violation around the screw was shown in sacral dysmorphism, if the violated (elevated) height exceeds 13 mm, traditional trans-sacral screw fixation should not be performed as this may cause neurological damage (20).

Radley et al. also showed in their study that sacral dysmorphism plays an important role in sacral screw placement. They emphasized that sacral morphology prescribes where iliosacral screws will be placed when performing surgeries of pelvic ring injuries; furthermore in an abnormal sacrum, the safe bony passage of the first sacral part (S1) is smaller and lacks a trans-sacral passage, expanding the need for fixation in the second sacral vertebrae (S2) (21).

Sacroiliac joint injuries and sacral fractures that cause posterior pelvic instability, require a well-established posterior stabilization thus this is very important for the continuity of the pelvic ring. Percutaneous posterior sacroiliac screwing is one of the most commonly used surgical methods for stabilization of the posterior ring. Although this method has proven efficacy, it is a very difficult procedure to apply (22). During percutaneous posterior sacroiliac screwing, neurovascular damage may occur in approximately 2 to 15% of patients as well as cortical perforation may develop during screwing (19,23). One of the most important difficulties encountered during the procedure is the complex anatomy of the posterior pelvic region. In this context, one of the most important causes of this complex anatomy is sacral dysmorphism, which is encountered quite common. After the determination of sacral dysmorphism and appropriate surgical planning, it has been observed that the rate of vascular nerve injury has decreased to 1% (4,8). This shows that; both Orthopedic surgeons who perform pelvic trauma surgery and the Radiologists preparing the report of the patient should pay special attention to dysmorphic changes in the sacral region.

Our most important limitation in this study is that measurements are made by a single radiologist.

In conclusion, among the diversities in pelvic anatomy, one of the most important entity is sacral dysmorphism. The presence of sacral dysmorphism may require some important modifications in surgical techniques due to its unique morphology, and surgical complications may be encountered with

conventional methods. Thus, sacral dysmorphism should always be kept in mind by both orthopedic surgeons and the radiologists when evaluating and treating a pelvic entity.

Ethics Committee Approval: Clinical Research Ethical Board of Muğla Sıtkı Koçman University was obtained with the letter dated 26.02.2020 and numbered 04/VIII.

References

1. Matson DM, McCormick LM, Sembrano JN et.al. Sacral Dysmorphism and Lumbosacral Transitional Vertebrae (LSTV) Review. *Int J Spine Surg.* 2020;14(1):14-9.
2. Kılıncı, C. Y. Posterior Pelvik Halka Yaralanmalarında Hangi Teknik Seçilmelidir: Perkütan Sakroiliak Vida Fiksasyonu Ya Da Posterior Perkutan Transiliak Plak Fiksasyonu? *Kırıkkale Üni Tıp Fak Derg.* 2019;21(1):80-4.
3. Enninghorst N, Toth L, King KL et.al. Acute definitive internal fixation of pelvic ring fractures in polytrauma patients: a feasible option. *J Trauma.* 2010;68(4):935-41.
4. Gardner MJ, Farrell ED, Nork SE, et al. Percutaneous placement of iliosacral screws without electrodiagnostic monitoring. *J Trauma.* 2009;66(5):1411-5.
5. Cole JD, Blum DA, Ansel LJ. Outcome after fixation of unstable posterior pelvic ring injuries. *Clin Orthop Relat Res.* 1996;(329):160-79.
6. Moed BR, Geer BL. S2 iliosacral screw fixation for disruptions of the posterior pelvic ring: a report of 49 cases. *J Orthop Trauma.* 2006;20(6):378-83.
7. Routt ML Jr, Gregor PJ, Simonian PT et.al. Early results of percutaneous iliosacral screws placed with the patient in the supine position. *J Orthop Trauma.* 1995;9(3):207-14.
8. Schweitzer D, Zylberberg A, C'ordova M et.al. Closed reduction and iliosacral percutaneous fixation of unstable pelvic ring fractures. *Injury.* 2008;39(8):869-74.
9. Alemdaroglu, K. B., Yücens, M., Kara, T. et.al. Pedicle axis view combined by sacral mapping can decrease fluoroscopic shot count in percutaneous iliosacral screw placement. *Injury.* 2014; 45(12):1921-7.
10. Tile MH, Kellam JF: *Fractures of the Pelvis and Acetabulum*, ed 3. Philadelphia, PA, Lippincott Williams & Wilkins, 1995; pp199-208.
11. Sagi HC, Lindvall EM. Inadvertent intraforaminal iliosacral screw placement despite apparent appropriate positioning on intraoperative fluoroscopy. *J Orthop Trauma.* 2005;19(2):130-3.
12. Altman DT, Jones CB, Routt ML Jr. Superior gluteal artery injury during iliosacral screw placement. *J Orthop Trauma.* 1999;13(3):220-7.
13. Ko PS, Kou SK. A rare complication of percutaneous iliosacral screw in a vertically unstable pelvic disruption in a child. *Injury.* 2001;32(2):159-61.
14. Peeters G, Govaers K, Himpens J. Successful laparoscopic exploration and screw extraction for intractable pain after anterior iliosacral arthrodesis. *J Orthop Trauma.* 2010;24(10):83-5.
15. Weil YA, Nousiainen MT, Helfet DL. Removal of an iliosacral screw entrapping the L5 nerve root after failed posterior pelvic ring fixation: a case report. *J Orthop Trauma.* 2007;21(6):414-7.
16. Templeman D, Schmidt A, Freese J et.al. Proximity of iliosacral screws to neurovascular structures after internal fixation. *Clin Orthop Relat Res.* 1996;(329):194-8.
17. Routt MLC, Simonian PT, Agnew SG, et al. Radiographic recognition of the sacral alar slope for optimal placement of iliosacral screws: a cadaveric and clinical study. *J Orthop Trauma.* 1996;(10):171-7.
18. Conflitti JM, Graves, ML, Routt Jr, MC. Radiographic quantification and analysis of dysmorphic upper sacral osseous anatomy and associated iliosacral screw insertions. *J Orthop Trauma.* 2010;24(10):630-6.

19. Kaiser SP, Gardner MJ, Liu J, et.al. Anatomic determinants of sacral dysmorphism and implications for safe iliosacral screw placement. JBJS. 2014; 96(14):e120.
20. Chung HJ, Park J, Sohn HS, et.al. The usefulness of reformatting CT scanning plane to distinguish sacral dysmorphism and introducing the variable of elevated height for predicting the possibility of trans-sacral screw fixation. Orthop Traumatol Surg Res. 2020;106(1):109-15.
21. Radley JM, Hill BW, Nicolaou DA, et.al. Bone density of first and second segments of normal and dysmorphic sacra. J Orthop Traumatol. 2020;21(1):1-6.
22. Ozmeric A, Yucens M, Gultaç E, et.al. Are two different projections of the inlet view necessary for the percutaneous placement of iliosacral screws? Bone Joint J. 2015;97:705-10.
23. Hinsche AF, Giannoudis PV, Smith RM. Fluoroscopy-based multiplanar image guidance for insertion of sacroiliac screws. Clin Orthop Relat Res. 2002;395:135-44.