

Sagittal anatomic investigation of the rabbit liver

Kamelia Stamatova-Yovcheva¹, Rosen Dimitrov¹, Ömer Gurkan Dilek², David Yovchev¹

¹Department of Anatomy, Histology and Embryology, Faculty of Veterinary Medicine, Trakia University, Stara Zagora/BULGARIA

²Department of Anatomy, Faculty of Veterinary Medicine, Burdur Mehmet Akif Ersoy University, Burdur/TURKEY

Key Words:

rabbit
liver
sagittal topography
anatomy

Received : 31.01.2021
Accepted : 20.03.2021
Published Online : 30.04.2021
Article Code : 871506

Correspondence:

K. STAMATOVA-YOVCHEVA
(kameliastamatovayovcheva@gmail.com)

ORCID

K. STAMATOVA-YOVCHEVA : 0000-0002-1121-0033
R. DIMITROV : 0000-0002-5308-838X
ÖG. DİLEK : 0000-0002-5717-3928
D. YOVCHEV : 0000-0003-4357-0858

ABSTRACT

The aim of the research was to study the topography of the liver and to image on computed tomography of the white New Zealand rabbit. We used ten rabbit cadavers. We obtained sagittal frozen cuts. At the level of the plane 10 mm to the left, the left medial lobe was cranial to the left lateral lobe. Caudally were the spleen, the left kidney and parts of the small and large intestines. At the level of the plane 20 mm to the left, the left lateral lobe touched caudally the stomach fundus and body, the papillary process was dorsal to the stomach fundus. At the level of the plane 10 mm to the right, the right lobe was cranially situated to the other lobes. Between the right lobe and caudate lobe were fundus and body of the stomach. Caudate process was caudal to the fundus of the stomach and dorsal to the cranial part of duodenum and ascending colon. It had anatomical contact with the right kidney. Papillary process covered the dorsal part of the stomach. At the level of the plane 20 mm to the right, the right lobe was cranial to the other lobes of the liver. The left medial lobe was covered partially by quadrate lobe. Gall bladder did not reach the ventral border of the liver. The left medial lobe was cranial to the body of the stomach. Caudate lobe touched the muscles of the spine.

INTRODUCTION

New Zealand rabbits are used to determine topographical features of the rabbit liver and other organs (1-5). Computed tomography (CT) methods are widely used in non-clinical basic research to study anatomical objects that are individually specific (6). Some authors introduce CT as innovative method for describing the abdominal anatomy in small animals. The used algorithm for determine the topography of the abdominal organs is for transverse CT (7) The sagittal CT is appropriate for visualization of the anatomical peculiarities of the human abdominal organs. Even more it gives detailed information via graphic displaying (8).

Precontrast computed tomography of the abdominal organs is an appropriate method for obtaining detailed anatomical information about the organs and vessels of small domestic mammals (9).

The anatomical representation of the liver in the domestic rabbit by means of CT corresponds to the data concerning the topography of the examined organ. CT is a comprehensive method for interpreting the anatomical features of the liver (lobes, topography and boundaries) in the rabbit in modern aspect (10).

In previous studies, Stamatova-Yovcheva et al. (11) and Stamatova-Yovcheva et al. (12) compared the anatomical features of the liver in the domestic rabbit on frozen

transverse sections with the transverse CT visualization of the examined organ. The authors prove that the data obtained in the anatomical examination (topography, number of sections, location of *vesica fellea* and adjacencies with other abdominal organs) complement the CT anatomical features of the liver in this animal species Dimitrov et al. (13) conducted a comparative CT anatomical investigation in sagittal aspect of the prostate and bubourethral glands in the domestic rabbit. The obtained imaging anatomical results present in detail the morphological features of the studied glands - location, bone markers, marking their topography and as well the presence of a prostate complex specific for this species.

CT imaging material is preferred for visualization of the normal topography of the rabbit liver compared to black and white photographic images of native frozen transverse sections, due to their lower quality. Image anatomical soft tissue findings are interpreted according to variations in CT density and gray-white scale (10).

Schapiro and Chiu (14) investigated the possibilities of axial CT for the anatomical visualization of human epigastric organs. The differentiation of anatomical structures from pathologically altered ones is based on the difference in densities that are specific to each tissue. CT and anatomical features of the organs in the *epigastrium* are used as a morphological basis in the differentiation of normal tissues in this abdominal area.

The disadvantage of the axial CT method is that it does not take into account the changes that occur in the resulting images during respiration. The difference between the axial and spiral CT method is that in the axial each tomographic slice is parallel to the other, while in the spiral, the images are spring-like (spiral) and each slice is at an angle to the other (15, 16).

It is evident that the scientific literature provides data mainly on the anatomical features of the liver in the rabbit in a transversal aspect. The information on the sagittal CT presentation of this organ is insufficient. These facts were motive to undertake this study. The aim of the research was to study the topography of the liver and to image on computed tomography of the white New Zealand rabbit.

MATERIAL and METHODS

Sagittal postmortem anatomical examination

We examined the cadavers of three male mature New Zealand rabbits which weights to 2.8 to 3 kilogram. Using an electric saw with a replaceable blade MAX RTR RTM908 (Turkey) we obtained sagittal frozen anatomical sections with a thickness of 10 mm. The first postmortem frozen anatomical sections were obtained at the level of the longitudinal plane, passed 10 mm parallel and laterally to the median plane in the left and right directions, and the last - at 40 mm. The findings observed in one native section were compared with those of three consecutive computed tomography scans.

Axial CT anatomical study

We studied 12 mature (6 male, 6 female) clinically healthy New Zealand rabbits which weight to 2.8 to 3.2 kilogram. An axial computed tomography Picker Marconi-USA, 1995, has been used. The table height was 395 mm, the field of view (FOV) - 180, filter - 1, anode force 125 mA, anode voltage

100 kV and time of scanning - 1.2 sec. The resolution was high - 512 and gentry (GT) -0 °. The window (W) was 399 and the center - 53. The experimental animals were positioned in a ventrodorsal position. Computed tomography sagittal investigation of the abdominal cavity was from 8 intercostal space to L7 at a slice thickness of 5 mm. The scan slices were consecutively chosen. The results were interpreted following the terms of NAV 2017 (17). CT parameters measured on sagittal sections were dorsoventral size (DV - the distance between the dorsal and ventral border of the liver) and craniocaudal size (CC - the distance between the most prominent part of *facies diaphragmatica* and the caudal contour of the liver border) (10, 18).

Statistical methods

The obtained values were measured in mm to the second decimal place. Data were statistically processed by Statistica 8 (19). Descriptive statistical analysis was applied at P = 95%.

RESULTS

The results from the postmortem anatomical study on sagittal sections obtained at the level of the sagittal plane, passed 10 mm parallel to the median and to the left, showed the intrathoracic anatomical location of the liver in the domestic rabbit. *Lobus hepatis sinister medialis* was cranially to *lobus hepatis sinister lateralis* and covered it on *facies diaphragmatica*. *Proc. papillaris* was observed as an oval structure, caudodorsal to the left lobes. The ventral margin of the organ touched the soft abdominal wall. The spleen, left kidney, segments of the small and large intestines were found caudally from the organ, and at this level they did not have direct anatomical contact with the liver (Figure 1).

On the sagittal *postmortem* anatomical study on frozen sections obtained at the level of the longitudinal plane passed 20 mm laterally from the median plane and on the left, the anatomical

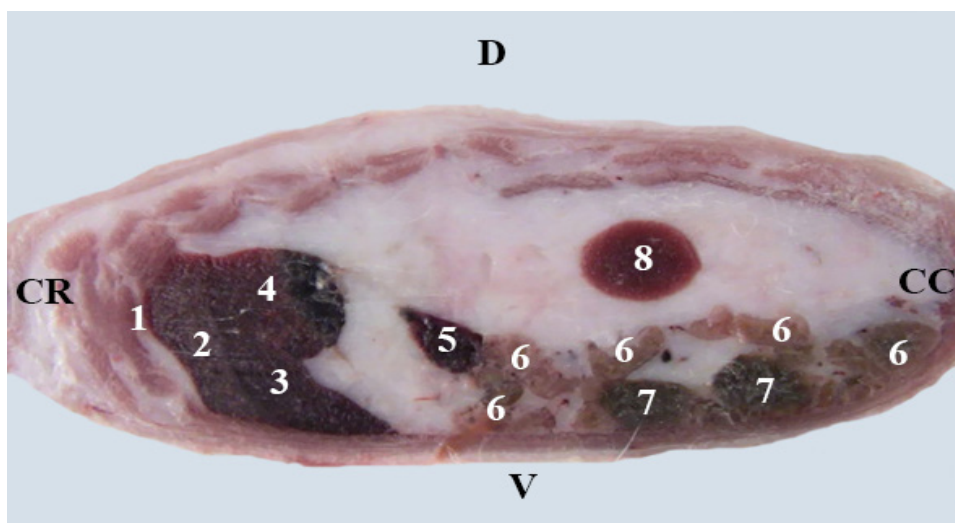


Figure 1. Sagittal postmortem anatomical section of cavum abdominis in a rabbit, at the level of the longitudinal plane passed 10 mm parallel to the median plane and to the left (D-dorsal; V-ventral). (1) diaphragm, (2) lobus hepatis sinister medialis; (3) lobus hepatis sinister lateralis; (4) proc. papillaris; (5) lien; (6) jejunum; (7) caecum, (8) ren sinister.

borders of the liver in the domestic rabbit with the adjacent abdominal organs from the left half of the abdominal cavity were outlined. *Lobus hepatis sinister lateralis* was located caudally from the diaphragm and it covered *lobus hepatis sinister lateralis* at *facies diaphragmatica*. The lateral left lobe touched caudally to *fundus et corpus ventriculi*, and *proc. papillaris* was located caudally to the most dorsal parts of the stomach (Figure 2).

The postmortem anatomical study on sagittal sections from *regio abdominis* obtained at the level of the longitudinal plane passed 10 mm parallel and to the right of the median plane showed that *lobus hepatis dexter* was cranially located relative to the remaining parts of the liver. The bottom and body of the stomach remained located between *lobus hepatis dexter* and *lobus caudatus*. *Lobus hepatis dexter* touched the parietal surface of the stomach. *Proc. caudatus* was found caudally relative to *fundus ventriculi* and dorsally from *pars cranialis duodeni* and segments of *colon ascendens*. Caudally, it touched the right kidney. *Proc. papillaris* covered the dorsal parts of the stomach and touched dorsally the muscles of the spine (Figure 3).

On the sagittal *postmortem* anatomical study on frozen sections obtained at the level of the longitudinal plane passed 20 mm parallel and to the right of the median plane, it was found that *lobus hepatis dexter* was observed as a well-defined anatomical structure cranially located relative to the other sections. *Lobus hepatis sinister medialis* was partially covered by *lobus quadratus*. The latter was found medially to the gallbladder as a poorly defined anatomical structure. *Vesica fellea* was round in shape and did not reach the ventral edge of the liver. *Corpus ventriculi* was topographed caudally to *lobus hepatis sinister medialis*. *Lobus caudatus* was in direct contact with the muscles of the spine, as the longitudinal section of *v. cava caudalis* was found just below the muscles of the spine and on the visceral surface of the dorsal right segments of the liver (Figure 4).

The results of the sagittal anatomical CT examination of *regio abdominis*, at the level of the longitudinal plane, passing 10 mm parallel and to the right of the median plane, demonstrated the peculiarities of the localization of the liver in *regio abdominis cranialis* and its adjacent soft tissue structures defining their shade according to the gray-white scale. *Lobus hepatis dexter*

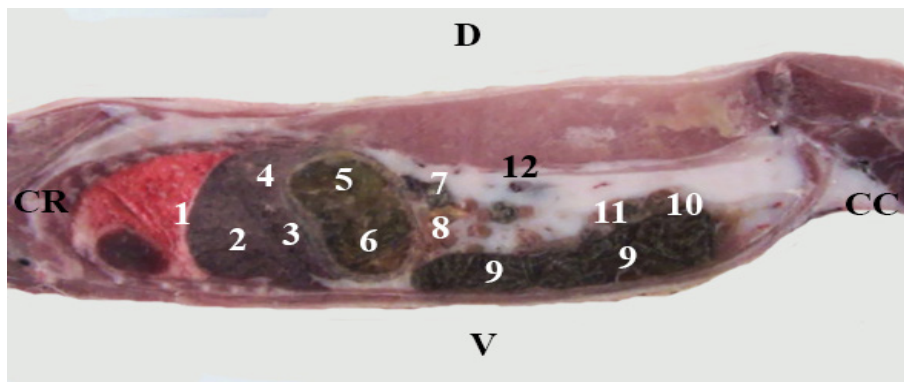


Figure 2. Sagittal postmortem anatomical section of the cavum abdominis at the level of the longitudinal plane passed 20 mm parallel and to the left of the median plane (D-dorsal; V-ventral). (1) diaphragm; (2) lobus hepatis sinister medialis; (3) lobus hepatis sinister lateralis; (4) proc. papillaris; (5) fundus ventriculi; (6) corpus ventriculi; (7) lien; (8) jejunum; (9) caecum; (10) duodenum; (11) ascending colon; (12) ren sinister.

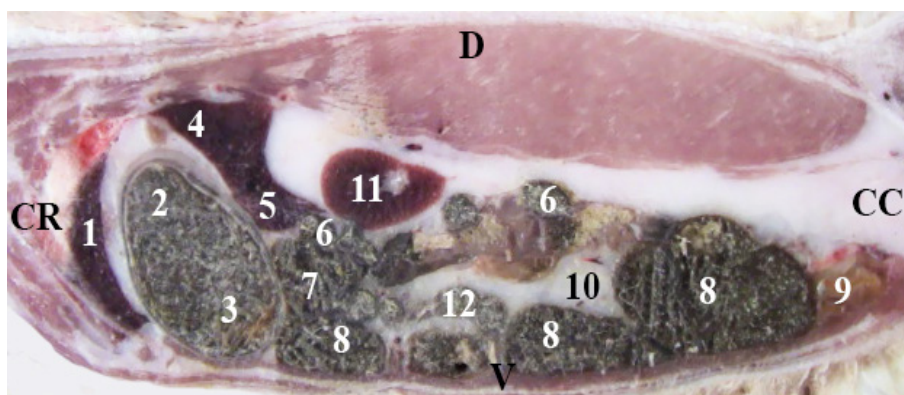


Figure 3. Sagittal postmortem anatomical section of cavum abdominis at the level of the longitudinal plane passed 10 mm parallel and to the right of the median plane (D-dorsal; V-ventral). (1) lobus hepatis dexter; (2) fundus ventriculi; (3) corpus ventriculi; (4) proc. papillaris; (5) proc. caudatus; (6) pars cranialis duodeni; (7) haustral part of colon ascendens; (8) caecum; (9) urinary bladder; (10) adipose tissue; (11) ren dexter; (12) ileum.

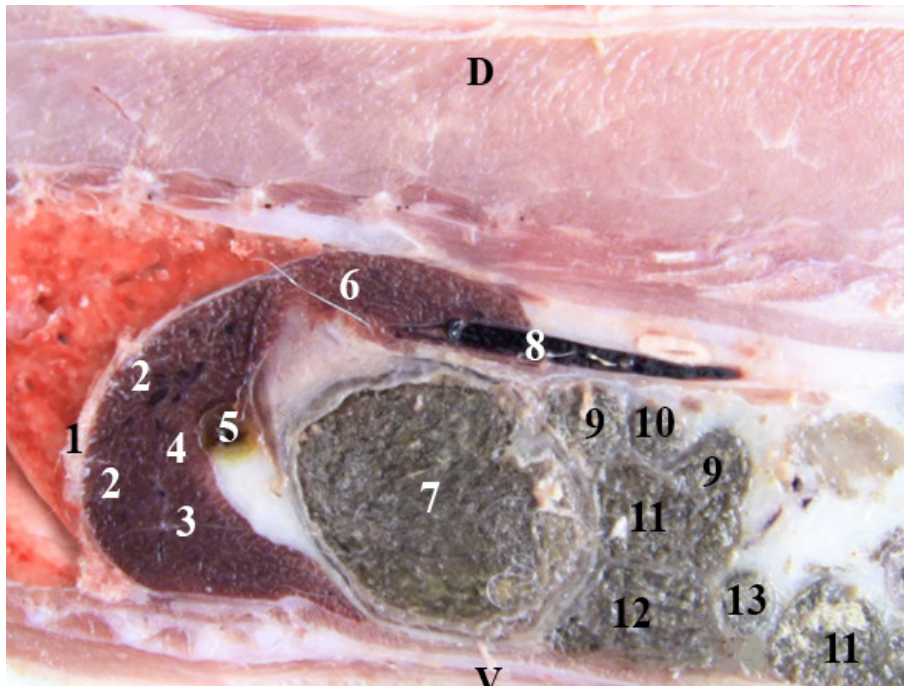


Figure 4. Sagittal postmortem anatomical section of cavum abdominis at the level of the longitudinal plane passed 20 mm parallel and to the right of the median plane (D-dorsal; V-ventral). (1) diaphragm; (2) lobus hepatis dexter; (3) lobus hepatis sinister medialis; (4) lobus quadratus; (5) vesica fellea; (6) lobus caudatus; (7) corpus ventriculi; (8) v. cava caudalis; (9) duodenum; (10) ileum; (11) caecum; (12) ascending colon; (13) jejunum.

was located cranially relative to the rest of the liver and was visualized as a single clearly defined norm attenuated structure, sharply distinguishable from *lobus hepatis sinister medialis* and *lobus caudatus*. There was no clear line between the *lobus hepatis sinister medialis* and *lobus hepatis dexter*. The hypo attenuated intraperitoneally distinct soft tissue image of *fundus ventriculi* was found between *lobus hepatis dexter* and *lobus caudatus*, with the relatively hyper dense liver borders defining its topography. *Proc caudatus* showed intermediate density relative to the surrounding soft tissue findings and was found caudodorsally to *fundus ventriculi* and dorsally from *pars cranialis duodeni* and the segments of *caecum*. At this sagittal scan level, CT anatomical

contact between *proc. caudatus* and right kidney were visualized. The norm dense anatomical image of *proc. papillaris* covered the dorsal hypo dense parts of the stomach and was opposite to *proc. caudatus* (Figure 5).

On the sagittal anatomical CT study of *regio abdominis* at the level of the longitudinal plane passed 20 mm parallel and to the right of the median plane, *lobus hepatis dexter* was observed as a clearly defined CT norm attenuated anatomical structure caudally situated to the relative hypo dense diaphragm. *Lobus hepatis dexter* covered *lobus hepatis sinister medialis* at *facies diaphragmatica*. A soft tissue anatomical marker for their

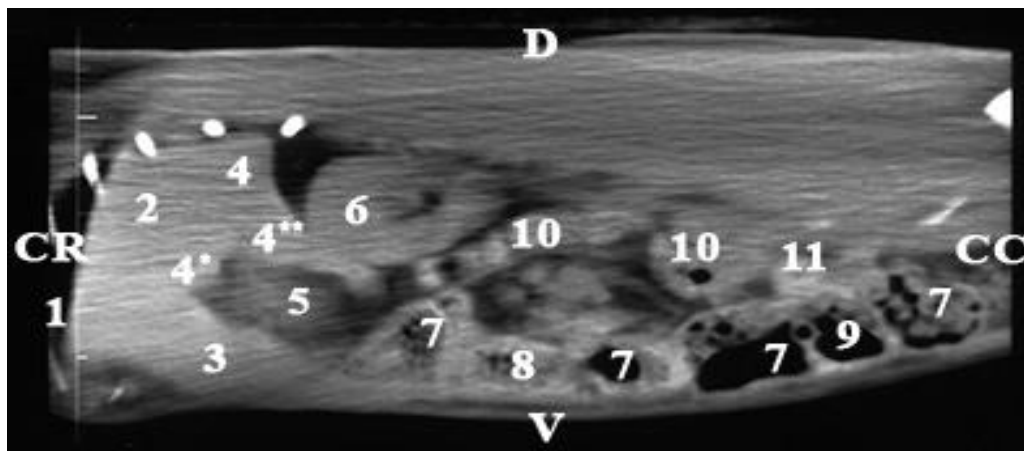


Figure 5. Sagittal anatomical CT section of cavum abdominis at the level of the longitudinal plane passed 10 mm parallel and to the right of the median plane. CR - cranial, CC - caudal, D - dorsal, V - ventral. (1) diaphragm; (2) lobus hepatis dexter; (3) lobus hepatis sinister medialis; (4) lobus caudatus; (4 *) *proc. papillaris*; (4 **) *proc. caudatus*; (5) *fundus ventriculi* with peritoneum; (6) *ren dexter*; (7) *caecum*; (8) *ileum*; (9) *ascending colon*; (10) *duodenum*; (11) *jejunum*.

distinction was a longitudinal hypo dense linear band. The norm attenuated CT image of *lobus caudatus* partially overlapped with that of *lobus hepatis dexter* and was found caudally as a single structure, without the presence of separation. *Lobus caudatus* was located dorsally relative to the rest of the liver and showed close density to that of the muscles around the spine. The cranial pole of the relatively hypo dense right kidney partially touched and overlapped the norm attenuated *lobus caudatus*, and *pars cranialis duodeni* and segments of the caecum were observed caudally from the visceral surface of *lobus hepatis sinister medialis*. A soft tissue marker for defining their CT anatomical images was the relatively hyper dense outlines of the liver margins (Figure 6).

On sagittal CT anatomical study of *regio abdominis*, at the level of the longitudinal plane passed 30 mm parallel and to the right of the median plane, it was found that *lobus hepatis dexter* was located cranially to *lobus hepatis sinister medialis*. Dorsally to the left and right lobes of the liver was the norm dense anatomical image of *lobus caudatus*. The soft-tissue peripheral

outlines of *proc. caudatus* were hyper attenuated compared to the norm dense right kidney. Ventrocaudally to the ventral border of *lobus hepatis dexter* were visualized the left parts of the stomach (*fundus et corpus ventriculi*), which in accordance to the gray-white scale showed intermediate density close to that of the liver (Figure 7).

On sagittal CT anatomical study of *regio abdominis* at the level of the longitudinal plane passed 10 mm parallel and to the left of the median plane, *lobus hepatis sinister medialis* was visualized as a clearly defined CT norm attenuated soft tissue anatomical finding. *Lobus hepatis sinister medialis* covered *lobus hepatis sinister lateralis* on *facies diaphragmatica*. The norm attenuated CT image of *proc. papillaris* and *lobus caudatus* were found dorsally from the left lobes of the liver. *Proc. papillaris* showed intermediate density to the surrounding soft tissue findings and was found caudorsally to *fundus ventriculi*. The relatively hyper dense outlines of the liver borders and the hypo dense mesentery were used as a soft tissue marker to define the CT anatomical image of the liver. (Figure 8). In the sagittal anatomical CT

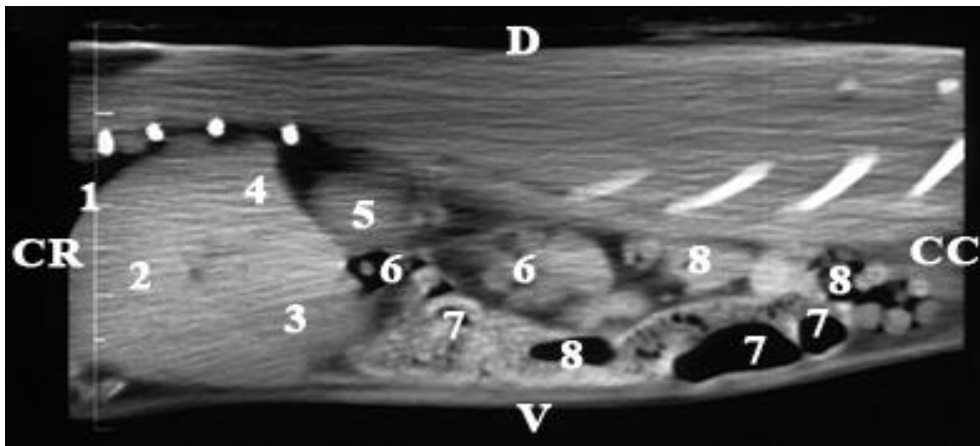


Figure 6. Sagittal anatomical CT section of the cavum abdominis at the level of the longitudinal plane passed 20 mm parallel and to the right of the median plane. CR - cranial, CC - caudal, D - dorsal, V - ventral. (1) diaphragm; (2) lobus hepatis dexter; (3) lobus hepatis sinister medialis; (4) lobus caudatus; (5) ren dexter; (6) duodenum; (7) caecum; (8) jejunum.

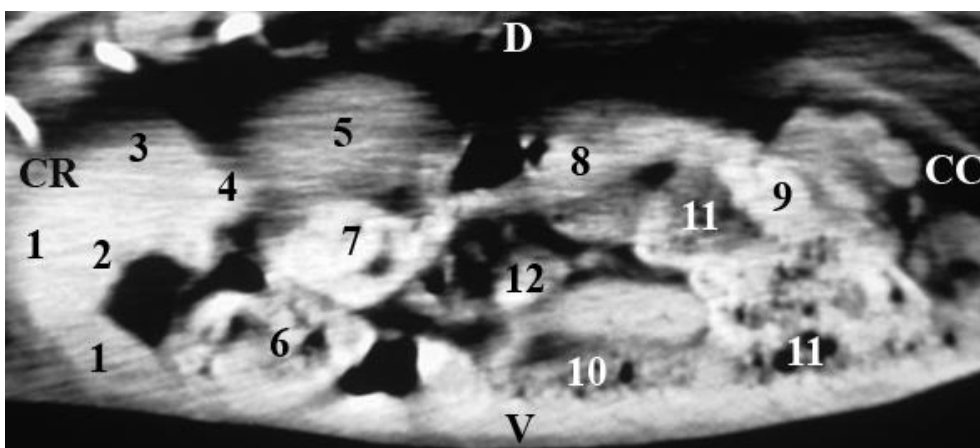


Figure 7. Sagittal anatomical CT section of cavum abdominis at the level of the longitudinal plane passed 30 mm parallel and to the right of the median plane. CR - cranial, CC - caudal, D - dorsal, V - ventral. (1) lobus hepatis dexter; (2) lobus hepatis sinister medialis; (3) lobus caudatus; (4) proc. caudatus; (5) ren dexter; (6) corpus ventriculi and pars pylorica; (7) pars cranialis duodeni; (8) pars descendens duodeni; (9) pars transversa duodeni; (10) ascending colon; (11) caecum; (12) jejunum

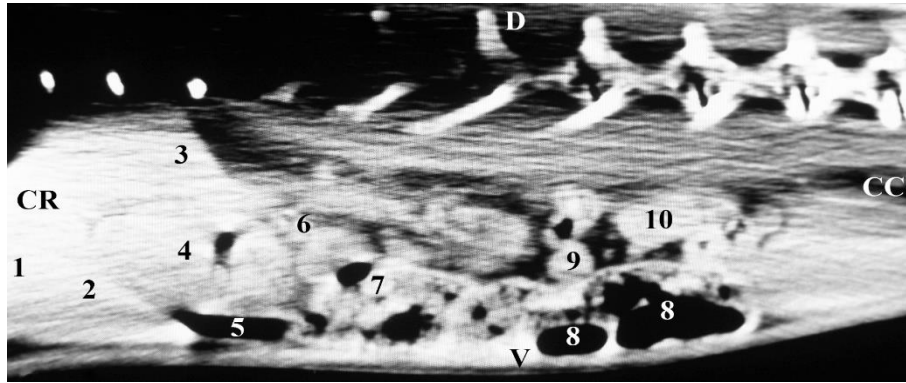


Figure 8. Sagittal anatomical CT section of cavum abdominis at the level of the longitudinal plane passed 10 mm parallel and to the left of the median plane. CR - cranial, CC - caudal, D - dorsal, V - ventral. (1) lobus hepatis sinister medialis; (2) lobus hepatis sinister lateralis; (3) lobus caudatus (proc. papillaris); (4) fundus et corpus ventriculi; (5) mesentery; (6) lien; (7) ansae jejunaes; (8) caecum; (9) colon ascendens (non-haustral part); (10) duodenum

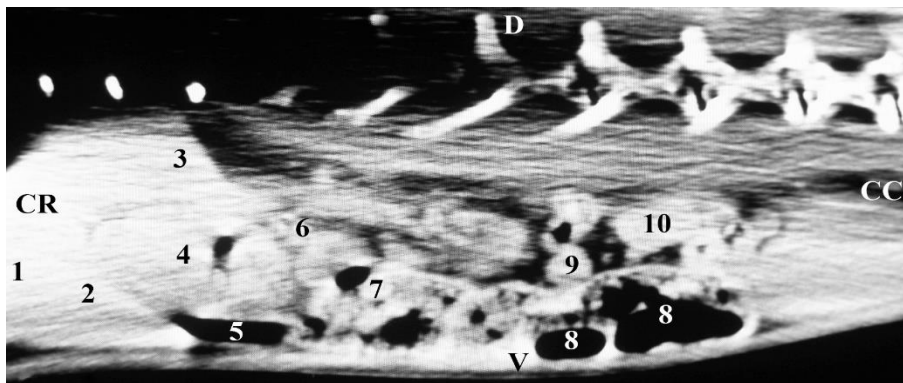


Figure 9. Sagittal anatomical CT section of cavum abdominis at the level of the longitudinal plane passed 20 mm parallel and to the left of the median plane. CR - cranial, CC - caudal, D - dorsal, V - ventral. (1) lobus hepatis sinister medialis; (2) lobus hepatis sinister lateralis; (3) lobus caudatus (proc. papillaris); (4) fundus et corpus ventriculi; (5) lobus caudatus; (6) ren sinister; (7) colon ascendens (haustral part); (8) caecum; (9) jejunum; (10) colon ascendens (non-haustral part); (11) duodenum.

study of *regio abdominis*, at the level of the longitudinal plane passed 20 mm parallel and to the left of the median plane, the CT anatomical boundaries of the liver toward the adjacent abdominal organs of the left abdominal half were defined. The norm dense anatomical image of *lobus hepatis sinister medialis* covered *lobus hepatis sinister lateralis* on *facies diaphragmatica*. *Lobus caudatus* was found dorsally to the left lobes of the liver, as *proc. papillaris* touched *fundus et corpus ventriculi* and was visualized as a relatively hyper dense structure relative to the hypo dense borders of the stomach. The relatively hyper dense outlines of the liver's borders and the hypo dense mesentery were used as a soft tissue marker to define the computed tomographic anatomical image of the liver at this level (Figure 9).

On sagittal anatomical CT study of *regio abdominis*, at the level of the longitudinal plane passed 30 mm in parallel and to the left of the median plane, the whole anatomical image of *lobus hepatis sinister medialis* was visualized. The left medial part of the liver was cranially to *lobus hepatis sinister lateralis*, partially covering it. *Lobus hepatis sinister lateralis* and *lobus caudatus* touched the left parts of the stomach (*fundus et corpus ventriculi*) (Figure 10).

The average computed tomography metric values of the rabbit liver, measured in the field of visualization of the organ

on sagittal sections, were presented graphically. The results presented the average values of the test metrics. The diagram was confirmative (Figure 11).

DISCUSSION

The imaging anatomical data present in detail the anatomical position of the examined organ in different sagittal planes. In addition, we interpret the lobes of the organ according to the variations on the gray-white scale, but at the same time we find the topography and the adjacency of the organ with other abdominal organs (diaphragm, *fundus et corpus ventriculi*, *pars pylorica*, *duodenum*, *ren dexter* and segments of the caecum). These facts give us reason to propose axial CT as an appropriate anatomical method for the visualization of the liver in domestic rabbits, similar to the findings of some authors for the applicability of CT (6).

We apply a sagittal CT scan of the liver in the domestic rabbit. This approach is suitable to obtain objective anatomical data concerning the topography of the organ. Our algorithm differs to that of the transverse CT study to investigate the topography of the abdominal organs in small mammals (7)

The sagittal CT study is a sufficiently comprehensive

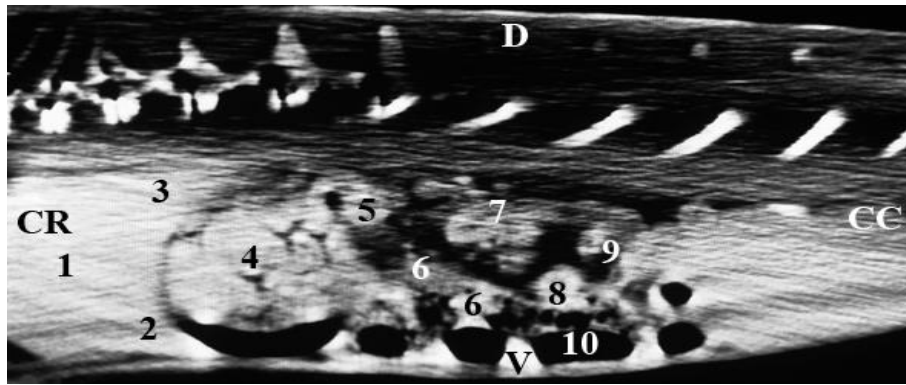


Figure 10. Sagittal anatomical CT scan of cavum abdominis at the level of the longitudinal plane passed 30 mm parallel and to the left of the median plane. CR - cranial, CC - caudal, D - dorsal, V - ventral. (1) lobus hepatis sinister medialis; (2) lobus hepatis sinister lateralis; (3) lobus caudatus (proc. papillaris); (4) fundus et corpus ventriculi; (5) lien; (6) jejunum; (7) ren sinister; (8) ascending colon; (9) duodenum; (10) caecum.

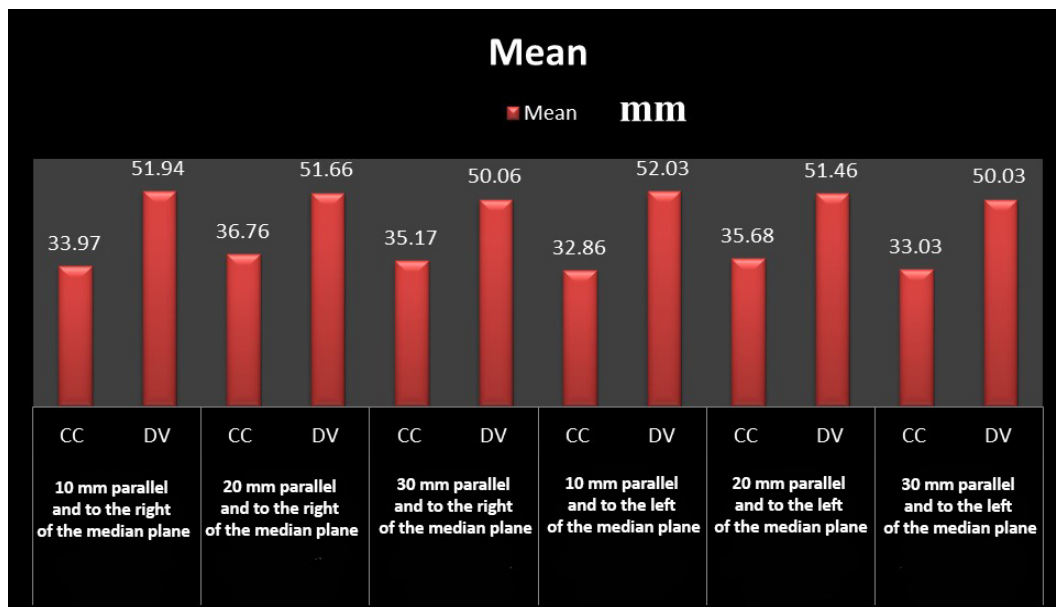


Figure 11. CT metric values (mm) of the liver in a rabbit, measured in the field of visualization of the organ on sagittal sections. (SS-cranio-caudal size; DV-dorso-ventral size)

method for investigation either the anatomical features of the liver (presence of five separate sections - *lobus hepatis dexter*, *lobus hepatis sinister medialis*, *lobus hepatis sinister lateralis*, *lobus caudatus*), adjacent to other abdominal organs, either to achieve reliable metric results (the cranial caudal and dorsal ventral size of the liver). Our thesis on the precision of the sagittal CT as an anatomical method complements the findings of some authors in humans (8).

Our imaging results provide information on the anatomical location of the liver in the rabbit in four sagittal planes (10 mm, 20 mm, 30 mm and 40 mm to the left and right to the median plane). In addition, these CT planes correspond to the applied anatomical planes in the *postmortem* examination. This thesis complements the theory of some authors about the accuracy of axial CT as an anatomical method (9, 10, 13).

Our data correspond to the opinion of Schapiro and Chiu (14) regarding the application and capabilities of axial CT for the anatomical visualization of soft tissue structures of

regio abdominis cranialis in humans. The interpretation of CT anatomical images of the liver in the rabbit, according to the gray-white scale, is related to the degree of X-ray absorption. We find the anatomical CT imaging of the liver.

CONCLUSION

We resume that the axial CT of the liver in the rabbit gives detailed data on the topography and anatomical features of the organ. We present information for *lobus hepatis dexter* (a single clearly defined norm attenuated find, sharply distinguishable from *lobus hepatis sinister medialis* and *lobus caudatus*). Our data demonstrated the anatomical contact between the liver and other organs (diaphragm, *fundus et corpus ventriculi*, *pars pylorica*, *duodenum*, *ren dexter* and segments of the caecum).

DECLARATIONS

Ethics Approval

This study was approved by animal ethics committee of the Trakai University (No: 51/2012, No:59/2013), Bulgaria.

Conflict of Interest

The authors declare that they have no competing interests.

Author Contribution

Idea, concept and design: K Stamatova-Yovcheva, R Dimitrov

Data collection and analysis: K Stamatova-Yovcheva, R Dimitrov, ÖG Dilek, D Yovchev

Drafting of the manuscript: K Stamatova-Yovcheva

Critical review: R Dimitrov, ÖG Dilek, D Yovchev

Data Availability

The data that support the findings of this study are available from the corresponding author upon reasonable request.

REFERENCES

1. Ozgel O, Karakurum, E, Demiraslan Y. Determination of the Effect of Stomach Volume on Topography of Liver of New Zealand Rabbit (*Oryctolagus Cuniculus* L.) AJAVS. 2015;1(2):33-41.

2. Halgür A, Karakurum E, Dilek, OG. Morphological aspects of the pancreas in the rat and the rabbit: an investigation into the location, ducts, arteries and veins. MAE Vet Fak Derg. 2018;3(2):96-101, 2018 DOI: 10.24880/maevfd.495969.

3. Dilek OG, Erden H. Age, Sex and Body Weight Related Echocardiographic Parameters of Clinically Healthy New Zealand White Rabbits. Acta Sci Vet. 2019;47(1652):1-8.

4. Dilek, OG, Erden H, Turan E, Dimitrov R, Stamatova-Yovcheva K, Karakurum, E. The qualitative and quantitative assessment of the renal cortex of the clinically healthy rabbits. Ankara Univ Vet Fak Derg. 2020;67(4):381-86.

5. Sevil Kilimci F. Rabbit liver lobes: an anatomical study of experimental surgical approaches. Erciyes Üniv Vet Fak Derg. 2020;17(2):103-08.

6. Cardoso L, Gil F, Ramírez G. Computed tomography (CT) of the lungs of the dog using a helical CT scanner, intravenous iodine contrast medium and different CT windows. Anat Histol Embryol. 2007;36:328-31.

7. De Rycke LM, Kromhout KJ, van Bree HJ, Bosmans T Gielen IM. Computed tomography atlas of the normal cranial Canine, abdominal vasculature enhanced by dual-phase, angiography. Anat Histol Embryol. 2013;43(6):413-22. doi: 10.1111/ahe.12090.

8. Van waes P, Michael A, Feldberg M, Goldberg HI, Herve P, Frans W et al. Direct coronal and direct sagittal CT of abdomen and pelvis: An approach to staging malignancies. RadioGraphics. 1986;6(2):213-44.

9. Gielen H, Van Bree H. Computed tomography (CT) in small animals. Part 2. Clinical applications. Vlaams Diergeneesk Tijdschr. 2003a;72:168-79.

10. Stamatova-Yovcheva K, The application of some imaging anatomical methods for investigation of the liver of the New Zealand white rabbit (*Oryctolagus cuniculus*). Dissertation. Stara Zagora, Bulgaria, (2016).

11. Stamatova-Yovcheva K, Dimitrov R, Yonkova P, Russenov A, Yovchev D, Kostov D. Comparative imaging anatomic study of domestic rabbit liver (*Oryctolagus cuniculus*). Trakia J Sci.2012a;10:57-63.

12. Stamatova-Yovcheva K, Dimitrov R, Toneva Y, Yonkova P, Kostov D, Rusenov A et al. Helical computed tomography application in rabbit liver anatomy: comparison with frozen cross-sectional cuts. Turk J Vet Anim Sci. 2013;37:553-58.

13. Dimitrov R, Yonkova P, Stamatova-Yovcheva K. Agreement between sagittal plane cross sectional anatomy, sonoanatomy and computed tomography of rabbit prostate and bulbourethral glands. Bulg J Vet Med. 2011;14(1):11-6.

14. Schapiro R, Chiu L, An Introduction to Abnormal Computed Tomographic Anatomy. I. The Epigastrium. J Comput Tomogr. 1977;1: 17-22.

15. Romans L. Introduction to computed tomography. Philadelphia: Williams & Wilkins; 1995. p. 5-16.

16. Seeram E. Single slice spiral/helical computed tomography: Physical principles and instrumentation. Chapter 11. In: Wilke J, Held L, editors. Computed tomography: Physical principles, clinical applications, and quality control. St. Louis: Saunders Elsevier; 2009. p. 246-266.

17. International Committee on Veterinary Gross Anatomical Nomenclature. Nomina Anatomica Veterinaria, Sixth Edition (revised version). Published by the Editorial Committee, Hanover (Germany), Ghent (Belgium), Columbia, MO (U.S.A.), Rio de Janeiro (Brazil). 2017.

18. Verma S, McClure K, Parker L, Mitchell D, Verma M.. Simple linear measurements of the normal liver: Interobserver agreement and correlation with hepatic volume on MRI. Clin Raiol. 2010;65(4):315-8. <http://jdc.jefferson.edu/radiologyfp/8>.

19. StatSoft®STATISTICA 7. Descriptive statistic. Dell Software, USA, 2013.