

CONFORMAL BREAST IRRADIATION IN THE PRONE POSITION IN TWO CASES

*Cengiz KURTMAN, *Fuat ÇİNER, *Meltem NALÇA ANDRIEU,
*Ayse HİÇSÖNMEZ, *Aysun ÇAĞAR

ABSTRACT

Introduction: Prone position can be used for the planning of adjuvant radiotherapy after breast conservative surgery. It is aimed to deliver less irradiation to lung tissue and cardiac tissue in the prone position.

Materials and Methods: Two cases of left breast carcinoma in stages T1, N0, M0 were taken for three-dimensional conformal radiotherapy planning after breast conservative surgery. The first case had moderate size of breast tissue. They were positioned with breast ring in the supine position and with foam which had a hole in order to allow the left breast tissue coming down in to prone position.

Results: Isodose distributions and dose volume histograms of the cases in the prone position were compared with the ones in the supine position. We have observed less irradiation given to the left lung tissue, cardiac tissue and right lung tissue in the prone position than in the supine position.

Discussion: Three-dimensional conformal radiotherapy planning was used to provide less normal tissue complication and high local control in both of the supine and prone position. Large breasted women appeared to benefit most from the planning in the prone position.

Key Words

Breast, conformal radiotherapy, prone position.

İKİ VAKADA PRONE POZİSYONDA KONFORMAL MEME İŞİNLAMASI

ÖZET

Giriş: Meme koruyucu cerrahi sonrası radyoterapi planlanması için prone pozisyon kullanılabilir. Amaç prone pozisyonu ile akciğer ve kalp dokularına daha az radyasyonun ulaşmasını sağlamaktır.

Gereç ve yöntem: Meme koruyucu cerrahi sonrası üç boyutlu konformal radyoterapi planlanması için T2N0M0 sol meme kansinomalı 2 vaka seçilmiştir. İlk vaka orta büyüklükteki meme dokusuna sahipti. Supine pozisyonda meme halkası ile pozisyon verilmiş ve prone pozisyonda sol meme dokusunun aşağı doğru sarkabileceği delikli köpük üzerine hastaya pozisyon verdirilmiştir.

Sonuçlar: Vakaların prone pozisyondaki izodoz dağılımları ve doz hacim histogramların supine pozisyondaki sonuçlar ile karşılaştırılmıştır. Prone pozisyonda supine pozisyonundaki ile karşılaştırıldığında sol akciğer dokusuna, kalp dokusuna ve sağ akciğer dokusuna daha az radyasyon verildiği gözlenmiştir.

Tartışma: Supine ve prone pozisyonunda her ikisinde de üç boyutlu konformal radyoterapi planlaması kullanılması normal doku komplikasyonları azaltmakta ve yüksek lokal kontrol sağlamaktadır. Prone pozisyonda yapılan tedavi planlamasından en fazla büyük memeli hastalar yarar sağlamaktadırlar.

Anahtar Kelimeler

Meme, konformal radyoterapi, prone pozisyon

Introduction

The management of primary breast cancer with conservative surgery and radiation therapy is a widely accepted alternative to mastectomy[1,2]. Standard tangential breast radiotherapy not only treats portions of chest wall, but also exposes to lung and heart tissue [3,4].

Radiation pneumonitis following conservative surgery and radiation therapy for breast cancer is a rare complication and it is related to treatment technique [5,6]. The prone position technique takes advantage of the reproducibility characteristics of the supine position technique and combines them with the homogeneity and normal tissue-sparing characteristics of lateral decubitus position technique. Prone position breast irradiation appears to be a simple and effective alternative to irradiation of the breast in the conventional supine position when the supine position is likely to result in unacceptable dose inhomogeneity or significant doses to normal tissue [7]. The technical aspect of prone position with three-dimensional conformal radiotherapy (3D-CRT) planning will be described.

Materials and Methods

The objectives of the prone position are the treated breast hangs down and minimize the volume of normal tissue. Two patients who have diagnosis of infiltrative ductal carcinoma in their left breast tissue subjected to conservative surgery as lumpectomy and referred to radiotherapy clinic. The stages of the cases were T1,N0,M0. First case had moderate size of breast tissue and second case had huge size of breast tissue. The cases were positioned with immobilization foam both in the supine position and in the prone position. The ipsilateral arm was placed above the head. The contralateral arm was placed on the immobilization foam. A breast ring applied and fixed on the left breast that held the breast upper position in the supine position. An hole was left under the left breast that allowed the breast came down during the treatment in the prone position.

The CT images were taken Picker® (Picker International, Inc, Cleveland, Ohio,

U.S.A.) I.Q. T/C computed tomography both in the supine position and in the prone position. The target volume, body out-line, left lung tissue, right lung tissue and cardiac tissue were drawn, target isocenter was fixed, and virtual simulation was done with Picker Voxel Q virtual simulation workstation. Beam's eye view, isodose distribution, inhomogeneity correction, multileaf collimators and dose volume histogram (DVH) were done with a Varian® Cad-plan (Varian Associates Inc, Oncology Systems, Palo Alto, CA, U.S.A.) treatment modelling workstation. The median and lateral borders of the breast tissue were determined both clinically and beam's eye view, must be included with in the fields of the tangential parallel-opposed photon beams. Three D-CRT planning was done for each position. Radiotherapy was given with planned with 6 mV photon of Varian® (Varian Associates Inc, Oncology Systems, Palo Alto, CA, U.S.A.). A total dose of 50 Gy with conventional daily fractions was applied. The wedges were used to enhance the isodose distribution and the treatment plans and DVH's were compared both in the supine position and in the prone position.

Results

The plans were performed with SAD technique and the isodose distributions were taken for the two cases both in the supine position and prone position. The isodose distributions were optimized with 15° wedge in the transverse plane. DVH analysis were performed for the target volume, left lung tissue volume, right lung tissue volume and cardiac tissue volume in each case and in each for both of the supine position and prone position.

In the first case; the target volume was in the 82.8 % isodose at the base of the breast tissue and in the 108.5 % isodose at the lateral edge of the breast tissue, the mean target dose was 99.99 % \pm 3.02 (50Gy) in the supine position, but the target volume was in the 77.8 % isodose at the base of the breast tissue and in the 193.5 % isodose at the lateral edge of the breast tissue, and the mean target dose was 97.65 % \pm 2.85 (48.82 Gy) in the prone position. In the second case; the target volume was in the 75 % isodose at the base of the breast tissue and in the 108.8 % isodose at the

lateral edge of the breast tissue, the mean target dose was $95.08 \% \pm 4.37$ (45.54 Gy) in the supine position, but the target volume was in the 67.10 % isodose at the base of the breast tissue and in the 109 % isodose at the lateral edge of the breast tissue, and the mean target dose was $99.03 \% \pm 5.23$ (49.52 Gy) in the prone position.

In the first case ; the mean left lung tissue dose was $15.23 \% \pm 29.88$ (7.62 Gy) in the supine position, and the mean left lung tissue dose was $6.49 \% \pm 16.51$ (3.24 Gy) in the prone position, the mean cardiac tissue dose was $11.18 \% \pm 18.89$ (55.59 Gy) in the supine position and the mean cardiac tissue dose was $9.77 \% \pm 17.33$ (4.88 Gy) in the prone position, and the mean right lung tissue dose was $1.61 \% \pm 1.29$ (0.80 Gy) in the supine position and the mean right lung tissue dose was $1.05 \% \pm 0.84$ (0.52 Gy) in the prone position.

In the second case; the mean left lung tissue dose was $11.61 \% \pm 22.66$ (5.81 Gy) in the supine position (Figure 1.), and the mean left tissue dose was $1.18 \% \pm 0.86$ (0.59 Gy) in the prone position (Figure 1.), the mean cardiac tissue dose was $12.64 \% \pm 19.51$ (6.32 Gy) in the supine position and the mean cardiac tissue dose was $3.52 \% \pm 2.83$ (1.76 Gy) in the prone position, and the mean right lung tissue dose was $1.20 \% \pm 0.62$ (0.60 Gy) in the supine position and the mean right lung tissue dose was $0.36 \% \pm 0.34$ (0.18 Gy) in the prone position.

Discussion

The management of primary breast cancer with conservative surgery and radiation therapy is a widely accepted alternative to mastectomy [1]. There is an increasing interest in the late side effect of therapy on the survival of patients treated for breast cancer [8-11]. The long- term complications following conservative surgery and radiation therapy for early stage breast cancer is low, and alterations in radiation technique may reduce their occurrence [12].

The risk of radiation pneumonitis appears to be related to the volume of lung irradiated [5,13,14]. The use of CT in tangential breast irradiation provides a detailed picture of the

dose distributions throughout the breast volume and surrounding normal tissue. The three-dimensional treatment planning allows dose escalation to the target volume without significantly increasing the dose received by surrounding normal tissue [15]. The full scale CT scan with a true three-dimensional dose algorithm is more accurate than the three-slice model [16].

Gyenes et al [17] reported that the CT-based three-dimensional treatment planning system might be conformed to reduce the irradiated cardiac volume. In this study the patients with left-sided T1,N0,M0 breast cancer did not receive irradiation to substantial cardiac volume.

Dose to the contralateral breast due to primary breast irradiation is possible as a function of the technique used for the primary of the treated breast. Several factors have been found to contribute significantly to the opposite breast dose and these can be improved by good techniques.

Gray et al [19] documented slight yet measurably inferior cosmetic results in large-breasted or heavy women. However, the difference between the large groups was not great and should not exclude these women from consideration for breast conservation techniques.

Cross et al [20] presented a technique for the conservative irradiation of women with huge size breasts. Patients were treated in a modified lateral decubitus technique offered breast-conserving therapy to women with large breasts, without poor cosmesis.

Merchants et al [7] reported that prone position breast irradiation appears to be a simple and effective alternative to irradiation of the breast in the conventional supine position when the supine position was likely to result in unacceptable isodose inhomogeneity or significant doses to normal tissues. Large breasted women appeared to benefit most from this treatment.

Bieri et al [21] determined the effects of treatment techniques, such as supine and prone positioning on the absorbed dose in organs at a distance from the irradiated breast. Peripheral

doses such as abdomen, pelvic organs, bone marrow and lung were significantly higher for supine than for prone tangential breast irradiation.

In conclusion, 3D-CRT planning was used to provide less normal tissue complication and high local control in the supine position and in the prone position. In the prone position, the

left breast tissue came down and the right breast tissue was pressed to lateral position. The left lung tissue, cardiac tissue and right lung tissue doses were less in the prone position than in the supine position. Large breasted women appeared to benefit from the planning in the prone position.

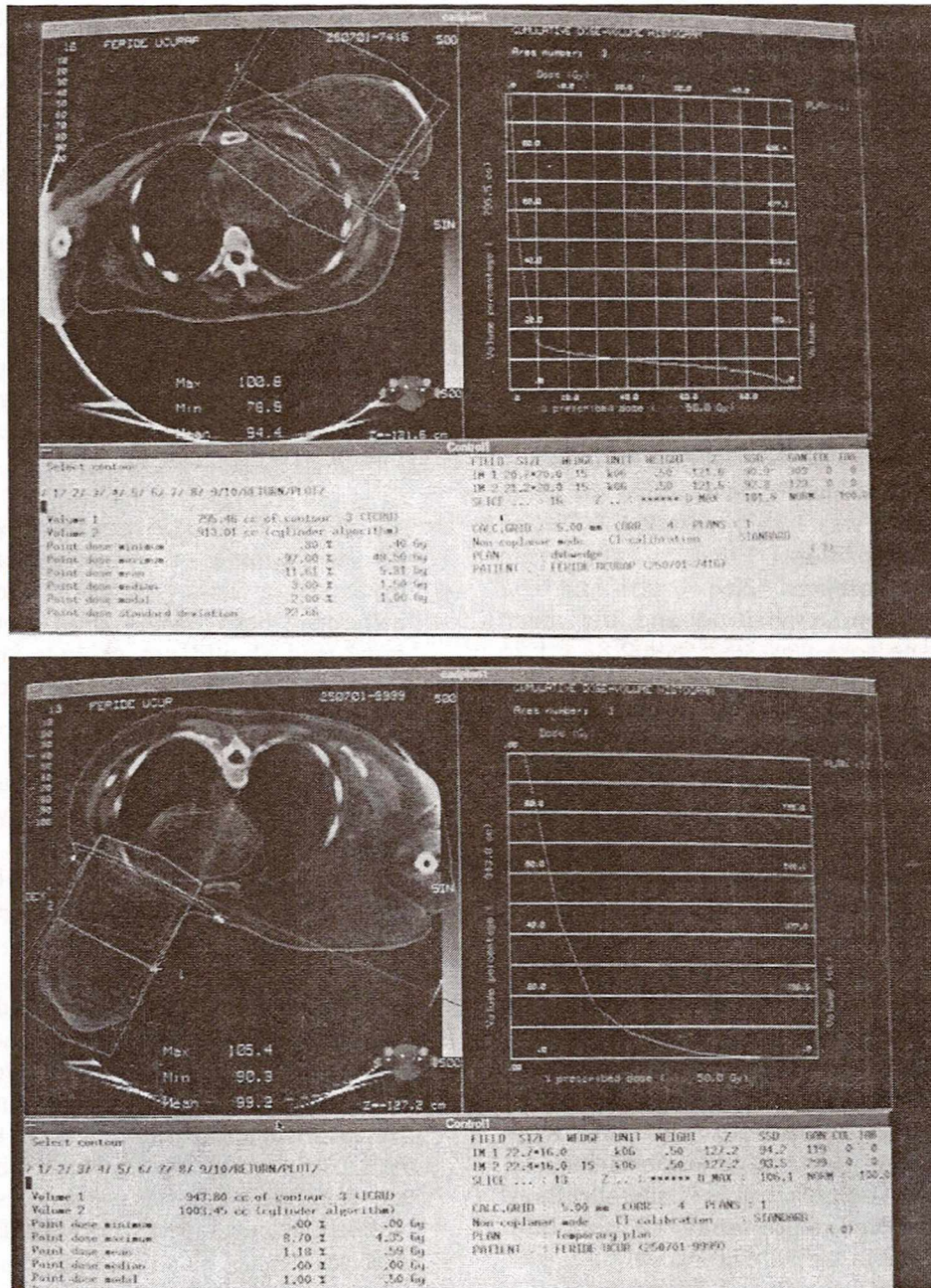


Figure 1. In the second case; the DVH and the isodose distribution of the target volume in the supine position and in the prone position.

REFERENCES

1. Fisher B, Bauer M, Margolese R, et al. I. Five-year results of a randomized clinical trial comparing total mastectomy and segmental mastectomy with or without radiation in the treatment of breast cancer. *New Eng J Med* 1985; 12: 665-673.
2. Vitucci C, Tirelli C, Graziano F, et al. Results of conservative surgery for limited sized infiltrating breast cancer: analysis of 962 tested patients: 24 years of experience. *J Surg Oncol*, 2000; 74: 108-115.
3. Cross P, Joseph DJ, Cant J, et al. Tangential breast irradiation: Simple improvements. *Int J Radiat Oncol Biol Phys* 1992; 23: 433-442.
4. Foo ML, McCullough EC, Foote RL, et al. Doses to radiation sensitive organs and structures located outside the radiotherapeutic target volume for four treatment situations. *Int J Radiat Oncol Biol Phys* 1993; 27: 403-417.
5. Lingos TI, Recht A, Vicini F, et al. Radiation pneumonitis in breast cancer patients treated with conservative surgery and radiation therapy. *Int J Radiat Oncol Biol Phys* 1991; 21: 355-360.
6. Gez E, Sulkes A, Isacson R, et al. Radiation pneumonitis: a complication resulting from combined radiation and chemotherapy for early breast cancer. *J Surg Oncol* 1985; 30: 116-119.
7. Merchant TE, McCormick B: Prone position breast irradiation. *Int J Radiat Oncol Biol Phys* 1994; 30: 197-203.
8. Haybittle JL, Brinkley D, Houghton J, et al. Postoperative radiotherapy and late mortality: Evidence from the cancer research campaign trial for early breast cancer. *Br Med J*, 1989; 298: 1611-1614.
9. Kelly CA, Wang X, Chu JCH, et al. Dose to contralateral breast: A comparison of four primary breast irradiation techniques. *Int J Radiat Oncol Biol Phys*, 1996; 34: 727-732.
10. Majeski J, Austin RM, Fitzgerald RH: Cutaneous angiosarcoma in an irradiated breast after conservation therapy for cancer: association with chronic lymphedema. *J Surg Oncol*, 2000; 74: 208-213.
11. Varsos G, Yahalom J: Lactation following conservation surgery and radiotherapy for breast cancer. *J Surg Oncol*, 1991; 46: 141-144.
12. Pierce SM, Recht A, Lingos TI, Abner A, et al. Long-term radiation complications following conservative surgery (CS) and radiation therapy (RT) in patients with early stage breast cancer. *Int J Radiat Oncol Biol Phys*, 1992; 23: 915-923.
13. Rotstein S, Lax I, Svane G: Influence of radiation therapy on the lung tissue in breast cancer patients: CT-assessed density changes and associated symptoms. *Int J Radiat Oncol Biol Phys*, 1990; 18: 173-180.
14. Groth S, Zaric A, Sorensen PB, et al. Regional lung function impairment following post-operative radiotherapy for breast cancer using direct or tangential field techniques. *Br J Radiol*, 1986; 59: 445-451.
15. Chin LM, Cheng CW, Siddon RL, et al. Three dimensional photon dose distributions with and without lung corrections for tangential breast intact treatments. *Int J Radiat Oncol Biol Phys*, 1989; 19: 1327-1335.
16. Cheng CW, Das IJ, Stea B, et al. The effect of the number of computed tomographic slices on dose distributions and evaluation of treatment planning systems for radiation therapy an intact breast. *Int J Radiat Oncol Biol Phys*, 1994; 30: 183-195.
17. Gyenes G, Gagliard G, Lax I, et al. Evaluation of irradiated hearth volumes treated with postoperative adjuvant radiotherapy. *J Clinic Oncol*, 1997; 15: 1348-1353.
18. Frass BA, Robenson PL, Lichter AS: Dose to the contralateral breast due to primary breast irradiation. *Int J Radiat Oncol Biol Phys*, 1985; 11: 485-497.
19. Gray JR, McCormick B, Cox L, et al. Primary breast irradiation in large-breasted or heavy women: Analysis of cosmetic outcome. *Int J Radiat Oncol Biol Phys*, 1991; 21: 347-354.
20. Cross MA, Elson HR, Aron BS: Breast conservation radiation therapy techniqu for women with large breasrs. *Int J Radiat Oncol Biol Phys*, 1989; 17: 199-203.
21. Bieri S, Russo M, Rouzaud M, et al. Influence of modifications in breast irradiation technique on dose outside the treatment volume. *Int J Radiat Oncol Biol Phys*, 1997; 38: 117-125.