

## RESEARCH

# Comparison of Apical Transportation and Canal Straightening Between Protaper Next, Hyflex, Reciproc and Reciproc Blue Instruments

Ali Türkyilmaz(0000-0003-0641-0062)<sup>α</sup>, Deniz Erdoğan(0000-0002-6471-8631)<sup>α</sup>

Gözde Akbal Dinçer(0000-0001-5188-334X)<sup>β</sup>, Ali Erdemir(0000-0003-1140-3887)<sup>α</sup>

*Selcuk Dent J*, 2022; 9: 402-408 (Doi: 10.15311/selcukdentj.887570)

Başvuru Tarihi: 27 Şubat 2021  
Yayına Kabul Tarihi: 14 Ekim 2021

### ABSTRACT

#### Comparison of The Effect of Different File Systems With Rotation and Reciprocating Motion on Apical Transportation and Canal Straightening

**Background:** This study aimed to compare apical transportation and canal straightening of ProTaper Next, HyFlex Electric Discharge Machining, Reciproc and Reciproc Blue nickel-titanium (NiTi) files with different apical enlargements.

**Methods:** Forty-eight mandibular molar human teeth were included in the study. The teeth were divided into four groups according to the NiTi file types (n=12). A digital radiographic method was used to compare apical transportation and canal straightening in the buccolingual and mesiodistal directions using before-and-after images superimposed with Image J software. The Kruskal-Wallis test with Bonferroni correction and the Wilcoxon test were used; the P value was set at 5%.

**Results:** The maximum transportation of the buccolingual and mesiodistal directions were 0.216 mm and 0.196 mm with Reciproc file. The maximum straightening of the buccolingual and mesiodistal directions were degrees of 8.661 and 8.048 respectively with ProTaper Next and Reciproc files.

**Conclusion:** ProTaper Next, HyFlex Electric Discharge Machining and Reciproc Blue files presented similar results. Using a larger instrument increased the apical transportation and canal straightening.

### KEYWORDS

Apical Transportation, Canal Straightening, Hyflex EDM, Reciproc Blue, Protaper Next

### ÖZ

#### Rotasyon ve Resiprokasyon Hareketi ile Çalışan Farklı Eğe Sisteminin Apikal Transportasyon ve Kanal Düzleşmesine Etkisinin Karşılaştırılması

**Amaç:** Bu çalışma, farklı apikal çaplara sahip ProTaper Next, HyFlex Electric Discharge Machining, Reciproc ve Reciproc Blue nikel-titanyum (NiTi) eğelerin apikal transportasyonu ve kanal düzleşmesini karşılaştırmayı amaçlamıştır.

**Gereç ve Yöntemler:** Kırk sekiz mandibular molar insan dişi çalışmaya dahil edildi. Dişler NiTi eğe tiplerine göre (n = 12) dört gruba ayrıldı. Image J yazılımı ile üst üste çakıştırılmış ilk ve son radyografik görüntüler kullanarak bukkolingual ve meziodistal yönlerde apikal transportasyonu ve kanal düzleşirmeyi karşılaştırmak için dijital radyografik yöntem kullanıldı. Analizlerde Bonferroni düzeltmeli Kruskal-Wallis testi ve Wilcoxon testi kullanıldı; P değeri %5 olarak belirlendi.

**Bulgular:** Hem apikal transportasyon hem de kanal düzeltme için eğeler arasında istatistiksel olarak önemli farklılıklar bulundu. Eğe çapının #40'a çıkarılması apikal transportasyon ve kanal düzleşmesini arttırdı (P < 0.05).

**Sonuç:** ProTaper Next, HyFlex Electric Discharge Machining ve Reciproc Blue eğeleri benzer sonuçlar verdi. Daha büyük bir enstrüman kullanmak apikal transportasyonu ve kanal düzleşmesini arttırdı.

### ANAHTAR KELİMELER

Apikal Transportasyon, Hyflex EDM, Kanal Düzleşmesi, Reciproc Blue, Protaper Next

## INTRODUCTION

Adequate cleaning and shaping of the root canal system during root canal preparation is indispensable for successful treatment.<sup>1</sup> It is essential to maintain the original shape of the root canal and not shift the position of the apical foramen.<sup>2</sup> Especially in curved root canals, it is more difficult to maintain the original shape of the root canal anatomy.

The amount of pulpal debris and infected dentin decrease when the apical preparation applied larger,<sup>3</sup> efficacy of the action of irrigations improves,<sup>4</sup> but the potential risks of apical transportation and canal straightening may increase. Increased apical

transportation can have a negative effect on the seal of root canal obturation.<sup>5</sup> and reduced curvature as a result of canal straightening may change the working length (WL). Various procedural errors, such as canal transportation, apical zipping, canal ledges, strip perforations and instrument separation, are likely to occur. The introduction of nickel-titanium (NiTi) systems into the field of endodontics has led to significant improvements in root canal shaping, and it has significantly reduced apical transportation.<sup>6</sup>

ProTaper Next (PTN) (Dentsply-Sirona, Ballaigues, Switzerland) has an innovative off-centre rectangular cross-section that provides a snake-like shape as it

<sup>α</sup> Department of Endodontics, Faculty of Dentistry, Kırıkkale University, Kırıkkale, Turkey

<sup>β</sup> Department of Endodontics, Faculty of Dentistry, Okan University, İstanbul, Turkey

moves through the root canal. The manufacturer claims that the rotation of this cross-section creates an enlarged space for the removal of debris. The file is made of M-Wire alloy, which improves its flexibility and resistance to cyclic fatigue while maintaining cutting efficiency.<sup>7,8</sup>

A recently developed technology, with controlled memory, has optimized the mechanical properties of NiTi alloy to make the files extremely flexible. Hyflex Electric Discharge Machining (HFEDM) (Coltene-Whaledent, Altstätten, Switzerland) is a new type of NiTi wire product. This file system is produced with a unique, complex heating and cooling process to control the material's memory.<sup>9</sup> The manufacturer claims that these files provide excellent flexibility that allows better preservation of the original canal curvature and increased adequacy and safety.<sup>10</sup>

Reciproc (RC) (VDW, Munich, Germany) a NiTi system with M-Wire technology, was developed due to the separation problem of NiTi instruments during clinical use. These files perform clockwise and counter-clockwise rotations to complete the root canal preparation with only one instrument, which simplifies the process. The reciprocating motion was reported to extend the lifespan of RC instruments in comparison to those that use constant rotation.<sup>11</sup>

Recently RC has recently been upgraded to Reciproc Blue (RCB) (VDW) using an innovative heat treatment that changes the molecular structure of the alloy and gives the instrument a blue colour. It has been reported that this heat treatment increases the flexibility and cyclic fatigue resistance of the instrument and shows less surface microhardness values than RC.<sup>12</sup>

Further apical enlargement may be needed for the apical third with chronic apical lesions to eliminate the infection. However, there is little data on how this enlargement affects apical transportation and canal straightening in comparison to previous apical enlargements with different kinematics. The aim of the present study was to compare the amount of apical transportation and canal straightening in the mesiobuccal canals of mandibular molars after instrumentation at #25 and #40 apical diameters in two different continuous rotation or reciprocating systems. The null hypothesis tested was that the instruments would provide similar apical transportation and canal straightening both in buccolingual and mesiodistal directions at #25 and #40 apical diameters.

## MATERIALS AND METHODS

### *Selection of the teeth*

An alpha-type error of 0.05 and a beta power of 0.80 were established and the minimal estimated sample size for each group was calculated to be 12 samples for each group. Forty-eight extracted first mandibular molars were collected under a protocol approved by the

local Ethics Committee of Kırıkkale University, Turkey (2019.11.24). Teeth with calcifications, internal or external root resorption, root cracks, severe curves or roots with multiple curves and a single canal with a mesial root were excluded. Teeth with 20–45° curvatures according to Schneider's method<sup>13</sup> and roots with a 3–7 mm radius of curvature were selected according to the method suggested by Estrela.<sup>14</sup> Based on the degree and the radius of the curvature, the teeth were assigned into four groups each consisting of 12 teeth. The homogeneity of the four groups according to the curvature angle and radius was assessed using analysis of variance (ANOVA) and the Student–Newman–Keuls post-hoc test.

Coronal access was achieved using diamond burs, and the mesiobuccal canal was located under a dental operating microscope (Carl Zeiss Meditac AG, Jena, Germany) and checked to determine if a #10 file (VDW, Munich, Germany) reached the apical region. After irrigating the root canals with 1% sodium hypochlorite, the WL was defined as 1 mm away from the point at which the file tip became visible at the major foramen under the dental operating microscope. The teeth were selected that has a 14±1 mm mesial root length from the cemento-enamel junction (CEJ) to apex (considering out-curvature surface) to standardized root length. The distal root was removed with a stainless-steel disc at the level of furcation. The mesial root of all the teeth was embedded in the putty impression material to mimic periodontium conditions.

Initial radiographs (before instrumentation) were taken with a #15 K-file (VDW). Each tooth was embedded in resin cubes, which had the same size and shape (25×25×25 mm), to provide a standard position for all the radiographs. A radiographic-sensor holding paralleling device (Cone Indicator, Indusbelo, Londrina, Brazil) was used to take the radiographs. The exposure parameters (0.08 s; 65 kV, 7 mA) were the same for all of the radiographs. Buccolingual and mesiodistal radiographs were obtained from all the samples to ensure the presence of two separate mesial canals.

### *Root Canal Instrumentation*

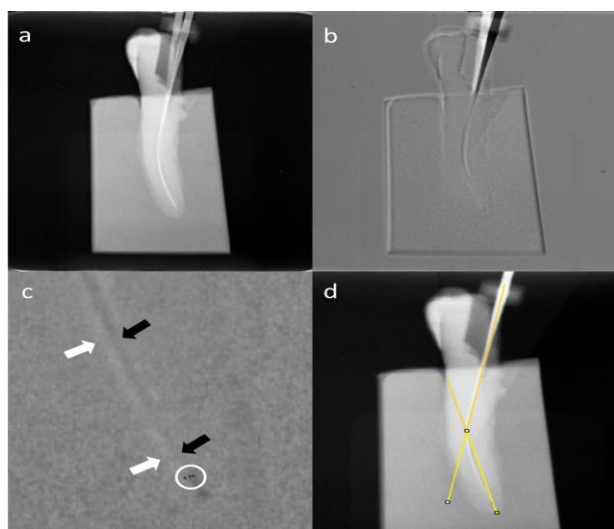
All the steps were performed by the same operator. PTN files were used at 300 rpm and at a torque of up to 2.0 Ncm, HFEDM files were used at 500 rpm and at a torque of up to 2.5 Ncm, RC and RCB files were used with the "Reciproc All" mode, using an 8:1 reduction handpiece powered by an X-Smart Plus (Dentsply-Sirona, Ballaigues, Switzerland) with an in-and-out motion and a crown-down technique. Each canal was prepared to meet the WL specification. Root canals were prepared to an apical size #25 and #40 with PTN (Group 1), HFEDM (Group 2), RC (Group 3) and RCB (Group 4). The instruments were replaced after three

canals were prepared. After each file in any group, the root canal was irrigated with 2 mL of a 2.5 % NaOCl solution; after instrumentation was completed, the root canal was irrigated with 5 mL of NaOCl using a plastic syringe with a 30-g open-ended needle (NaviTip; Ultradent, South Jordan, UT, USA). Then, the radiographs were first taken in the buccolingual and mesiodistal directions 15 with a #25 K-file inside the root canal; after further preparation, radiographs were taken with a #40 K-file.

**Evaluation of the Samples**

Adobe Photoshop (Adobe Systems, San Jose, CA, USA) was used to combine the radiographs. A toolbar was used with 50% transparency to superimpose each post-instrumentation image (with a #25 K-file and with a #40 K-file) separately onto its corresponding pre-instrumentation image (with a #15 K-file). ImageJ software (NIH, Bethesda, MD, USA) was used to measure apical transportation at a point 0.5 mm away from the WL.

The direct distance between the tips of two files (#15K/#25K or #15K/#40K) at 0.5 mm was measured on the superimposed images and recorded as apical transportation data. Similarly, the angle that occurred on the superimposed images of the two files was measured and recorded as the canal straightening data using ImageJ software (Figure 1).



**Figure 1.**

Superimposition of the initial and last radiographs taken with #15 and #40 K files (a). Negative image of superimposition (b). Magnification of apical third of negative image. Black arrows show #15 K-file and white arrows show #40 K-file. White circle shows measured distance between the files (c). Canal straightening measurement using the angle between intersecting lines (d).

Data were analyzed using SPSS 22.0 software (SPSS Inc., Chicago, IL, USA ). After applying normality tests to the apical transportation and root canal straightening data, the Kruskal- Wallis and

post-hoc Bonferroni tests were used to compare the differences between the groups and the Wilcoxon signed rank test was used to compare the differences between the file sizes. The level of significance was established at 5%.

**RESULTS**

Significant differences in homogeneity were not observed between the groups before instrumentation ( $p > 0.05$ ). Moreover, none of the samples were excluded due to instrument fracture and shaping error.

The inter-group comparisons of apical transportation and canal straightening based on the different apical sizes and directions are presented in Table 1. The apical transportation results based on apical diameter enlargement differences were statistically significant between file systems (#25 K-files and #40 K-files) in the buccolingual direction ( $p < 0.05$ ). HFEDM had the lowest apical transportation scores at the #25 and #40 apical file sizes. In the mesiodistal direction, no statistically significant difference was observed between the file systems when apical enlargement was completed at #25 ( $p > 0.05$ ); however, statistical difference between file systems was observed when the size of apical enlargement increased to #40 ( $p < 0.05$ ). Based on the canal straightening in the buccolingual direction, no statistically significant difference was observed between the file systems when apical enlargement was completed at #25 ( $p > 0.05$ ); however, canal straightening was affected by the type of file systems that was used, when the apical enlargement increased to #40 ( $p < 0.05$ ). In the mesiodistal direction, significant differences were observed in canal straightening for both apical sizes (#25 and #40) ( $p < 0.05$ ).

**Table 1.**

**Inter-group comparisons of apical transportation and canal straightening according to different apical size and direction**

File Type (Diameter/Taper)	Apical Transportation		Canal Straightening	
	Buccolingual	Mesiodistal	Buccolingual	Mesiodistal
	mean±SD	mean±SD	mean±SD	mean±SD
ProTaper Next (#25/.06)	0,119 ± 0,037a,b	0,146 ± 0,078a	5,920 ± 3,648a	2,365 ± 3,537a
Hyflex (#25/ ~)	0,076 ± 0,036a	0,096 ± 0,040a	3,551 ± 2,217a	2,359 ± 1,543a,b
Reciproc (#25/.08)	0,137 ± 0,067b	0,159 ± 0,069a	6,585 ± 3,423a	6,815 ± 4,947b
Reciproc Blue (#25/.08)	0,095 ± 0,057a,b	0,080 ± 0,062a	4,633 ± 4,283a	2,458 ± 2,067a,b
ProTaper Next (#40/.06)	0,134 ± 0,047a,b	0,170 ± 0,057a,b	8,661 ± 4,418a	3,384 ± 4,127a
Hyflex (#40/.04)	0,098 ± 0,038a	0,112 ± 0,035a	4,238 ± 1,862b	4,205 ± 1,926a,b
Reciproc (#40/.06)	0,215 ± 0,132b	0,196 ± 0,071b	8,314 ± 2,565a	8,048 ± 4,986b
Reciproc Blue (#40/.06)	0,118 ± 0,054a,b	0,124 ± 0,062a,b	6,339 ± 5,279a,b	3,465 ± 2,758a
P value	<.001	<.001	<.001	<.001

\*In each group the values followed by the same superscript letter do not differ ( $p < 0.05$ ). ~Hyflex - One file has a variable taper

In intra-group comparisons of apical transportation and canal straightening based on the different apical sizes and directions are shown in Table 2. When the #40 size was used, the amount of apical transportation and the degree of canal straightening increased in all the file systems in comparison with the #25 size in the buccolingual and mesiodistal directions ( $p < 0.05$ ). Only the comparison was

not statistically significant for PTN in the mesiodistal direction in the apical transportation. On the hand, the files showed similarly statistically differences in apical transportation and canal straightening with buccolingual and mesiodistal directions when comparing different apical size enlargements.

**Table 2.**

**Intra-group comparisons of apical transportation and canal straightening according to different apical size and direction**

Rotation	File Type	Size/Taper	Apical Transportation		Canal Straightening	
			Buccolingual	Mesiodistal	Buccolingual	Mesiodistal
			mean±SD	mean±SD	mean±SD	mean±SD
Rotary	ProTaper Next	#25/.06	0,119 ± 0,037a	0,146 ± 0,078a	5,920 ± 3,648a	2,365 ± 3,537a
		#40/.06	0,134 ± 0,047b	0,170 ± 0,057a	8,661 ± 4,418b	3,384 ± 4,127b
	Hyflex	#25/ ~	0,076 ± 0,036a	0,096 ± 0,040a	3,551 ± 2,217a	2,359 ± 1,543a
		#40/.04	0,098 ± 0,038b	0,112 ± 0,035b	4,238 ± 1,862b	4,205 ± 1,926b
Reciproc	Reciproc	#25/.08	0,137 ± 0,067a	0,159 ± 0,069a	6,585 ± 3,423a	6,815 ± 4,947a
		#40/.06	0,215 ± 0,132b	0,196 ± 0,071b	8,314 ± 2,565b	8,048 ± 4,986b
	Reciproc Blue	#25/.08	0,095 ± 0,057a	0,080 ± 0,062a	4,633 ± 4,283a	2,458 ± 2,067a
		#40/.06	0,118 ± 0,054b	0,124 ± 0,062b	6,339 ± 5,279b	3,465 ± 2,758b

\*In each group the values followed by the same superscript letter do not differ ( $p < 0.05$ ).

## DISCUSSION

The present study investigated apical transportation and canal straightening of four different Ni-Ti file systems at the apical part of curved canals using different apical enlargement. According to the results the null hypothesis was partially accepted because the files showed similar performance in apical transportation for mesiodistal direction and in canal straightening for buccolingual direction at #25 apical enlargement comparisons. When the results of apical transportation and canal straightening were analyzed at #40 apical enlargement, significant differences were observed between the file systems especially due to the flexibility property of the file. Increased flexibility decreased apical transportation and root canal straightening of root canal. Also the results of study revealed that use of a #40 size file after #25 size file generally resulted in more apical transportation and canal straightening. These findings can be attributed to preparation safety for curved canals.

In the last several decades, innovations in instrumentation systems were expected to lead to better root canal preparation with different kinematics, designs and geometry, such as the recently designed heat treatment NiTi alloys. These alloys have advantages when used for biomechanical preparation; they can help overcome anatomic challenges and severe curvatures.<sup>16</sup>

Optimization of the instrumentation size is an important factor when shaping root canals. Inadequate instrumentation cannot provide effective irrigation and disinfection of the root canal system, and it may adversely affect healing.<sup>17</sup> Some studies have reported that, to reduce the risk of infection, mechanical preparation is more efficient with large files than with small files.<sup>18,19</sup> One study recommended enlarging the apical third of the root canal up to a diameter of #40 in order to remove more debris and ensure better cleaning of this part of the tooth.<sup>18</sup> Moreover, the preparation needs to be enlarged to a diameter of #40 to provide a satisfying amount of irrigation contact with the debris remaining at the apical third.<sup>18</sup> However, over-instrumentation of the root canal system is challenging, and it can cause more irreversible shaping errors in root canals.<sup>20</sup>

Various methods, such as computed tomography and microcomputed tomography, can be used to evaluate the efficacy of endodontic instruments and root canal preparation techniques. Although these techniques provide very accurate information,<sup>21</sup> they are costly and time-consuming.<sup>22,23</sup> Digital radiography is another method that is used for this purpose. In this method, pre- and post-instrumentation radiographs are taken and overlapped to assess the degree of flattening of the canal and the amount of apical transportation in the buccolingual and mesiodistal directions. This method is easy to use and cost-effective<sup>24</sup> but it lacks the capacity to disclose volumetric information.<sup>25</sup> In the present study, this technique was used and the canals were evaluated in the buccolingual and mesiodistal directions to obtain more accurate information than two-dimensional conventional radiography.

For standardization of the study, the root portion of all the teeth was embedded in the putty impression material to simulate the gingiva in the resin blocks. Especially in curved canals, preserving the root canal anatomy while



simultaneously enlarging the root canal requires choosing the appropriate instruments, which can be challenging. Therefore, instrumentation systems with that different kinematics (continuous rotating and reciprocating motion), physical and metallurgical properties were selected in this study. The mesiobuccal canals of the mandibular molars were used because they are generally curved between 20-45°.26 Consequently, these teeth are suitable for evaluating the apical transportation of endodontic instruments.27

Iqbal et al. (2004)28 indicated that to measure the apical transportation at 0 mm (1 mm coronal to major foramen) is unfavorable because of the loss of the WL. In the present study, the apical transportation was determined at 0.5 mm (1.5 mm coronal to major foramen) similar to Duran-Sindreu et al. (2012)29 in order to obtain reliable measurements. Apical transportation may lead to shaping errors, such as zipping, canal ledges or perforations. These occur when the instruments exceed the critical level of instrumentation. This has a negative effect on root canal obturation, which reduces the sealing quality. Canal straightening can cause root strip perforation at the middle third or weakening of the coronal third by removing more of the cervical dentin tissue of the curved root canals. In canal straightening, the curvature angle and initial WL decrease and excessive root canal obturation can occur if the practitioner does not pay careful attention. Considering the aforementioned conditions, the flexibility of the instrument is essential in order to protect the root canal dynamics against iatrogenic events. The flexibility of hand and rotary files depends on various parameters, such as the metallurgical properties, cross-sectional design, core diameter and surface treatment of the instrument. To increase the flexibility of an instrument it is necessary to increase the number of spirals or flutes or the depth of the flutes and decrease the taper, size and/or core diameter.30

An innovative off-centered rectangular cross-section was integrated into PTN that gives the file a snake-like swaggering movement.31 It was manufactured from M-wire alloy that improved file resistance to cyclic fatigue and flexibility whilst retaining its cutting efficiency.32 Saber et al. (2015)31 reported that the use of PTN resulted in significantly greater canal straightening than HFEDM and iRace but no significant difference was found between the three files with respect to apical transportation. Its less flexibility against thermally treated files resulted in greater canal straightening. In a study that evaluated NiTi systems, PTN, RC, RCB and TRUShape did not result in different dimensional changes and canal transportation in the critical apical area.16 Another study evaluated apical transportation of maxillary molars with manual K-files, PTN and RC showed similar apical transportation results for all groups.33 The RCB instrument has the same metallic volume as the RC instrument, but it resulted in the smallest canal changes, which is similar to instruments that have a smaller taper, such as PTN.16 Venino et al.

al. (2017) evaluated the root canal transportation and centering ratio of PTN and HFEDM in the buccolingual and mesiodistal directions; they reported that the files used in the study were similarly effective.34 The results of our study are similar to those reported in the previously mentioned studies. Similar results were found between PTN, HFEDM and RCB. It is acceptable to ascribe these outcomes to the greater flexibility of these files. Although RCB has a thermal treatment that enhanced the cutting efficiency of the file, the difference in the taper and hence in the volume of the core structure, may influence its shaping ability. RC and RCB have a .08 taper in the apical 3 mm. The HFEDM One file (#25/.08) has a decreasing taper to the coronal, beginning at 4 mm from the tip. PTN has a .06 taper. The HFEDM One file has a variable taper on the cutting surface. However, RC does not have as much flexibility as other files that were used in our study. This can lead to greater values for the RC file, which could explain why we found a significant difference for this instrument

Several methods have been and are still preferred to compare changes before and after root canal shaping. In apical transportation and root canal straightening researches, the current method is micro-CT. However, it is still a costly method in serial usage. In the present study, the superimposition technique that is an alternative method to micro CT was preferred. The superimposition of digital radiographs can be considered as a limitation of this study against the effectiveness of micro-CT. Another limitation was the flexibility differences of files. When measuring superimposed radiographs, files #25 and #40 could not adapt to the canal curvature as close as #15 and this may have affected the measurement sensitivity for all samples.

## CONCLUSION

Within the limitation of the present study, the results showed that the use of RC file caused more apical transportation and degree of straightening than PTN, HFEDM and RCB files. Additionally, achieving a larger apical diameter (from #25 to #40) could present a higher risk of procedural errors related to apical transportation and root canal straightening, especially for less flexible files.

## ACKNOWLEDGEMENTS

The authors have no conflicts of interest related to this study.

## DISCLOSURE STATEMENT

No potential conflict of interest was reported by the authors

## REFERENCES

1. Kell, T., Azarpazhooh, A., Peters, O. A., El-Mowafy, O., Tompson, B., Basrani, B. Torsional profiles of new and used 20/. 06 GT series X and GT rotary endodontic instruments. *J Endod* 2009; 35: 1278-81.
2. Alrahabi, M., Comparative study of root-canal shaping with stainless steel and rotary NiTi files performed by preclinical dental students. *Technol Health Care* 2015; 23: 257-65.
3. Tan BT, Messer HH. The quality of apical canal preparation using hand and rotary instruments with specific criteria for enlargement based on initial apical file size. *J Endod* 2002; 28: 658-64.
4. Shuping GB, Ørstavik D, Sigurdsson A, Trope M. Reduction of intracanal bacteria using nickel-titanium rotary instrumentation and various medications. *J Endod* 2000; 26: 751-5.
5. Wu MK, Fan B, Wesselink PR. Leakage along apical root fillings in curved root canals: part I—effects of apical transportation on seal of root fillings. *J Endod* 2000; 26: 210-6
6. Paleker, F. and P.J. van der Vyver. Comparison of canal transportation and centering ability of K-files, ProGlider File, and G-Files: a micro-computed tomography study of curved root canals. *J Endod* 2016; 42: 1105-9.
7. Alapati, S.B., Brantley, W. A., Iijima, M., et al. Metallurgical characterization of a new nickel-titanium wire for rotary endodontic instruments. *J Endod* 2009; 35: 1589-93.
8. Zhou, H., Peng, B., Zheng, Y. F. An overview of the mechanical properties of nickel-titanium endodontic instruments. *Endod Topics* 2013; 29: 42-54.
9. Gutmann, J., Gao, Y. Alteration in the inherent metallic and surface properties of nickel-titanium root canal instruments to enhance performance, durability and safety: a focused review. *Int Endod J* 2012; 45: 113-28.
10. Zhao, D., Shen, Y., Peng, B., Haapasalo, M. Micro-computed tomography evaluation of the preparation of mesiobuccal root canals in maxillary first molars with Hyflex CM, Twisted Files, and K3 instruments. *J Endod*, 2013; 39: 385-8.
11. Plotino, G., Ahmed, H. M. A., Grande, N. M., Cohen, S., Bukiet, F. Current assessment of reciprocation in endodontic preparation: a comprehensive review—part II: properties and effectiveness. *J Endod* 2015; 41: 1939-50.
12. De-Deus, G., Silva, E. J. N. L., Vieira, V. T. L., et al. Blue thermomechanical treatment optimizes fatigue resistance and flexibility of the Reciproc files. *J Endod* 2017; 43(3); 462-6.
13. Schneider, S.W. A comparison of canal preparations in straight and curved root canals. *Oral Surg Oral Med Oral Pathol* 1971; 32: 271-5.
14. Estrela, C., Bueno, M. R., Sousa-Neto, M. D., Pécora, J. D. Method for determination of root curvature radius using cone-beam computed tomography images. *Braz Dent J* 2008; 19: 114-8.
15. de Oliveira, D.J.F., Leoni, G. B., da Silva Goulart, R., de Sousa-Neto, M. D., Sousa, Y. T. C. S., Silva, R. G. Changes in Geometry and Transportation of Root Canals with Severe Curvature Prepared by Different Heat-treated Nickel-titanium Instruments: A Micro-computed Tomographic Study. *J Endod* 2019; 45: 768-73.
16. Nair, P. N. R. On the causes of persistent apical periodontitis: a review. *Int Endod J* 2006; 39: 249-281.
17. Siqueira Jr, J.F., Lima, K. C., Magalhães, F. A., Lopes, H. P., de Uzeda, M. Mechanical reduction of the bacterial population in the root canal by three instrumentation techniques. *J Endod* 1999; 25: 332-5.
18. Card, S.J., Sigurdsson, A., Ørstavik, D., Trope, M. The effectiveness of increased apical enlargement in reducing intracanal bacteria. *J Endod* 2002; 28: 779-83.
19. Ram, Z. Effectiveness of root canal irrigation. *Oral Surg Oral Med Oral Pathol* 1977; 44 :306-12.
20. Schäfer, E., Dammaschke, T. Development and sequelae of canal transportation. *Endod Topics* 2006; 15: 75-90.
21. Swain, M.V., Xue, J. State of the art of Micro-CT applications in dental research. *Int J Oral Sci* 2009; 1: 177-88.
22. Anderson, P., Yong, R., Surman, T. L., Rajion, Z. A., Ranjitkar, S. Application of three-dimensional computed tomography in craniofacial clinical practice and research. *Aust Dental J* 2014; 59 (s1): 174-85.
23. Domark, J.D., Hatton, J. F., Benison, R. P., Hildebolt, C. F. An ex vivo comparison of digital radiography and cone-beam and micro computed tomography in the detection of the number of canals in the mesiobuccal roots of maxillary molars. *J Endod* 2013; 39: 901-5.
24. Celik, D., T. Tasdemir, K. Er. Comparative study of 6 rotary nickel-titanium systems and hand instrumentation for root canal preparation in severely curved root canals of extracted teeth. *J Endod* 2013; 39: 278-82.
25. Ounsi, H.F., Franciosi, G., Paragliola, R., et al. Comparison of two techniques for assessing the shaping efficacy of repeatedly used nickel-titanium rotary instruments. *J Endod* 2011; 37: 847-50.

26. Mohammadian, F., Sadeghi, A., Dibaji, F., Sadegh, M., Ghoncheh, Z., & Kharrazifard, M. J. (2017). Comparison of Apical Transportation with the Use of Rotary System and Reciprocating Handpiece with Precurved Hand Files: An In Vitro Study. *Iran Endod J*, 12(4), 462.
27. Vallaëys, K., Chevalier, V., Arbab-Chirani, R. Comparative analysis of canal transportation and centring ability of three Ni-Ti rotary endodontic systems: Protaper(R), MTwo(R) and Revo-S, assessed by micro-computed tomography. *Odontology* 2016; 104: 83-8.
28. Iqbal MK, Firic S, Tulcan J, Karabucak B, Kim S. Comparison of apical transportation between ProFile and ProTaper NiTi rotary instruments. *Int Endod J* 2004;37: 359–64.
29. Duran-Sindreu, F., García, M., Olivieri, J. G., Mercadé, M., Morelló, S., & Roig, M. (2012). A comparison of apical transportation between FlexMaster and Twisted Files rotary instruments. *J Endod*, 38(7), 993-995.
30. McSpadden, J.T. Mastering endodontic instrumentation. *Cloudland Institute* 2007; 51-52.
31. Saber, S. E. D. M., Nagy, M. M., & Schäfer, E. Comparative evaluation of the shaping ability of ProTaper Next, iRaC e and Hyflex CM rotary NiTi files in severely curved root canals. *Int Endod J* 2015; 48(2), 131-136.
32. Alapati SB, Brantley WA, Iijma M et al. Metallurgical characterization of a new nickel-titanium wire for rotary endodontic instruments. *J Endod* 2009; 35, 1589– 93.
33. Zanesco, C., Só, M. V. R., Schmidt, S., Fontanella, V. R. C., Grazziotin-Soares, R., Barletta, F. B. Apical Transportation, Centering Ratio, and Volume Increase after Manual, Rotary, and Reciprocating Instrumentation in Curved Root Canals: Analysis by Micro-computed Tomographic and Digital Subtraction Radiography. *J Endod* 2017; 43: 486-90.
34. Venino, P.M., Citterio, C. L., Pellegatta, A., Ciccarelli, M., Maddalone, M. A micro-computed tomography evaluation of the shaping ability of two nickel-titanium instruments, HyFlex EDM and ProTaper Next. *J Endod* 2017; 43: 628-32.

Corresponding Author:

Ali TÜRKYILMAZ

Department of Endodontics, Faculty of Dentistry,  
Kırıkkale University, Kırıkkale, Turkey

E-mail : turkyilmaz\_a@hotmail.com