

Kikuchi-Fujimoto Disease or Lymphoma?

Kikuchi-Fujimoto Hastalığı mı, Lenfoma mı?

Sema YILDIRIM¹, Ayse ASIK¹, Bengu Cobanoglu SIMSEK², Ayse Bozkurt TURHAN³

¹ Goztepe Prof. Dr. Suleyman Yalcin City Hospital, Department of Pediatric, Istanbul, Turkey

² Istanbul Medeniyet University, Goztepe Prof. Dr. Suleyman Yalcin City Hospital, Department of Pathology, Istanbul, Turkey

³ Goztepe Prof. Dr. Suleyman Yalcin City Hospital, Department of Pediatric Hematology and Oncology, Istanbul, Turkey

Özet

Kikuchi-Fujimoto hastalığı kendi kendini sınırlayan bir hastalık olup lenfadenitin oldukça nadir görülen sebeplerinden biridir. Başlıca semptomları lenfadenopati ve ateştir. Daha nadir olarak gece terlemesi, artralji, kilo kaybı ve cilt bulguları görülebilir. Bu yazıda üç haftadır mevcut olan servikal bölgede kitle, gece terlemesi, kilo kaybı ve yorgunluk şikayetleri olan 16 yaşında erkek hasta sunulmuştur. Yazının amacı, nedeni belirsiz ateş ve lenfadenopatinin ayırıcı tanısında lenfoma ve tüberküloz gibi hastalıkların yanı sıra nadir görülen ve genellikle iyi seyirli olan Kikuchi-Fujimoto hastalığının da akılda tutulmasını vurgulamaktır.

Anahtar kelimeler: Histiositik nekrotizan lenfadenit, Kikuchi-Fujimoto hastalığı, Lenfoma

Abstract

Kikuchi-Fujimoto disease is a rare, idiopathic and usually self-limiting disease caused by lymphadenitis. The main symptoms are lymphadenopathy and fever, and less frequent symptoms are night sweats, arthralgia, weight loss and rashes.

A case of a 16 years old boy is presented. His complaints were cervical mass presenting for about three weeks, night sweats, weight loss and fatigue. Our aim is that in the differential diagnosis of fever and lymphadenopathy of unknown origin, diseases such as lymphoma and tuberculosis, as well as rare and mostly very benign Kikuchi-Fujimoto disease should be remembered.

Keywords: Histiocytic necrotizing lymphadenitis, Kikuchi-Fujimoto disease, Lymphoma

Yazışma Adresi: Sema YILDIRIM, Göztepe Prof. Dr.Süleyman Yalçın Şehir Hastanesi, Pediatri AD, Eğitim Mah. Dr. Erkin Cad. 34722 Kadıköy, İstanbul, Türkiye

Telefon: +905054741303

Email: yldrsm@gmail.com

ORCID No (Sırasıyla): 0000-0001-7311-519X, 0000-0003-0973-8098, 0000-0003-2639-2017, 0000-0002-6671-0596

Geliş tarihi: 22.03.2021

Kabul tarihi: 15.07.2021

DOI: 10.17517/ksutfd.900042

INTRODUCTION

Kikuchi-Fujimoto disease (KFD), also called histiocytic necrotizing lymphadenitis, is a rare, benign and generally self-limiting disease caused by lymphadenitis. It was first described by Kikuchi and Fujimoto in Japan in 1972 (1,2). KFD's etiology is still unknown, however, viruses (especially Epstein-Barr virus) and autoimmune diseases (particularly systemic lupus erythematosus (SLE)) are being suspected (3). KFD is classically presented in young woman and among Asian population. Painful cervical lymphadenopathy, predominantly including posterior cervical lymph nodes, and fever are the characteristic features. It is important to recognize that it may mimic lymphoma, therefore it is misdiagnosed as lymphoma. Diagnosis is confirmed by histopathologic evaluation of affected lymph nodes. There is no specific therapy for KFD which usually resolves within a few months (4,5).

CASE PRESENTATION

A previously healthy 16 years old boy admitted to pediatric unit with a complaint of an enlarged nodule on the right side of the neck grown over a period of three weeks. He also complained of fever, fatigue, night sweats, and a weight loss of 3 kilograms in the last month. On physical examination, he had a tender right anterior cervical lymph node measured 3x2 cm without erythema, warmth, and fluctuation. His otolaryngologic examination evidenced no sign of infection. Also, no other remarkable findings such as hepatosplenomegaly, petechia or purpura were demonstrated on his physical examination. His physical development was within normal range. The patient had previously been evaluated by a primary care physician who trialed a course of oral antibiotics without any improvement or resolution of the neck mass.

In initial laboratory findings, the complete blood count and routine blood biochemistry were within normal limits. The test for serum C-reactive protein was negative, the sedimentation rate was mildly elevated (25mm/h). Serological tests for Cytomegalovirus (CMV), Epstein Barr Virus (EBV), Parvovirus, Rubella, HIV (human immune deficiency virus), Toxoplasma gondii, and Brucella were negative. The Monospot test

was also negative. The serum levels of rheumatoid factor (<1 IU/mL), C3 (143 mg/dL), C4 (35.8 mg/dL), anti-streptolysin O (111 IU/mL) and anti dsDNA (<10 IU/mL) were within normal limits. The serum titer of anti-nuclear antibody (ANA) was slightly elevated (1/160). The purified protein derivative (PPD) test was negative. The QuantiFERON test was negative. On peripheral smear investigation, polymorphonuclear leukocytes was seen as 46%, lymphocytes as 22%, monocytes as 22%, stab neutrophils as 10%, and the platelet count was adequate and erythrocyte morphologies were between normal range. Also, there were no atypical blood cells. The posteroanterior chest X-ray was normal. The neck ultrasound showed an enlarged, heterogeneous 36x16 mm single lymph node without fatty hilum and with increased vascularization, while there was no lymphadenopathy in the abdomen.

Initially, ampicillin sulbactam (150 mg/kg/day) was given for the treatment. On the fourth day of the treatment, ampicillin sulbactam was replaced by ceftriaxone (75 mg/kg/day) and clindamycin because his complaints such as fever and tender enlarged lymphadenopathy still continued. We did not observe any clinical improvement, although the treatment of combined intravenous antibiotic therapy with ceftriaxone and clindamycin. An excisional lymph node biopsy was performed for diagnosis because of the persistence of intermittent fever and lymphadenopathy.

Histologically, follicular hyperplasia was observed in the lymph node. The paracortex was enlarged and included areas of irregular, well-defined necrosis. Necrotic foci contain abundant karyorectic nuclear debris (**Figure 1**) and CD68+ histiocytes were seen around the necrosis (**Figure 2**). There were scattered lymphocytes, immunoblastic cells and plasma cells among the histiocytes. Proliferation and congestion were observed in the blood vessels. However, there was no granulomatosis and caseification necrosis. The histopathological diagnosis was evaluated as histiocytic necrotizing lymphadenitis and interpreted as Kikuchi Fujimoto disease. Antibiotherapy was discontinued and ibuprofen was prescribed after final diagnosis. Upon one week of treatment, there were no complaints. Fever was not observed again, and the enlarged lymph nodes began to regress. It has not recurred during the two years follow-up.

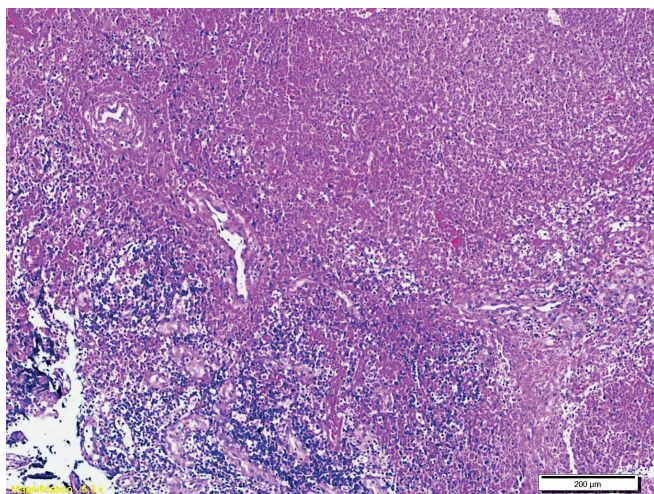


Figure 1. Necrotic foci contain abundant karyorectic nuclear debris and histiocytes were seen around the necrosis (HEx100)

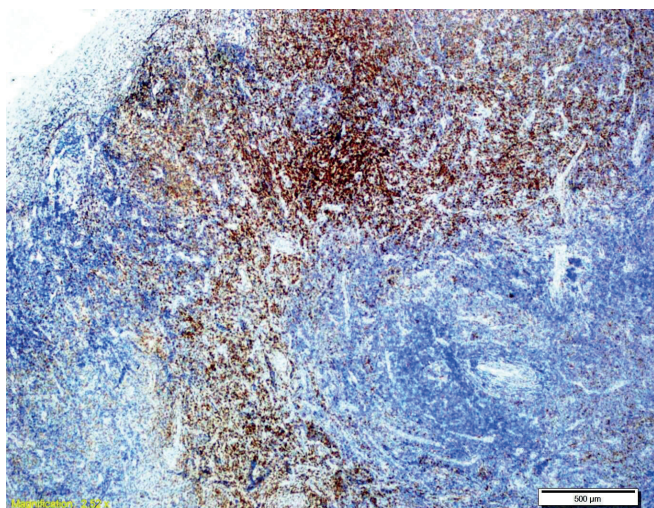


Figure 2. Extensive histiocytes proliferation (CD68x40)

DISCUSSION

KFD is an uncommon benign self-limiting condition related with histiocytic necrotizing lymphadenitis. It is endemic in Asia especially and it commonly occurs in young adults under 40 years and is rare in children (4). A recent study including 91 patients with KFD had reported the average age as 30 years. Although, in most literature it has been reported that it is mostly seen in females rather than males, Lin et al. has stated the equal prevalence between females and males in their study (3,6,7). KFD is characterized by tender lymphadenopathy and fever. The cervical lymph nodes are most commonly affected, however, axillary, supraclavicular, and other lymph nodes can also be affected. Generalized lymphadenopathy has been reported to be in 1–22% of the cases, and fever is present in 35–77% of the cases

(4). In addition, other symptoms such as weight loss, night sweats, nausea, and vomiting, fatigue, headache, arthralgia, upper respiratory symptoms, and sore throat could occur as rare symptoms (8). Prevalence of hepatomegaly and splenomegaly have been commonly reported under 5% of the cases (9). However, Dumas et al. (3) reported its' prevalence as 14.8% in their study. Cutaneous involvement such as rashes, erythematous macules, erythematous papules, or plaques and lesions can infrequently be presented. It manifests mostly on face and upper body, and most commonly as skin rashes (10). Dumas et al. (3) reported skin rashes within 32.9% of cases with KFD. In a recent case study of 11 patients, Al Mosavi et al reported that all patients had fever, 6 (54.5%) of them had fatigue and/or weakness, 5 (45.5%) of them had arthralgia and/or arthritis and 4 (36.4%) of them had skin rash (11). Our case was a 16 years old boy. He had tender cervical lymphadenopathy with combined fever, night sweats and weight loss. He had no cutaneous findings or any upper respiratory system's infection.

There are no specific laboratory tests for the diagnosis of KFD. However, elevated liver enzymes such as lactate dehydrogenase and transaminases, increased rate of sedimentation, increased C-reactive protein, anemia, leukopenia or leukocytosis have been reported in some cases (12,13). In our case, hemogram, levels of liver enzymes and C- reactive protein were in normal range, while the sedimentation rate was slightly increased (25mm/h).

The definitive diagnosis can be obtained with excisional biopsy and histopathological examination of lymphadenopathy (5). Upon histologic examination, lymph nodes often have an architecture partially preserved with follicular hyperplasia. The paracortex expands and shows areas of irregular, well-defined necrosis. Necrotic foci show abundant karyorrhectic nuclear waste and a large accumulation of histiocytes at the edge of necrosis (4). There are numerous CD8-positive lymphocytes and CD68-positive histiocytes in KFD. On histopathological examination of lymph node in our case, diffuse necrosis and CD68+ histiocyte proliferation were observed, thus KFD was diagnosed.

The differential diagnosis should be considered in terms of infectious lymphadenitis, autoimmune lymphadenopathy, especially systemic lupus erythematosus, and lymphoma. We investigated with serological tests for EBV, CMV, Parvovirus, Rubella, HIV, Toxoplasma

gondii, and Brucella, and there were not any acute infectious findings for these agents. Also, QuantiFERON, PPD tests were detected negative and the chest X-ray was normal, therefore tuberculosis was excluded. In addition, evaluated levels of C3, C4, ANA, anti dsDNA -in order to exclude SLE- were normal. Although presence of lymphadenopathy, fever, night sweats, and weight loss also suggested lymphoma, this diagnosis was excluded via the biopsy.

KFD is a benign condition that usually resolves in a few months. The rate of recurrence has been reported between 3-4%. However, prolonged systemic symptoms and severe complications as hemophagocytic syndrome (HS) have been reported in some patients in the data (14,15).

The number of case reports documenting familial cases of KFD in siblings is very limited. In a recent report, Quadir *et al* reported two cases of familial KFD in dizygotic HLA identical twins. These two cases were important in terms of demonstrating the role of HLA-linkage in the etiology KFD (16).

There is no specific therapy for KFD. Non-steroid anti-inflammatory drugs could be used for treatment. If there is a presence of SLE or HS, steroids or intravenous immunoglobulins could be used (8). In our case, all symptoms regressed with NSAID in two weeks. There has not been recurrence during the follow-up period of two years.

CONCLUSION

Lymphadenopathy, fever, fatigue, night sweats, and weight loss can be findings of underlying severe diseases such as tuberculosis, SLE, or lymphoma. However, KFD that is a self-limiting benign disease should also be considered among the differential diagnoses.

Conflict of interest: The authors declare no conflict of interest.

Informed Consent: Written informed consent was obtained from the patient who presented in this case report.

REFERENCES

1. Kikuchi M. Lymphadenitis showing focal reticulum cell hyperplasia with nuclear debris and phagocytosis. *Nippon Ketsueki Gakkai Zasshi*. 1972;35:378–380.
2. Fujimoto Y, Kozima Y, Hamaguchi K. Cervical necrotizing lymphadenitis: a new clinicopathological agent. *Naika*. 1972;20:920–927.
3. Dumas G, Prendki V, Haroche J, Amoura Z, Cacoub P, Galicier L *et al*. Kikuchi-Fujimoto disease: retrospective study of 91 cases and review of the literature. *Medicine (Baltimore)*. 2014;93(24):372–382.
4. Perry AM, Choi SM. Kikuchi-Fujimoto Disease: A Review. *Arch Pathol Lab Med*. 2018;142(11):1341-1346.
5. Singh JM, Shermetaro CB. Kikuchi-Fujimoto disease in Michigan: a rare case report and review of the literature. *Clin Med Insights: Ear, Nose and Throat*. 2019;12:1-5.
6. Jamal AB. Kikuchi-Fujimoto disease. *Clin Med Insights Arthritis Musculoskeletal Disord*. 2012;5:63–6.
7. Lin HC, Su CY, Huang CC, Hwang CF, Chien CY. Kikuchi's disease: a review and analysis of 61 cases. *Otolaryngology*. 2003;128(5):650–3.
8. Lelii M, Senatore L, Amodeo I, Pinzani R, Torretta S, Fiori S *et al*. Kikuchi-Fujimoto disease in children: two case reports and a review of the literature. *Ital J Pediatr*. 2018;44:83.
9. Kucukardali Y, Solmazgul E, Kunter E, Oncul O, Yildirim S, Kaplan M. Kikuchi-Fujimoto Disease: analysis of 244 cases. *Clin Rheumatol*. 2007;26(1):50-54.
10. Atwater AR, Longley BJ, Aughenbaugh WD. Kikuchi's disease: case report and systematic review of cutaneous and histopathologic presentations. *J Am Acad Dermatol*. 2008;59:130–136.
11. Al Mosawi Z, Ebrahim B, Baik S, Madan W, Aljufairi E. Kikuchi-Fujimoto Disease: Eleven pediatric cases and literature review. *Arch Rheumatol*. 2020;35(2):303-307.
12. Deaver D, Naghashpour M, Sokol L. Kikuchi-Fujimoto disease in the United States: three case reports and review of the literature. *Mediterr J Hematol Infect Dis*. 2014;6(1):e2014001.
13. Lee BC, Patel R. Kikuchi-Fujimoto Disease: A 15-year analysis at a children's hospital in the United States. *Clin Pediatr*. 2013;52:92-95.
14. Hutchinson CB, Wang E. Kikuchi-fujimoto disease. *Arch Pathol Lab Med*. 2010;134(2):289–293.
15. Lin YW, Horiuchi H, Ueda I, Nambu M. Recurrent hemophagocytic lymphohistiocytosis accompanied by Kikuchi's disease. *Leuk Lymphoma*. 2007;48:2447–2451.
16. Quadir A, Peacock K, Hsu P, Singh-Grewal D, Alexander S. A familial case of Kikuchi-Fujimoto disease in dizygotic twins. *Pediatr Rheumatol Online J*. 2020;18(1):62.