

Evaluation of Early and Late Period Arthroplasty Results in the Treatment of Incomplex Acetabular Fractures with Coxarthrosis

Koksartrozlu Kalçada Gelişen Kompleks Asetabuler Kırığın Tedavisinde Erken ve Geç Dönem Artroplasti Sonuçlarının Değerlendirilmesi

Vahit YILDIZ¹, Ali SISMAN², Caner POYRAZ¹, Halil YILDIRIM³, Kadri YILDIZ⁴, Sevki Oner SAVK¹

¹ Adnan Menderes University Faculty of Medicine, Department of Orthopaedics and Traumatology, Aydın, Turkey

² Istanbul Umraniye Training and Research Hospital, University of Health Sciences, Department of Orthopaedics and Traumatology, Istanbul, Turkey

³ Ercis Sehit Ridvan Cevik State Hospital, Orthopaedics and Traumatology Clinic, Van, Turkey

⁴ Kafkas University Faculty of Medicine, Department of Orthopaedic and Traumatology, Kars, Turkey.

Özet

Amaç: Bu çalışmada koksartrozu mevcut olup kompleks asetabulum kırığı nedeniyle erken ve geç kalça artroplastisi yapılan hastaların klinik sonuçlarını karşılaştırmayı ve klinik sonuçları etkileyen faktörleri araştırmayı amaçladık.

Gereç ve Yöntemler: 2005 ve 2017 yılları arasında asetabular kırık nedeniyle ameliyat edilen hastalar geriye dönük olarak incelendi. Letournel Sınıflamasına göre kompleks kırıklar ve Kellgren-Lawrence radyolojik kriterlerine göre artrozu olan hastalar, çalışmaya dahil edildi. Hastalar artroplasti yapılmaya zamanlarına göre kırık sonrası erken dönem (grup 1) ve geç dönem (grup 2) olmak üzere iki gruba ayrıldı. Her iki grup Harris kalça skoru, Visual Analogue Scale (VAS), yaş, artroz, ameliyat süresi ve günlük hayata dönme süresi açısından karşılaştırıldı.

Bulgular: Çalışmaya alınan hastaların 20'sinin erken dönemde, 21'inin ise geç dönemde artroplasti geçirdiği belirlendi. Ortalama Harris skoru erken artroplasti yapılanlarda 71.60±13.5, geç artroplasti yapılanlarda 61.23±2.6 idi (p=0.002). Ortalama VAS skoru erken artroplasti yapılanlarda 1.7 (1-3), geç artroplasti yapılanlarda 2.6 (1-5) idi (p=0,102).

Sonuç: Erken artroplasti, koksartroz zemininde kompleks asetabular kırığı olan hastalarda geç artroplastiyeye göre daha iyi fonksiyonel sonuç ve daha düşük komplikasyon oranları ile daha güvenli bir seçenektir. Koksartroz zemininde kompleks asetabular kırığı olan hastalarda, cerrahın erken veya geç artroplasti kararında arada kaldığı durumlarda, erken artroplasti tercih edilmelidir.

Anahtar Kelimeler: Asetabular kırık, Koksartroz, Total kalça replasmanı

Abstract

Objective: We aimed to compare the clinical results of patients who underwent early and late hip arthroplasty due to complex acetabulum fracture with coxarthrosis and investigate the factors affecting the clinical results.

Material and Methods: Patients who were operated on for acetabular fractures between 2005 and 2017 were retrospectively analysed. Patients with complex fractures according to the Letournel Classification and arthrosis according to the Kellgren-Lawrence radiological criteria were included in the study. Patients were divided in to two groups, post-fracture early period (group 1) and late period (group 2), based on when they underwent arthroplasty. Both groups were compared in terms of Harris hip score, Visual Analogue Scale (VAS), age, arthrosis, operation time, and time to return to daily life.

Result: It was determined that 20 of the patients included in the study underwent arthroplasty in the early period and 21 in the late period. The mean average Harris score was 71.60±13.5 in those who underwent early arthroplasty and 61.23±2.6 in those who underwent late arthroplasty (p=0.002). The average VAS score was 1.7 (1-3) in those who underwent early arthroplasty and 2.6 (1-5) in those who underwent late arthroplasty (p=0.102).

Conclusion: Early arthroplasty is a safer option with better functional results and lower complication rates than late arthroplasty in patients with complex acetabular fractures with coxarthrosis. In patients with complex acetabular fractures with coxarthrosis, early arthroplasty should be preferred when the surgeon is not sure about early or late arthroplasty.

Keywords: Acetabular fracture, Coxarthrosis, Total hip replacement.

Yazışma Adresi: Vahit YILDIZ, Adnan Menderes Üniversitesi, Tıp Fakültesi, Ortopedi ve Travmatoloji BD, Aydın, Türkiye

Telefon: +905052932783, **Mail:** dr.vyildiz44@hotmail.com

ORCID No: (Sırasıyla): 0000-0003-3639-0912, 0000-0001-8461-3258, 0000-0002-3169-2455, 0000-0002-6333-8303, 0000-0002-8164-7687, 0000-0003-1647-7260

Geliş tarihi: 06.04.2021

Kabul tarihi: 24.04.2021

DOI: 10.17517/ksutfd.910837

INTRODUCTION

Acetabular fractures develop due to serious trauma, such as an out-of-vehicle traffic accident or falling from a height, with an incidence of 3 in 100,000 (1). Acetabular fractures cause serious injury to the hip joint. Currently, the standard treatment is open reduction and internal fixation (2). Important factors impacting the success of surgical treatment include the patient's age, type of fracture, presence of arthrosis, type of injury, damage to the femoral head, success in fracture reduction, development of heterotopic ossification, and timing of the surgery (3). On the other hand, complex fractures involving the posterior wall, severe damage to the femoral head or marginal impaction to the acetabulum have high complication rates and generally result in arthrosis (4). Although long-term results are positive with a good open reduction and internal fixation, arthrosis develops in 10–80% of patients after acetabular fractures (5). Treatment principles in selected cases with a background of arthrosis may vary depending on the age of the patient, the degree of fracture, damage to the femoral head, and the surgeon. Along with internal fixation, arthroplasty also plays an important role in the treatment (5-9).

The risk of developing infections due to the development of additional scar tissue, heterotopic ossification, soft tissue damage, or impaired blood supply of the acetabulum increases when hip arthroplasty is applied to patients whose initial treatment was fixation (10). In this study, we aimed to compare the clinical results of early and late arthroplasty in patients with coxarthrosis with complex acetabular fractures and help surgeons decide the timing of arthroplasty. Additionally, we aimed to investigate the factors affecting the results of early and late arthroplasty.

MATERIALS AND METHODS

Patients with complex acetabular fractures according to the Letournel classification who were treated between 2005 and 2017 in our clinic were analysed retrospectively. Patients with arthrosis and complex acetabular fractures according to Kellgren-Lawrence radiological criteria in the preoperative period were included in the study. The patients who underwent internal fixation and early arthroplasty in the first 21 days were assigned to group 1, and the patients who underwent only internal fixation and late-term arthroplasty in their follow-up were assigned to group 2. All operations were performed by a single surgeon (Sevki Oner SAVK). The final decision on implant selection was made during the surgery. In cases where the surgeon was uncertain about performing

early arthroplasty, a random arthroplasty decision was made. In cases with impaction on the acetabular edge, lesions in the femoral head, or where mobilisation was desired as soon as possible, the total hip prosthesis was applied together with internal fixation, considering the degree of bone loss. In cases where fixation was deemed necessary, an acetabular roof was created from the posterior with plate and screws or with screws alone. The number and type of screws were adjusted by the surgeon to ensure stability. After capsulotomy with a posterior approach, the hip was removed and the femoral head was resected in all patients. The femoral head was used as a graft for the acetabulum in cases of acetabular defects. A posterior approach was applied to all cases in the group in which arthroplasty was applied in the late period. The acetabulum was reamerised until the cancellous bone was reached and appropriate containers were placed. During the acetabular reaming, since no screw penetration into the joint was observed and sufficient depth was reached while placing the cup, arthroplasty was performed without any implant removal. Patients in both groups were immediately mobilised. They were called for their first check-up in the fourth week. Patients whose results were not available and whose follow-up period was less than one year were excluded from the study. The fracture type, age, duration of surgery, clinical results, Harris Hip Score, and Visual Analogue Scale (VAS) pain scale were compared between the groups.

This study was approved by the Medical Faculty Ethics Committee (2018/1299). All procedures followed were in accordance with the ethical standards of the responsible committee on human experimentation (institutional and national) and with the Helsinki Declaration of 1975, as revised in 2008. SPSS 18.0 was used for processing the data. The normality of the data was evaluated using the Kolmogorov-Smirnov and Shapiro tests. The Mann-Whitney U test was used for variables that did not show a normal distribution and a t-test was used for values that were normally distributed. P values <0.05 were considered statistically significant. Written informed consent was given by the participants.

RESULTS

According to the Kellgren-Lawrence radiological criteria, 41 of 127 patients who were retrospectively examined had moderate/severe arthrosis and complex acetabular fracture. Twenty patients underwent early arthroplasty and internal fixation (**Figure 1A-1B**). Twenty-one patients had only internal fixation and late arthroplasty at an average of 28 months (12–42) (**Figure 2**).

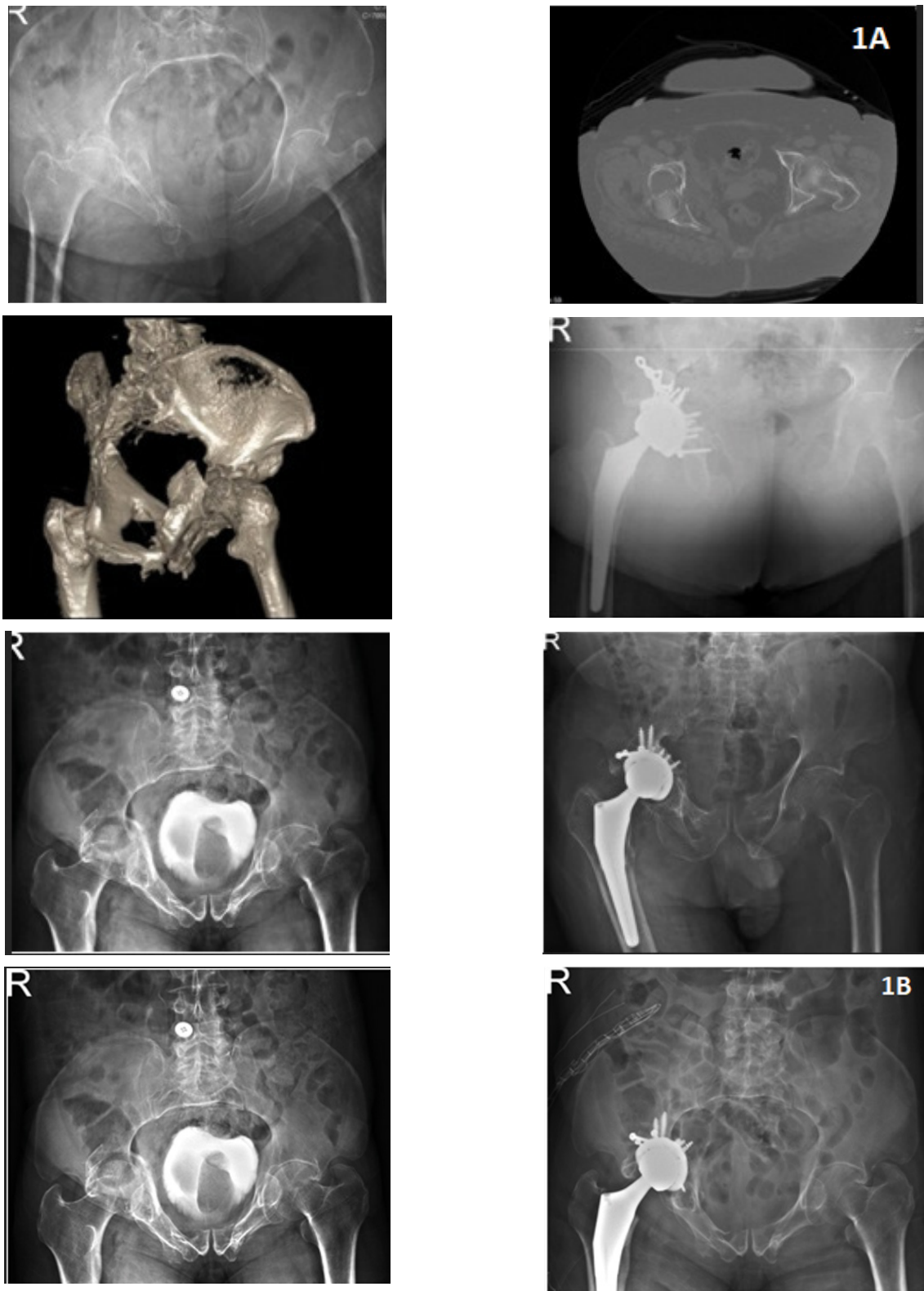


Figure 1A and 1B. Internal fixation and early arthroplasty in a patient with an acetabular fracture with moderate coxarthrosis

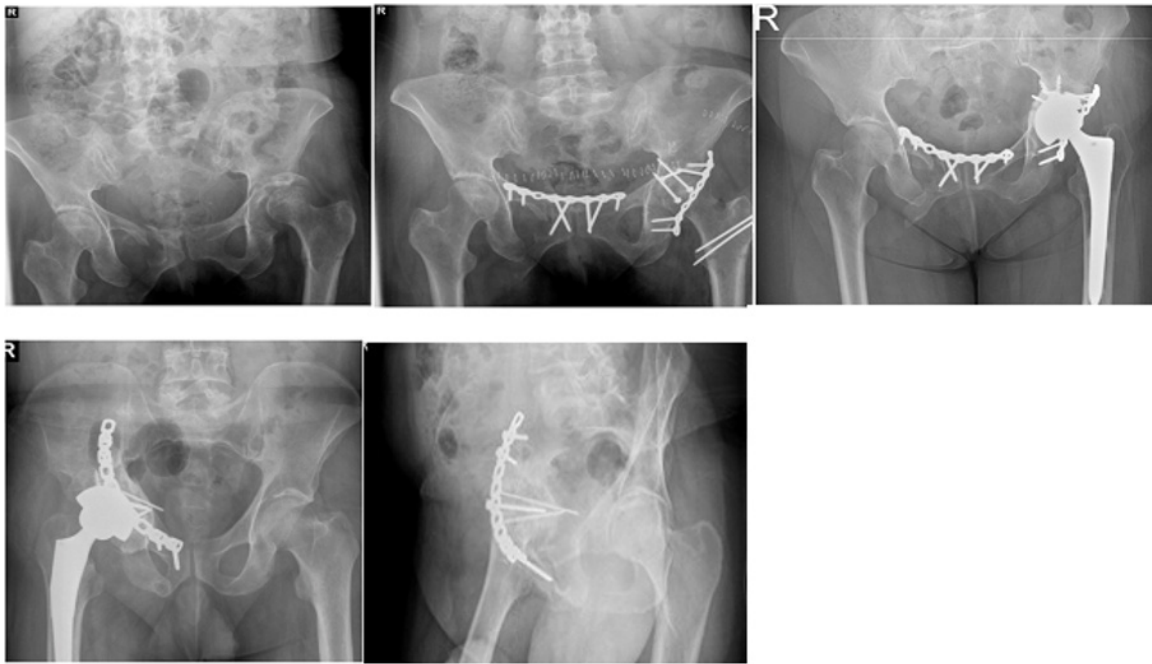


Figure 2. Late arthroplasty

The mean follow-up time was 34.54 ± 11.45 months in the early arthroplasty group and 27.20 ± 9.49 months in the late arthroplasty group ($p=0.128$). In the early arthroplasty group, nine of the patients were female and eleven were male. In the late arthroplasty group, nine patients were female and twelve were male. The mean age was 66.40 ± 6.4 in the early arthroplasty group and 63.22 ± 4.5 in the late arthroplasty group.

When the two groups were compared in terms of age, gender, degree of arthrosis, follow-up time, and fracture types, there was no significant difference between them (Tables 1 and 2).

Table 1. Degrees of arthrosis in the patients

	Early arthroplasty	Late arthroplasty
G0	0	0
G1	1	2
G2	10	13
G3	8	6
G4	1	0

Table 2. Preoperative complex fracture classification of patients

	Early arthroplasty	Late arthroplasty
Posterior column. posterior wall	1(%5)	0
Anterior column. posterior column	5(%25)	7(%33.3)
Transverse. Posterior wall	5(%25)	7(%33.3)
T shape	5(%25)	4(%19)
Anterior column. posterior hemitransverse	4(%20)	3(%14.2)

The mean duration of operation was 157.5 ± 17.67 minutes in the early arthroplasty group and 105.33 ± 25.4 minutes in the late arthroplasty group. There was a statistically significant difference between operation times ($p < 0.001$). The

Table 3. Comparison of Harris score, VAS, operation time, age, and follow-up times of both groups

	Early arthroplasty	Late arthroplasty	p
Harris Score	71.60 ± 13.5	61.23 ± 2.6	0.002
VAS	1.7 (1–3)	2.6 (1–5)	0.102
Operation time	157.5 ± 17.67	105.33 ± 25.4	<0.001
Age	66.40 ± 6.4	63.22 ± 4.5	0.121
Follow up time	34.54 ± 11.45	27.20 ± 9.49	0.128
Back to daily life (months)	5.42 ± 1.39	7.23 ± 2.65	0.153

VAS:visual Analogue Scale, p values <0.05 were considered statistically significant.

mean time for returning to daily life was 5.42 ± 1.39 months in the early arthroplasty group and (7.18 ± 2.85) months in the late arthroplasty group ($p=0.153$). The data from three patients in the late arthroplasty group were not included in this analysis, as they were not performing work that requires physical effort. There was no significant difference between the two groups in terms of time to return to daily life and the VAS scale ($p=0.153$, $p=0.102$) (Table 3).

There was a significant difference between Harris hip scores ($p=0.002$). In the early arthroplasty group, one patient had a dislocation, one patient had a pulmonary embolism, and two patients had heterotopic ossification. In the late arthroplasty group, one patient had sciatic symptoms (drop foot), three patients had an infection, and five patients had heterotopic ossification (Table 4).

Table 4. Frequency of complications seen in both groups

	Early arthroplasty	Late arthroplasty
Postoperative dislocation	1	0
Loosening	0	1
Pulmonary embolism	1	0
Sciatic injury	0	1
Infection	0	3
Heterotopic ossification	2	5

DISCUSSION

Treatment principles in complex acetabular fractures with coxarthrosis vary according to the fracture type, age, and osteoporosis. There are studies in the literature on internal fixation and arthroplasty related to acetabular fracture. However, there is no study comparing the results of early and late arthroplasty on arthrosis in these fractures. In this study, we evaluated the outcomes of patients who had complex acetabular fractures with arthrosis, who underwent either early or late arthroplasty. According to our study, clinical results in patients who underwent early arthroplasty were statistically better than those in the late arthroplasty group. In our opinion, the reason for this may be the further progression of arthrosis due to trauma in the late arthroplasty group, the fact that the patients have had two operations, and the negative effects of complications due to these operations. Alongside the literature reviews, we aimed to support this hypothesis below.

There are many studies in the literature showing that arthrosis increases in patients who have undergone primary internal fixation after acetabular trauma. In a study of 79 cases published by Mesbahi et al, it was reported that 60.8%

of osteoarthritis cases developed after surgery (7). In 2019, Busch et al. compared the rates of arthrosis in patients with simple and complex acetabular fractures, reporting that arthrosis developed in 72% of complex fractures and 50% of simple fractures (11). While the risk of developing coxarthrosis is 13% in fractures with a fracture displacement less than 2 mm, this rate reaches 44% in patients with a fracture displacement of more than 2 mm (12). Letournel reported that severe osteoarthritis and avascular necrosis of the femoral head can develop as a result of internal fixation (5). One of the reasons for the poor clinical outcomes of patients who underwent late arthroplasty may be the further progression of arthrosis as a result of trauma.

Early fixation was found to have high complication rates in patient's with moderate to advanced coxarthrosis pre-fracture, femoral neck fracture, osteoporosis, and multiple comminuted fractures. Also, studies have reported that non-anatomical acetabular reduction and acetabular roof incompatibility after primary fixation have similarly poor results and that arthroplasty should be performed in the early period in complex acetabulum fractures (12-20). Sermon reported that the Harris Hip score results were satisfactory in patients who underwent primary arthroplasty after acetabulum fracture (19). As stated in the literature, unsatisfactory clinical results of primary internal fixation in complex acetabular fractures and satisfactory results of early arthroplasty can be preferred in these cases of early arthroplasty with internal fixation.

The risk of complications such as ossification, infection, fibrotic tissue and adhesions is higher in patients who undergo delayed arthroplasty compared to the early arthroplasty group. This is because the patients in this group had two operations. These complications may cause contracture development, limitation of movement and muscle weakness, and may adversely affect the patient's clinical outcomes. One of the complications that develops after acetabular fracture is heterotopic ossification, with many studies reporting this complication. Giannoudis et al. reported 25.6%, Stibolt et al. reported a 28–63% incidence, and Sermon et al. reported 28% in the early period and 41% in the late period (12,13,18). In their study, Mears et al. reported that, when hip arthroplasty is applied to patients whose initial treatment is fixation, complications such as an extra scar, heterotopic ossification development, soft tissue damage, and infection due to impaired blood supply of the acetabulum may develop, and these results will adversely affect the patient's clinical outcomes (10). In our study, the heterotopic ossification rate in patients who underwent late arthroplasty was % 23.80, whereas it was %10 in the early arthroplasty group. While no infection was observed in any patient in the early arthroplasty group, infection was observed in three (%14.2) patients in the late arthroplasty group.

Early loosening and dislocation of arthroplasty are important complications (18). Herscovici et al. reported that five of 22 patients who underwent arthroplasty due to acetabular fracture had loosening and recurrent dislocation, and

therefore revision surgery was performed (17). In our study, component loosening was observed in one patient in the late arthroplasty group. We attributed this to the fact that the acetabulum was excessively sclerosed, the vessel was placed and osteointegration was not sufficiently reached. Recurrent dislocation was also observed in one (5%) patient in the early arthroplasty group. Closed reduction was performed under anaesthesia three times in this patient. No re-dislocation was observed in the 21st-month follow-up. In our study, heterotopic ossification developed in five (23.8%) of the patients who underwent late arthroplasty and in two (10%) of the patients who underwent early arthroplasty, in parallel with the literature.

Carol et al. reported that there was no statistically significant relationship between the outcomes of patients who underwent early arthroplasty and the type of fracture, patient age, and fixation type (16). In our study, there was no statistically significant difference between the two groups in terms of fracture type, patient age, and gender.

In conclusion, arthrosis increases further after primary internal fixation of complex acetabular fractures in patients undergoing late arthroplasty. Progression of arthrosis may negatively affect the clinical outcome of late arthroplasty. Since the patients undergoing late arthroplasty have two operations, the consequent increase in complications may adversely affect the clinical outcome. The fact that acetabulum reduction is relatively more difficult in complex fractures with primary internal fixation may lead to an inadequate and incorrect reduction and deterioration of the anatomical structure of the acetabular roof. This result may adversely affect the clinical outcome of late arthroplasty. According to our study, the first choice in these cases should be early arthroplasty with internal fixation, due to these factors and the results of arthroplasty applied in the early period. We believe that performing early arthroplasty will shorten the return to daily life, eliminate the need for a second surgery, and reduce the risk of complications and costs.

However, this study has some limitations. The sample size was not high, the post-operative physical therapy was not performed by us, we were unable to determine how much arthrosis progressed after the primary fixation applied to the patients with coxarthrosis, and we could not statistically evaluate the osteoporosis seen in the patients. Both the early and late arthroplasty groups should be investigated in more detail in further studies with more cases. The clinical and functional results of arthroplasty applied in the early period in complex acetabular fractures with coxarthrosis are more satisfactory than in the late period. In complex acetabular fractures, arthroplasty should be performed early, with internal fixation.

Conflict of Interest and Financial Status: Our study has not been financed by an institution and institution. In this study, there is no conflict of interest among the authors on any subject.

Ethical Approval: This study was approved by the Medical Faculty Ethics Committee (2018/1299).

Research Contribution Rate Statement Summary: The authors declare that, they have contributed equally to the manuscript

REFERENCES

- Laird A, Keating JF. Acetabular Fractures: A 16-Year prospective epidemiological study. *J Bone Joint Surg Am* 2005;87(7):969-973.
- Saterbak AM, Marsh JL, Nepola JV, Brandser EA, Turbett T. Clinical failure after posterior wall acetabular fractures: The influence of initial fracture patterns. *J Orthop Trauma* 2000;14(4):230-237.
- Chen HW, Zhao GS. Surgical treatment of acetabular posterior wall fractures. *Zhonggongguo Gu Shang* 2008;21(9):674-675.
- Tannast M, Najibi S, Matta JM. Two to twenty-year survivorship of the hip in 810 patients with operatively treated acetabular fractures. *J Bone Joint Surg Am* 2012; 94(17):1559-1567.
- Letournel E. Acetabulum fractures: Classification and management. *Clinic Orthop Relat Res* 1980;151(Sept):81-106.
- Frietman B, Biert J, Edwards MJR. Patient-reported outcome measures after surgery for an acetabular fracture. *Bone Joint J*. 2018;100(5):640-645.
- Mesbahi SAR, Ghaemmaghami A, Ghaemmaghami S, Farhadi P. Outcome after surgical management of acetabular fractures: A 7-year experience. *Bull Emerg Trauma* 2018;6(1):37-44.
- Negrin LL, Seligson D. Results of 167 consecutive cases of acetabular fractures using the Kocher-Langenbeck approach: A case series. *J Orthop Surg Res*. 2017;12(1):66.
- Isaacson MJ, Taylor BC, French BG, Poka A. Treatment of acetabulum fractures through the modified stoppa approach: Strategies and outcomes. *Clinic Orthop Rel Res*. 2014;472(11):3345-3352.
- Mears DC and Velyvis JH. Primary total hip arthroplasty after acetabular fracture. *Instr Course Lect*. 2001;50:335-354.
- Busch A, Stöckle U, Schreiner A, de Zwart P, Schäffler A and Ochs BG. Total hip arthroplasty following acetabular fracture: a clinical and radiographic outcome analysis of 67 patients. *Arch Orthop Trauma Surg* 2020;140(3):331-341.
- Giannoudis PV, Grotz MRW, Papakostidis C, Dinopoulos H. Operative treatment of displaced fractures of the acetabulum. A Meta-Analysis. *J Bone Joint Surg* 2005;87(1):2-9.
- Stibolt RD Jr, Harshadkumar AP, Huntley SR, Lehtonen EJ, Shah AB, Naranje SM. Total hip arthroplasty for posttraumatic osteoarthritis following acetabular fracture: A systematic review of characteristics, outcomes, and complications. *Chine J Traumatol*. 2018;21(3):176-181.
- Enocson A, Blomfeldt R. Acetabular fractures in the elderly treated with a primary burch-schneider reinforcement ring, autologous bone graft, and a total hip arthroplasty: A Prospective Study with a 4-year follow-up. *J Orthop Trauma* 2014;28(6):330-337.
- Resch H, Krappinger D, Moroder P, Auffarth A, Blauth M, Becker J. treatment of acetabular fractures in older patients-introduction of a new implant for primary total hip arthroplasty. *Archiv Orthop Trauma Surg*. 2017;137(4):549-556.
- Carol L, Caron J, Schmidt AH, Torchia M, Templeman D. Functional outcomes after total hip arthroplasty for the acute management of acetabular fractures: 1- to 14-Year Follow-Up. *J Orthop Trauma*. 2015;29(3):151-159.

17. Herscovici D Jr, Lindvall E, Bolhofner B, Scaduto JM. The combined hip procedure: open reduction internal fixation combined with total hip arthroplasty for the management of acetabular fractures in the elderly. *J Orthop Trauma*. 2010;24(5):291-296.
18. Sermon A, Broos P, Vanderschot P. Total hip replacement for acetabular fractures. Results in 121 patients operated between 1983 and 2003. *Injury*. 2008;39(8):914-921.
19. Matta JM. Fractures of the acetabulum: accuracy of reduction and clinical results in patients managed operatively within three weeks after the injury. *J Bone Joint Surg Am* 1996;78(11):1632-1645.
20. Mouhsine E, Garofalo R, Borens O, Fischer JF, Crevoisier X, Pellet S et al. Acute total hip arthroplasty for acetabular fractures in the elderly: 11 patients followed for 2 years. *Acta Orthop Scand*. 2002;73(6):615-618.