



Coalition of trapezoid, capitate, and metacarpal: a case report

Semra DURAN¹, Bedriye MERMERCİ BAŞKAN²

¹Ankara Numune Training and Research Hospital, Department of Radiology, Ankara, Turkey

²Ankara Numune Training and Research Hospital, Department of Physical Medicine and Rehabilitation, Ankara, Turkey

Carpal coalition is a rare wrist anomaly. A coalition can be an isolated condition, but it can be observed as a component of a congenital syndrome as well. Carpal coalition is usually asymptomatic and detected incidentally. It is most frequently encountered as lunate-triquetral coalition, followed by capitate-hamate coalition. Other coalition types are very rare. In this case report, we present a case in which the patient applied with complaints of pain, and in whom a coalition of capitate-trapezoid- second and third metacarpal was detected.

Keywords: Carpal bone; coalition; metacarpal bone.

Carpal bone anomalies can be classified in terms of variations of number, size, and shape, or as a fusion with neighboring bones.^[1] A coalition, which is often called a carpal fusion, develops due to non-segmentation of growth seeds, which would form 2 different bones.^[2] It can occur as a component of an isolated anomaly or a systemic syndrome.^[2–4] Congenital isolated carpal coalition is asymptomatic in most cases and detected incidentally in radiograms taken for various reasons.^[3,5] It may become symptomatic by altering the normal biomechanics of the wrist.^[6] The most commonly detected coalition occurs between the lunate and the triquetrum.^[1–5] Coalition of the trapezoid and the capitate is rare.^[6] Few cases have been reported in the literature in English.

We aimed to present a rare case of coalition of capitate-trapezoid- second and third metacarpal.

Case report

A 50-year-old male patient applied to our hospital with complaints of pain in the left wrist that had been ongoing for 3 months. There was no trauma or history of rheumatoid disease. Both wrists appeared normal, with no swelling or deformity. There was no area of localized tenderness in either wrist, and movements were normal. Physical examination of both upper limbs was normal. No anomalies were observed in laboratory findings. In elbow radiogram, a coalition was detected in the left wrist, between capitate-trapezoid- second and third metacarpal, with continuation of trabecular appearance. No cystic or sclerotic changes were observed on the joint surfaces of these bones. An avulsion fracture of the styloid process of the ulna drew attention. In the right wrist radiogram, bone structures were evaluated as

Correspondence: Semra Duran, MD. Ankara Numune Eğitim ve Araştırma Hastanesi, Radyoloji Kliniği, Ankara, Turkey.

Tel: +90 312 – 508 48 71 e-mail: semraduran91@gmail.com

Submitted: January 15, 2014 **Accepted:** June 18, 2014

©2015 Turkish Association of Orthopaedics and Traumatology

Available online at

www.aott.org.tr

doi: 10.3944/AOTT.2015.14.0031

QR (Quick Response) Code



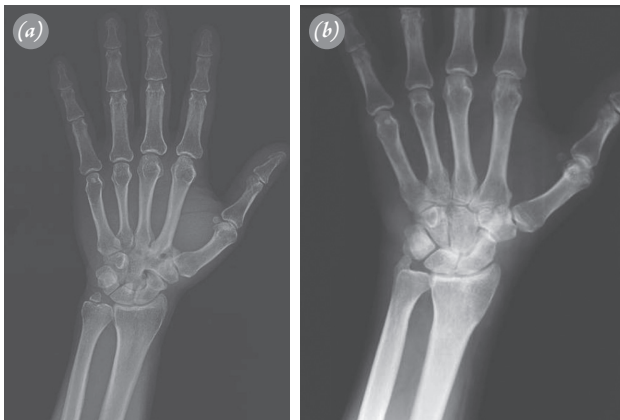


Fig. 1. (a) In left wrist radiogram, coalition between capitate-trapezoid- second and third metacarpal, and avulsion fracture in the styloid process of the ulna are present. (b) In the right wrist, bone structures are normal.

normal (Figures 1a, b). In magnetic resonance imaging (MRI) of the left wrist, in addition to direct radiography findings, bone marrow edema was detected on the joint surfaces of the capitate, the lunate, and the hamate bones (Figures 2a, b). Medical treatment was begun.

Discussion

Carpal coalition is a rare wrist anomaly, the incidence of which varies by race and geographical region. It has been reported as 0.1% in the Caucasian race, rising to 1.6% in African American males and 9.5% in African American females.^[1,2,5,7]

A coalition develops due to a segmentation deficiency of primitive cartilaginous canals and results in the absence of joint formation between bones.^[2,4,8] Acquired coalition may develop as a result of trauma, degenerative arthritis, or juvenile rheumatoid arthritis. Iatrogenic surgical fusion is used in the treatment of Kienböck's disease.^[1,3,4,8]

A coalition can be an isolated condition, but it can be observed as a component of a congenital syndrome as well. An isolated coalition is often seen between 2 bones on the same row. Massive carpal coalition, coalition between proximal and distal rows of carpal bones, and coalition between radius-ulna and carpal bones usually coexist with syndromes.^[1-9] Coexistence with arthrogyposis, symphalangia, diastrophic dwarfism, Turner syndrome, Ellis-van Creveld syndrome, otopalatodigital syndrome, and hand-foot-uterus syndrome has been reported.^[1,2,4-9]

Isolated coalition may be seen between almost all carpal bones, most frequently as coalition between the lunate and triquetrum, followed by coalition between the

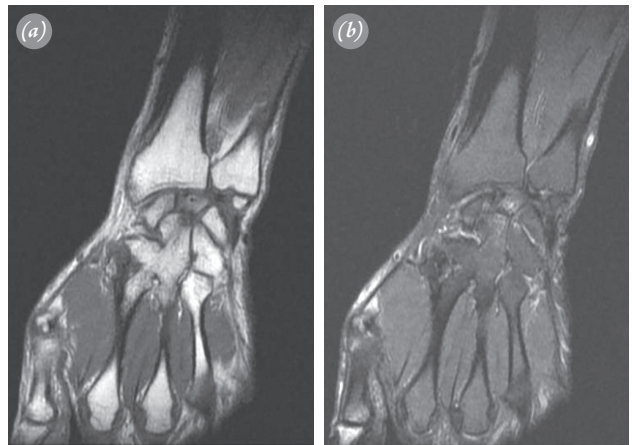


Fig. 2. Coalition in coronal T1- (a) and fat-suppressed T2- (b) weighted image, and bone marrow edema in capitate, lunate, and hamate can be seen.

capitate and hamate. Coalition is quite rare between the radius and carpal bones and between the distal row and metacarpal bones.^[2-9] The cases most similar to ours that we found in the English-language literature were cases of capitate-trapezoid,^[1,3,9] capitate-metacarpal,^[5] and capitate-hamate coalitions.^[8] Alemohammad et al. examined 202 wrists from cadavers for carpal boss and osseous coalition between capitate-trapezoid- second and third metacarpal. They detected coalitions between the second metacarpal-trapezoid in 18%, the third metacarpal-trapezoid in 10%, the capitate-trapezoid in 5%, and the second-third metacarpal in 2%. They reported incomplete coalitions involving these 4 bone structures in 2 wrists.^[10]

Almost all cases of carpal coalition are asymptomatic and are usually detected coincidentally. No wrist dysfunction is detected in these patients, and ranges of joint movements are full.^[4] However, because movement of bones involved in coalition is not possible, pain may occur due to increasing compensatory movements of neighboring joints and soft tissues. Since there is no intra-articular cartilaginous structure, degenerative arthritis may occur as a result of the increased load on the coalition. Risk of fracture is high in bones involving coalition. In pisiform-hamate coalition, neuropathy caused by ulnar nerve entrapment may be the cause of patients' application.^[1-4,8] Incomplete coalition is known to cause latent wrist pain, with findings similar to degenerative arthritis.^[7] There is little motion at the normal capitate-trapezoid- second and third metacarpal joint, as it is a fixed unit of the wrist.^[9] Therefore, in patients with carpal coalitions, as in our case, restriction in joint movements is not detected.

In cases with carpal coalitions, diagnosis is only possible with imaging methods. A coalition is identified

with a radiological trabecular appearance that shows continuity from one bone to another. A carpal coalition is classified as complete when its radiological appearance is in the form of a single bone unit, or incomplete when its appearance is in the form of a narrowing in joint range or an indentation. In incomplete coalition, there is no formation of sclerosis or osteophyte on the joint surfaces of bone structures.^[3,4,6] In cases of symptomatic coalition, direct contribution of radiography is limited. In such cases, cross-sectional imaging methods, MRI in particular, should be called upon. MRI is highly useful in characterizing carpal lesions and identifying symptomatic stress injuries in bone and soft tissue.^[7,8]

The symptoms of our case with complete coalition were thought to be caused by bone marrow edema, detected by MRI, in the capitate, lunate, and hamate. In MRI, no edema in the ulna or fragment was observed in the patient who had ulnar avulsion fracture. The patient had no history of trauma at the onset of symptoms. Avulsion fracture resulted from sport activity (wrestling).

In carpal coalition, treatment is seldom required for asymptomatic patients. For symptomatic patients, immobilization of the fracture, such as applying decompression for neuropathy, is recommended.^[3]

Conflicts of Interest: No conflicts declared.

References

1. Choudhry R, Tuli A, Chimmalgi M, Anand M. Os capitotrapezoid: a case report. *Surg Radiol Anat* 1998;20:373–5.
2. Suresh SS. Unusual coalition of the carpal bones with simian crease: a case report. *Acta Orthop Traumatol Turc* 2011;45:379–81.
3. Walia JPS, Sing A, Walia AK, Kumar D. Bilateral coalition of capitate&trapezoid a very rare case. *Ind J Radiol Imag* 2006;16:585–86.
4. Terrence Jose Jerome J. Congenital fusion of the trapezium and trapezoid. *Rom J Morphol Embryol* 2008;49:417–9.
5. Knezevich S, Gottesman M. Symptomatic scapholunatotriquetral carpal coalition with fusion of the capitometacarpal joint. Report of a case. *Clin Orthop Relat Res* 1990;251:153–6.
6. Singh P, Tuli A, Choudhry R, Mangal A. Intercarpal fusion: A Review. *J Anat Soc India* 2003;45:183–8.
7. Stähler A, Glaser C, Reiser M, Resnick D. Symptomatic fibrous lunato-triquetral coalition. *Eur Radiol* 1999;9:1643–6.
8. Hosalkar HS, Shaw BA, Carrie LC, Read H. Bilateral congenital capitate-hamate fusion. *J Postgrad Med* 2001;47:208–9.
9. Geutjens G. Carpal bossing with capitate-trapezoid fusion. A case report. *Acta Orthop Scand* 1994;65:97–8.
10. Alemohammad AM, Nakamura K, El-Sheneway M, Viegas SF. Incidence of carpal boss and osseous coalition: an anatomic study. *J Hand Surg Am* 2009;34:1–6.