

Treatment of Feline Mammary Fibroepithelial Hyperplasia with the Combination of Aglepristone and Cabergoline

Melih UÇMAK^{1*}, Sinem Özlem ENGİNLER¹, Mehmet Can GÜNDÜZ¹,
İsmail KIRŞAN¹, Kıvılcım SÖNMEZ²

¹Department of Obstetrics and Gynecology, Faculty of Veterinary Medicine, Istanbul University, Avcılar Campus, 34320, Avcılar, Istanbul

²Department of Pathology, Faculty of Veterinary Medicine, Istanbul University, Avcılar Campus, 34320, Avcılar, Istanbul

*Corresponding Author: Melih UÇMAK

¹Department of Obstetrics and Gynecology, Faculty of Veterinary Medicine, Istanbul University, Avcılar Campus, 34320, Avcılar, Istanbul, e-mail: dr_veterinarian@yahoo.com, Tel: +90-212 4737070/17322

Geliş Tarihi / Received: 23.07.2010

ABSTRACT

A case of fibroepithelial mammary hyperplasia in a two years old, intact, tabby female cat that showed oestrus 1 month ago was treated with the combination of aglepristone (Alizine, Virbac®) and cabergoline (Galastop, Ceva®) administrations. On the day of treatment, serum progesterone concentration was detected as 2,96 ng/ml and serum oestradiol concentration was below 5,0 pg/ml. The cat was treated with subcutaneous (SC) injections of aglepristone (Alizine, Virbac®) 15 mg/kg body weight (b.w.) on two subsequent days per week for three weeks and 5 µg/kg b.w per a day, per os (PO) cabergoline (Galastop, Ceva®) administration was accompanied to this treatment on the first week for seven days. On the examination at the end of the third week, there was a marked regression of the mammary glands and the milk secretion ceased. Six weeks after the initiation of treatment, mammary glands were completely regressed and serum progesterone and oestradiol concentrations were 0.142 ng/ml, and <5pg/ml respectively. It is determined that in such cases which is associated with milk secretion, successful results can be achieved by using aglepristone (Alizine, Virbac®) and cabergoline (Galastop, Ceva®) together.

Key Words: Fibroepithelial hyperplasia, aglepristone, cabergoline

ÖZET

KEDI MEME FIBROEPİTELYAL HİPERPLAZİSİNİN CABERGOLİN VE AGLEPRİSTON KOMBİNASYONU İLE TEDAVİSİ

Fibroepitelyal meme hiperplazi olgusu; kısırlaştırılmamış, 2 yaşlı, bir ay önce östrus göstermiş tekir dişi bir kedide aglepriston (Alizine, Virbac®) ve cabergolin (Galastop, Ceva®) kombinasyonu ile tedavi edildi. Tedavi günü, serum progesteron konsantrasyonu 2,96 ng/ml ve serum östradiol konsantrasyonu 5 pg/ml'den düşük olarak tespit edildi. Kedi, 15 mg/kg canlı ağırlığa (c.a.) aglepriston (Alizine, Virbac®) ile haftada iki gün üst üste 3 hafta boyunca ve bu tedaviye ek olarak cabergolin (Galastop, Ceva®) 5 µg/kg c.a. ile hergün günde 1 defa, per os (PO) birinci haftada uygulandı Üç hafta sonundaki muayenede, meme bezlerinde belirgin küçülme ve süt salgısının kesildiği saptandı. Tedavi başlangıcından 6 hafta sonra, meme bezlerinin tamamen küçüldüğü ve serum progesteron ve östradiol konsantrasyonlarının sırasıyla 0.142 ng/ml ve <5pg/ml olduğu saptandı. Süt salgısının mevcut olduğu bu tarz olgularda aglepriston (Alizine, Virbac®) ve cabergolinin (Galastop, Ceva®) beraber kullanımı ile başarılı sonuçlar alınabileceği belirlendi.

Anahtar Kelimeler: Fibroepitelyal hiperplazi, aglepriston, cabergolin

Introduction

Feline mammary fibroepithelial hyperplasia is defined as rapid, non-neoplastic proliferation of ductal epithelium and stroma of the mammary gland resulting in enlargement of one, several or all of the mammary glands (Allen, 1973). The condition usually develops in young queens (13 week old to 2 year old) at the time of puberty, during the first oestrus cycle, pregnancy or pseudopregnancy. It can also occur after the administration of exogenous progesterone containing compounds such as medroxyprogesterone acetate or megestrol acetate to spayed or intact male or female cats (Görlinger et al., 2002; Nak et al., 2004; Sontas et al., 2008; Wehrend et al., 2001).

Effected mammary glands of the cat with fibroepithelial mammary hyperplasia is reported to be soft, sharply limited, fluctuant and jelly consistency. It is also reported that some patients have erythematous, dark and necrotic areas on their skin of mammary glands. Anemic mucous membranes, fever, tachycardia, lethargia and anorexia can be seen as systemic effects of the disease (Loretti et al., 2004).

Fibroepithelial hyperplasia is mostly diagnosed by typical clinical findings such as swelling of the mammary glands without signs of inflammation. Although sonographic imaging of the effected mammary glands shows characteristic homogeneous and granular structures, it is suggested to examine the fine needle or excision biopsy specimens histopathologically (Vitasek and Dendisova, 2006; Wehrend et al., 2001).

In the cases of feline fibroepithelial hyperplasia, spontaneous and complete regression of the extended mammary glands are usually reported due to luteolysis, ovariectomy, ovariohysterectomy, spontaneous abort or parturition (Johnston et al., 2001; Keskin et al., 2008). Total or partial mastectomy is one of the choices among therapy options (Görlinger et al., 2002). Due to the presence of

progesterone receptors in fibroadenomatous tissue, a targeted endocrine therapy can be achieved by administration of progesterone receptor blockers. Researchers (Görlinger et al., 2002; Nak et al., 2004; Vitasek and Dendisova, 2006; Wehrend et al., 2001) have reported success in treatment using different antigestagen therapy schedules. Cabergoline which is used as antiprolactin has a direct effect on the pituitary gland. Administration of the drug at a dose of 5 µg/kg b.w./day, (PO) for 5 days, inhibits prolactin synthesis and undesirable lactation by the stimulation of dopaminergic D₂ receptors (Baştan et al., 1998; Keskin et al., 2008; Verstegen, 1998).

Case

A two-year old intact, tabby, female cat weighing 4 kg., was admitted to the clinic of the Department of Obstetrics and Gynaecology, Faculty of Veterinary Medicine, University of Istanbul with a history that showed signs of oestrus one month ago. At physical examination, the cat's body temperature, pulse and respiratory rates were within normal ranges. When inspected, an excessive swelling was covering all of the mammary glands of the cat (Figure 1) and when palpated they were at body temperature, jelly consistency, not attached to the abdominal wall, mobile, oedematous and non-painful. Mammary skin was tight and especially inguinal mammary gland lobes and teats were erythematous, swollen and milk was ejaculated by a slight pressure. Total hemogram parameters were within normal ranges, serum progesterone and oestradiol concentrations were measured as 2,96 ng/ml and <5 pg/ml respectively. Fibroepithelial mammary hyperplasia was diagnosed based on anamnesis, recent oestrus, typical clinical findings, ultrasonographic imaging, elevated serum progesterone concentration and histopathologic evaluation of the punch biopsy specimen (Figure 2).

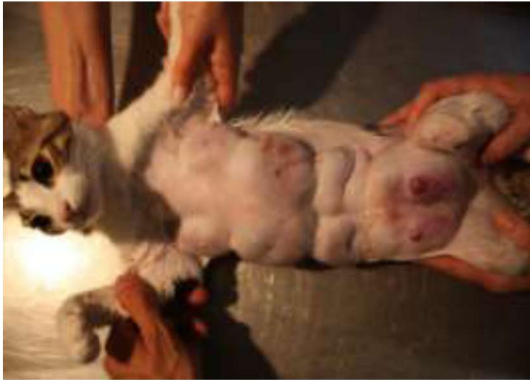

Figure 1: Mammary lobes on the presentation

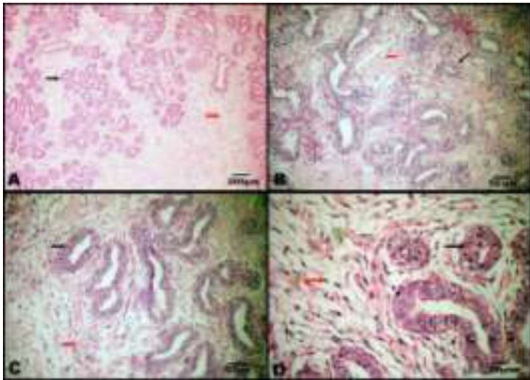


Figure 2. Histopathology of the mammary day glands
Black arrow: Active mammary gland,
Red arrow: Fibroadenomatous changes

The cat was treated with subcutaneous injections of aglepristone (Alizine, Virbac®) (15 mg/kg b.w.) on two consecutive days per week, for three weeks and 5 µg/kg b.w./day, per os cabergoline (Galastop, Ceva®) administration was accompanied to this treatment on the first week for seven days. Daily short term cold compressions were also applied.

Examination at the end of the third week revealed a marked regression of the mammary glands (Figure 3) parallel to the disappearance of the erythema and tightness of the mammary skin and milk secretion ceased. Due to the repeated oestrus behaviours observed in the third week, same treatment schedule was carried out for a further three weeks period in order to prevent possible progestative phase and proliferative response. Six weeks after the initiation of treatment mammary glands were completely regressed (Figure 4) and while total

hemogram parameters were within normal ranges, serum progesterone and oestradiol concentrations were 0.142 ng/ml and <5.0 pg/ml respectively. During the treatment period neither local nor systemic side effects related to aglepristone and cabergoline administrations was seen.



Figure 3: Mammary lobes at the end of the 3rd week

Discussion and Conclusion:

The two years old cat that brought to our clinic had oestrus one month ago and had local symptoms in its mammary lobes that belonged to feline fibroepithelial hyperplasia (Görlinger et al., 2002; Loretti et al., 2004; Wehrend et al., 2001). Bethlehem and Van der I (1993), defined fibroepithelial mammary hyperplasia as an enlargement of one or all mammary glands without milk production. However Görlinger et al. (2002), reported that feline fibroepithelial hyperplasia could also be observed during pseudopregnancy and usually occurred under the influence of endogenous progesterone, induced by ovulation. Growth hormone and prolactin are also reported to be effective in mammary gland evolution by Görlinger et al. (2002). Baştan et al. (2004) and Keskin et al. (2008) reported milk secretion in effected mammary glands of a cat with fibroepithelial mammary hyperplasia. As prolactin is responsible for morphological development of mammary glands, lactopoiesis and galactopoiesis (Arbeiter et al., 1998), Baştan et al. (1998) used cabergoline at a dosage of 5 µg/kg b.w./day, (PO) in 22 bitches having pseudopregnancy and found it safe and

practical for the regression of the mammary glands and the termination of undesirable lactation. Keskin et al. (2008) found cabergoline effective (5 µg/kg b.w./day for 14 days) to cease milk production in a pregnant queen having mammary hyperplasia. In this case cabergoline was accompanied to aglepristone treatment in order to prevent the undesirable lactation and help in the regression of the mammary glands. No side effects were observed in this case as well as Keskin et al. (2008) did not report any undesirable effect caused by the dosage of 5 µg/kg b.w./day cabergoline administration.



Figure 4: Mammary lobes at the end of the 6th week

Nak et al. (2004) treated a case of fibroadenomatous hyperplasia of the mammary gland in a queen with aglepristone at a dosage of 10 mg/kg b.w. on days 1, 2 and 7 and reported complete regression by day 21. Also Sontaş et al. (2008) and Wehrend et al. (2001) used aglepristone at a dosage of 10 mg/kg b.w. for 5 consecutive days which resulted in full recovery within 4 weeks. Görlinger et al. (2002), began aglepristone treatment on two consecutive days with a dose of 10 mg/kg b.w., once a week for 1-4 weeks but later they changed the treatment schedule as once a week at a dose of 20 mg/kg b.w. Within 1-4 weeks a total recovery in all treated 22 queens except one was reported.

Alternatively to the 10 mg/kg b.w. aglepristone administrations on 5 consecutive days or on the first, second and 7th. days in a week, we administered aglepristone by

increasing the dosage to 15 mg/kg b.w. on two consecutive days per week. This treatment schedule is found to be in line with the hypothesis of Görlinger et al. (2002) who finds the frequently repeated daily doses are unnecessary.

In this study milk secretion in the effected lobes ceased within three weeks and after the end of the sixth week the extension in all mammary lobes regressed totally by the treatment with aglepristone+cabergoline administration. These findings are in accordance with the results of the other researchers (Görlinger et al., 2002; Nak et al., 2004; Vitasek and Dendisova, 2006; Wehrend et al., 2001) who had success in the treatment of fibroepithelial mammary hyperplasia with antiprogesterins. The cat was followed up for six months period and no signs of reoccurrence were observed.

Although this report confirms the use of aglepristone in feline fibroepithelial hyperplasia as a reliable and effective treatment option, it demonstrates that successful results can be achieved by using aglepristone (Alizine, Virbac®) and cabergoline (Galastop, Ceva®) combinations, especially in cases with milk secretion.

REFERENCES

- Allen, H., 1973. Feline mammary hypertrophy. *Veterinary Pathology* 10, 501-508.
- Arbeiter, K., Brass, W., Ballabio, R., Jöchle, W., 1998. Treatment of pseudopregnancy in the bitch with cabergoline, an ergoline derivate. *Journal of Small Animal Practice* 29, 781-788.
- Baştan, A., Fındık, M., Erüenal, N., Aslan, S., Kılıçoğlu, Ç., 1998. The use of cabergoline for the treatment of pseudopregnancy in dogs with the purpose of suppressing lactation. *Reproduction in Domestic Animal* 33,49-53.
- Baştan, A., Özenç, E., Yağcı, İ.P., Beceriklisoy, H.B., 2004. Bir kedide meme hipertrofisi olgusu. *Ankara Üniversitesi Veteriner Fakültesi Dergisi* 51, 79-82.
- Bethlehem, M., Van der I, R.J.T., 1993. Feline fibroepitheliale hyperplasie bij drie gecasteerde katers na behandeling met progestativa. *Tijdschr Diergeneeskd.* 118, 650-652.

- Görlinger, S., Kooistra, H.S., Van den Broek, A., Okkens, A.C., 2002.** Treatment of fibroadenomatous hyperplasia in cats with aglepristone. *Journal of Veterinary Internal Medicine* 16, 710-713.
- Johnston, S.D., Kustritz, M.V.R., Olson, P.N.S., 2001.** Mammary hypertrophy. In: Johnston, S.D., Kustritz, M.V.R., Olson, P.N.S. (Eds.), *Canine and feline theriogenology*. Philadelphia, W.B. Saunders Company, pp. 474-477.
- Keskin, A., Yılmazbaş, G., Şimşek, G., İntaş, K.S., 2008.** Mammary hyperplasia in a pregnant queen. *Australian Veterinary Practitioner* 38, 75.
- Loretti, A.P., Ilha, M.R.S., Breitsameter, I., Faraca, C.S., 2004.** Clinical and pathological study of feline mammary fibroadenomatous change associated with depot medroxyprogesterone acetate therapy. *Arquivo Brasileiro de Medicina Veterinariae Zootecnia*. 56(2), 270-274.
- Nak, D., Nak, Y., İntaş, K.S., Kumru, İ.H., 2004.** Treatment of feline mammary fibroadenomatous hyperplasia with aglepristone. *Australian Veterinary Practitioner* 34(4), 161-162.
- Sontas, B.H., Turna, Ö., Uçmak, M., Ekici, H., 2008.** What is your diagnosis. *Journal of Small Animal Practice* 49, 545-547.
- Verstegen, J.P., 1998.** Pharmacological control of reproduction in the cat. In: England, G., Harvey, M. (Eds.), *Manuel of small animal reproduction and neonatology*. BSAVA., U.K, pp. 219-226.
- Vitasek, R., Dendisova, H., 2006.** Treatment of feline fibroepithelial hyperplasia following a single injection of proligestone. *Acta Veterinaria Brno* 75, 295-297.
- Wehrend, A., Hospes, R., Gruber, A.D., 2001.** Treatment of feline fibroadenomatous hyperplasia with a progesterone antagonist. *Veterinary Record* 148, 346-347.