

## A Hemangiosarcoma Case in a Dog

Gamze KARABAĞLI<sup>1\*</sup>, Oktay DÜZGÜN<sup>1</sup>, Esmâ YILDAR<sup>1</sup>, Özge ERDOĞAN<sup>2</sup>, Aydın GÜREL<sup>2</sup>

<sup>1</sup>İ.Ü. Veteriner Fakültesi Cerrahi Anabilim Dalı, 34320, Avcılar, İSTANBUL

<sup>2</sup>İ.Ü. Veteriner Fakültesi Patoloji Anabilim Dalı, 34320, Avcılar, İSTANBUL

\*Corresponding Author: Gamze KARABAĞLI İstanbul Üniversitesi Veteriner Fakültesi Cerrahi Anabilim Dalı, 34320, Avcılar, İstanbul,  
e-mail: gamze.vet@gmail.com, Tel: +90 212 4737070-17304

**Geliş Tarihi /Received: 25.11.2010**

### SUMMARY

The material of this study is a 3.5 years old male Rottweiler dog presented to Istanbul University Veterinary Faculty Surgery Clinics with a complaint of swelling in the right shoulder region. A diagnosis of hematoma was made and treatment was performed, but swelling started to grow gradually and general well-being deteriorated. When the drain was controlled, drainage of fluid containing blood was observed. Anemia and leucocytosis was determined on examination of the blood. The patient was operated. The mass was observed to expand in the thoracic cavity and it was found that organs in that regions were disfunctioned. So the patient was considered to be inoperable and euthanasia was performed. Specimens taken were examined histopathologically by using streptavidin-biotin immunoperoxidase (IMP) method and a diagnosis of hemangiosarcoma of soft-tissue origin was made.

**Key Words:** Hemangiosarcoma, dog, histopathology

### ÖZET

#### BİR KÖPEKTE HEMANJİYOSARKOM OLGUSU

Bu çalışmanın materyalini, İstanbul Üniversitesi Veteriner Fakültesi Cerrahi Kliniği'ne sağ omuz bölgesinde şişkinlik şikayeti ile getirilen, 3,5 yaşında, erkek, rotweiler ırkı bir köpek oluşturdu. Daha önce hematom teşhisi konularak tedavi uygulaması yapılan hastada şişkinliğin giderek büyüme gösterdiği ve genel durumunun giderek kötüleştiği belirtildi. Yapılan direnç kontrol edildiğinde kan içeren sıvı akışı tespit edildi. Kan bulgularında; anemi ve lökositoz görüldü. Hasta operasyona alındı. Operasyonda kitlenin toraks boşluğunu sarması ve bölge organlarının disfonksiyona uğraması nedeni ile inoperable kabul edilip hasta ötenazi edildi. Alınan örnekler histopatolojik olarak ve streptavidin-biotin immunperoksidaz (IMP) yöntemi kullanılarak incelendi ve yumuşak doku kökenli Hemanjiyosarkom teşhisi konuldu.

**Anahtar Kelimeler:** Hemanjiyosarkom, köpek, histopatoloji

### Introduction

Hemangiosarcoma is a malignant tumor with high metastasis rates also known as angiosarcoma or hemangioendothelioma

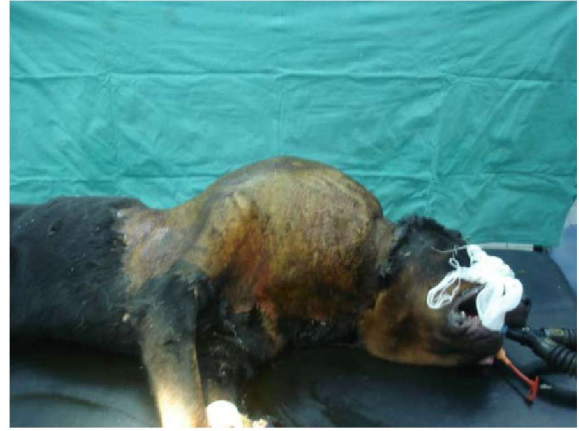originating from vascular endothelium (Douglas, 2007; Goldschmidt et al. 2002; Hidaka, 2006; Hilbe et al. 2002). Hemangiosarcoma is seen more frequently in

dogs compared to other animal species. It is predominantly reported in dogs of 9-10 years old. However, there are also publications reporting its presence in dogs under the age of three. German Shepherd dogs, Golden Retriever, Bernese Mountain dogs and Boxer dogs are among sensitive breeds (Bar-Am, 2006; Douglas, 2007; Vail, 2000). Hemangiosarcomas in dogs are aggressive and malignant tumors with poor prognosis (Bar-Am, 2006; Clifford, 2000; U'Ren, 2007). They are responsible of 12-21% of all mesenchymal tumors and 5% of all non-cutaneous primary malignant tumors in dogs. 2.3-3.6% of cutaneous tumors and 45-51% of splenic tumors in dogs are hemangiosarcomas. Although the etiology of hemangiosarcoma is unknown, thinning of hair and minimal pigmentation is found in laboratory dogs exposed to ultraviolet light (Brown, 1985; Douglas, 2007; Erdem, 2000; Hargis, 1992; Liapis, 2004; Mellanby, 2004; Ward, 2008). In the present study, the objective is to transfer clinical state and histopathologic examination of a case of hemangiosarcoma originating from soft-tissue found in a 3.5 years old Rottweiler dog to literature.

### Case Report

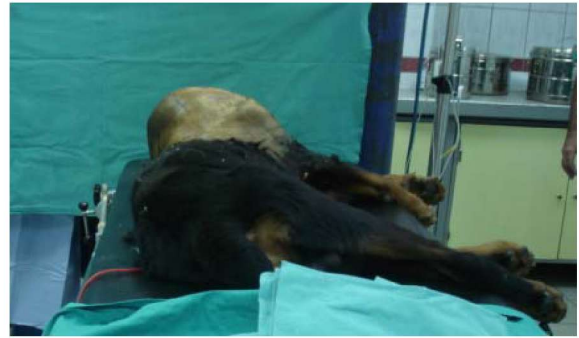Our case is a 3.5 years old, male, Rottweiler dog presented to Istanbul University Veterinary Faculty Surgery Clinics (presentation date: 09-25-2009, Protocol number: 2009003291) with gradually increasing swelling in the right shoulder joint and neck region despite therapy performed.

On examination a fluctuant mass about the size of a soccer ball was observed including the right shoulder and neck region (Figures 1, 2). It was reported that the general welfare of the patient gradually deteriorated and it could hardly walk. It was also reported that treatment of hematoma had been performed on the mass for 4 weeks. When the drain was controlled, drainage of fluid containing blood was observed. Anemia and leucocytosis was determined on examination of the blood. A date for operation was determined for extirpation of the mass or amputation of the extremity. Fol-



**Figure 1.** Swelling in the right shoulder joint and neck.

**Şekil 1.** Sağ omuz bölgesi ve boyunda şişkinlik.



**Figure 2.** Fluctuant mass about the size of a soccer ball was observed including the right shoulder and neck region.

**Şekil 2.** Sağ omuz ve boyun bölgesinde gözlemlenen yaklaşık futbol topu büyüklüğünde fluktan kitle.

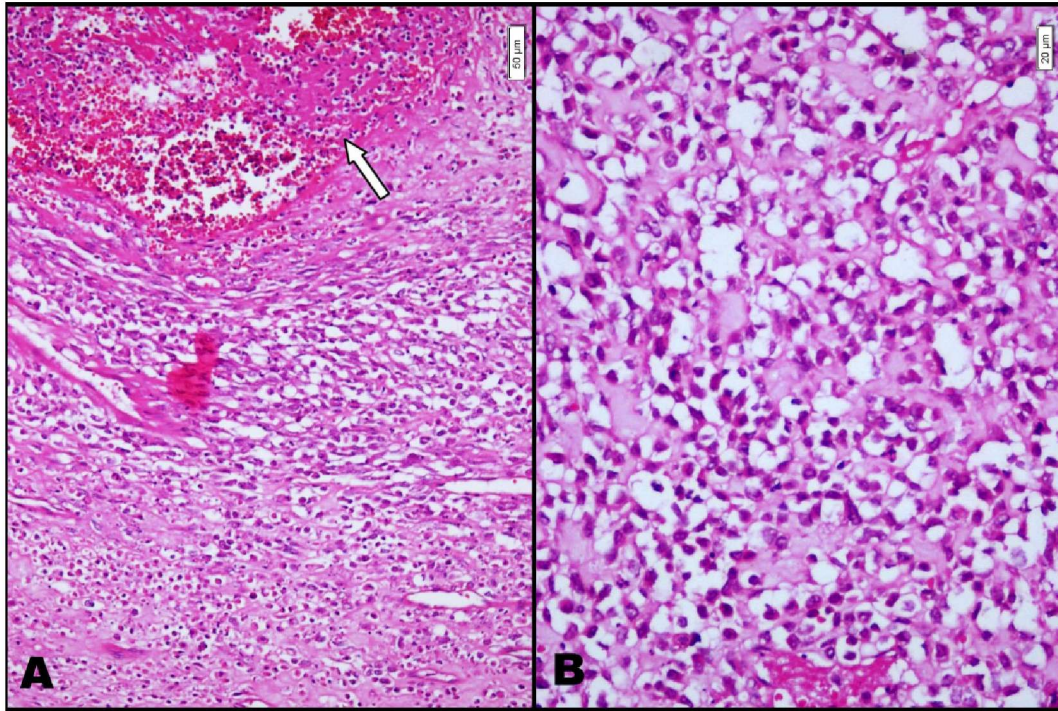
lowing anesthesia induction with 6 mg/kg propofol (IV 200 mg/20 ml, Pofol ® Sandoz) shaving and disinfection was completed. For general anesthesia Isoflurane (100 ml, Forane®, Abbott laboratuars) inhalation anesthesia was performed. Circumferential incision (melon slice) was performed on the mass and tissues were dissected. The mass was found to be connected to the thorax. It was decided that the mass could not be removed by operation. With the will of the owner euthanasia was performed. The red-brown soft mass with a size of 10 cm x 7 cm x 5 cm and grey areas on the section surface was fixed with 10% formaldehyde, treated with alcohol and xylol series and embedded into paraffin blocks. Sections of 5µ

thickness were taken and stained with Haematoxyline-Eosine. On microscopic examination of sections it was seen that endothelium-like cells with shapes changing from oval to fusiform and with vesicular nuclei and one or more nucleoli constricted cellular component. Many fissures, irregular capillaries and larger vascular structures, numerous typical and atypical mitoses, large necrosis areas, diffuse thromboses in the vessels and inflammatory cell infiltration were found (Figure 3). A diagnosis of hemangiosarcoma originating from soft-tissue was made and immunohistochemical labeling with the tumor marker Factor VIII (F-VIII) was performed on

sections using streptavidin-biotin immunoperoxidase method to confirm the diagnosis. Neoplastic cells thought to be originating from endothelial cells were determined by cytoplasmic F-VIII staining (Figure 4).

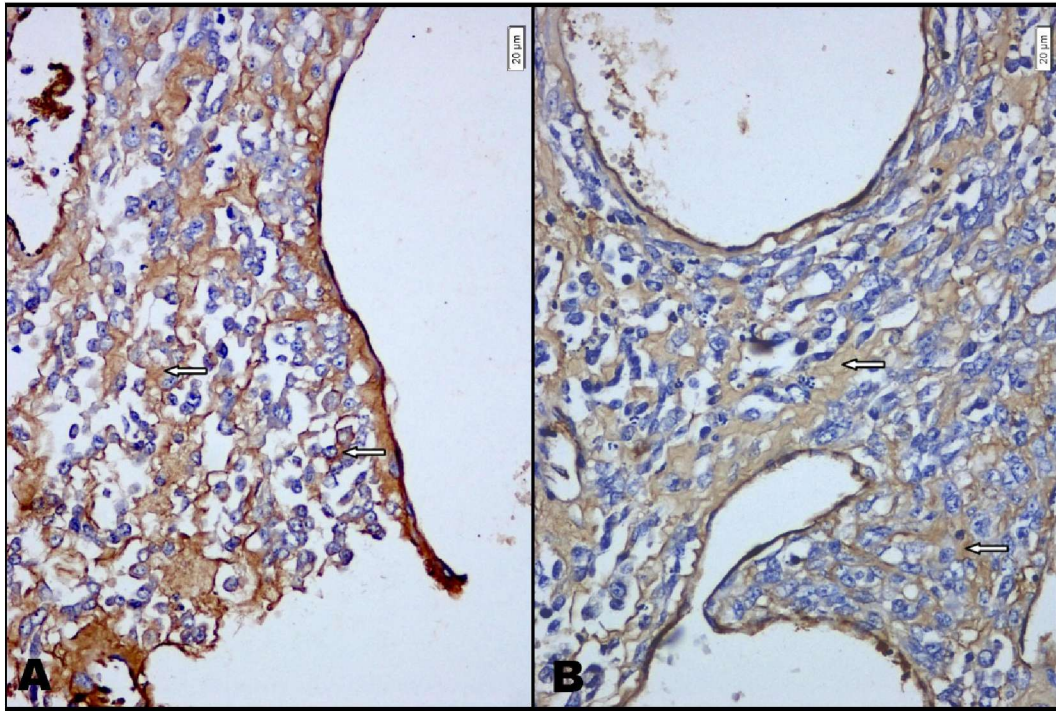
### Discussion and Conclusion

Hemangiosarcoma is a malignant tumor originating from vascular endothelial tissue (Bar-Am, 2006; Hidaka, 2006). Although hemangiosarcoma is mostly seen in middle-aged animals, publications reporting this tumor in dogs younger than 3 years old are compatible with our case.



**Figure 3.** A. Trombose in vein (arrow mark). B. Hemangiosarcoma, Hematoxylin-Eosin.

**Şekil 3.** A. Damarda tromboz (ok işareti). B. Hemanjiyosarkom, Hematoksilen-eozin boyama.



**Figure 4.** Hemangiosarcoma, F-VIII staining (IMP). intrastoplasmic F-VIII staining in tumor cells (arrow markers).  
**Şekil 4.** Hemanjiyosarkom F-VIII boyama (IMP) tümör hücrelerinde intrastoplazmik F-VIII boyama (ok işareti)

2.3-3.6% of cutaneous tumors in dogs are hemangiosarcoma. In a study performed in 104 dogs, 65 of the cases of hemangiosarcoma were reported to have developed in the spleen (62%), 18 in soft-tissue of the thorax and extremities (17%), 3 in the heart (3%), 3 in the long bones, 2 in the lung (2%), 1 in the bladder, 1 in the aorta and 1 in the prostate (4). Our case is in a large percentage segment (Douglas, 2007).

In dogs, hemangiosarcomas are metastatic tumors and rapidly lead to death (U-Ren, 2007). Metastasis occurs by transabdominal implantation or by hematogenous route rapidly. Hemangiosarcoma has been found in semimembraneous muscle histopathologically. Metastases are most frequently seen in the liver, omentum, mesenterium and lung (Bar-Am, 2006). The fact that the mass covered nearly the whole thoracic cavity in our case suggested that metastasis occurred rapidly by hematogenous route. It is compatible with the literatures.

Clear demonstration of hemangiosarcoma includes hematologic and biochemical laboratory findings, coagulation tests,

thoracoabdominal imaging, abdominosynthesis +/- or echography (Douglas, 2007). Hemotologic abnormalities have reported to include normocytic-normochromic anemia, thrombocytopenia, hemolysis, hypofibrinogenemia, prolongation of coagulation time (Bar-Am, 2006). The diagnosis of our case was evaluated biochemically-physiologically and histopathologically as far as possible and found to be compatible with the literatures.

Surgery and chemotherapy has limited succes for survival (Clifford, 2000). When immunotherapy and chemotherapy is combined, survival has been reported to prolong (U'Reni, 2007). Because of too many metastatic areas were present in our patient, treatment methods reported in the literature could not be performed.

Finally, hemangiosarcoma may occur in any region of the body. We believe that early diagnosis of the pathologic mass with biopsy and subsequently total extirpation of the mass would prolong survival and decrease possible function losses and pain to a minimal level.

#### REFERENCES

- Bar-Am, Y., 2006.** Femoral compartment syndrome due to haemangiosarcoma in the semimembranosus muscle in a dog. *Journal of Small Animal Practice* 47, 286-289.
- Brown, N.O., 1985.** Canine Hemangiosarcoma: retrospective analysis of 104 cases, *Journal of American Veterinary Medical* 186 (1), 56-8.
- Clifford, C.A., 2000.** Treatment of canine hemangiosarcoma: 2000 and beyond, *Journal of Veterinary Medicine* 14 (5), 479-85.
- Douglas, H. T., 2007.** Miscellaneous Tumors, *Small Animal Clinical Oncology* 4. Edition, Chapter 32, 785-792.
- Erdem, V., 2000.** Haemangiosarcoma of the scapula in three dogs. *Journal of Small Animal Practice* 41, (10), 461-4.
- Goldschmidt, M.H., Hendrick, M.J., 2002.** Tumors of the Skin and Soft Tissues. In: Meuten, D.J. (Ed), *Tumors in Domestic Animals*. 4th ed. Iowa State Pres, Iowa; 45-117.
- Hargis, A.M., 1992.** A retrospective clinicopathologic study of 212 dogs with cutaneous hemangiomas and hemangiosarcomas, *Veterinary Pathology* 29, 316-328.
- Hidaka, Y., 2006.** Primary hemangiosarcoma of the humerus in a Maltese dog. *The Journal of Veterinary Medical Science* 68 (8), 895-898.
- Hilbe, M., Hauser, B., Zilinszky, K., Ehrensperger, F., 2002.** Haemangiosarcoma with a metastasis of a malignant mixed mammary gland tumor in a dog. *Journal of American Veterinary Medical* 49, 443-444.
- Liapis, I.K., 2004.** Hemangiosarcoma of the third eyelid in a dog. *Veterinary Ophthalmology* 7, 4, 279-282.
- Mellanby, R.J., 2004.** Urethral haemangiosarcoma in a boxer, *Journal of Small Animal Practice* 45 (3), 154-6.
- U'Ren, L.W., 2007.** Evaluation of a novel tumor vaccine in dogs with hemangiosarcoma, *Journal of Veterinal Internal Medicine* 21 (1), 113-20.
- Ward, H., 2008.** Cutaneous Hemangiosarcoma in 25 Dogs: A Retrospective Study, *Journal of Veterinary Medicine* 8, 345-348.
- Vail, D.M., MacEwen, E.G., 2000.** Spontaneously occurring tumors of companion animals as models for human cancer. *Cancer Investigation* 18 (8), 781-792.