

Vaginal Leiomyosarcoma Subsequent to Pyometra in a Labrador Retriever Bitch

Sinem Özlem ENGİNLER^{1}, Uğur SİĞİRCİ², Seçkin Serdar ARUN², Hayri EKİCİ¹*

¹*Department of Obstetrics and Gynaecology, Faculty of Veterinary Medicine, University of Istanbul, 34320, Avcılar, Istanbul, Turkey.*

²*Department of Pathology, Faculty of Veterinary Medicine, University of Istanbul, 34320, Avcılar, Istanbul, Turkey*

**Corresponding Author: Sinem Özlem ENGİNLER Department of Obstetrics and Gynaecology, Faculty of Veterinary Medicine, University of Istanbul, 34320, Avcılar, Istanbul, Turkey
e-mail: soapaydin@hotmail.com*

Geliş Tarihi / Received: 03.10.2012

ABSTRACT

In this case, vaginal leiomyosarcoma subsequent to pyometra is described in a 10-year old Labrador Retriever bitch. Bloody, malodorous discharge related to pyometra was present from the vagina for 4 months. Ovariohysterectomy recommended but the owner refused the operation. Three weeks after the first examination a rapidly growing mass and a bulge were noticed in the vagina. The dog underwent ovariohysterectomy and a biopsy was taken from the mass at the vagina during this surgery and submitted to pathology laboratory. It was diagnosed as leiomyosarcoma in histopathological and immunohistochemical examinations. After the mass extirpated surgically the recurrence was occurred in one and a half months later. The bitch's general condition deteriorated rapidly and she died. Because of the late arrival of the patient to our clinic and in order to the request of the owner, treatment protocols could not be able to applied properly so the case was failed. The aim of this case is to transfer the surgical approaches to these kinds of reproductive pathologies to the literature. It is concluded that these kinds of pathologies should be treated immediately.

Key Words: Bitch, leiomyosarcoma, vagina, pyometra

ÖZET

BİR DİŞİ LABRADOR KÖPEKTE PYOMETRAYI TAKİBEN GÖRÜLEN VAGİNAL LEİOMYOSARKOMA

Bu olguda 10 yaşlı Labrador dişi bir köpekte pyometrayı takiben görülen vaginal leiomyosarkoma anlatıldı. Köpekte 4 aydır devam eden pyometraya bağlı kanlı, pis kokulu vaginal akıntı vardı. Köpeğe ovariohisterektomi önerildi fakat hasta sahibi bu öneriyi reddetti. İlk muayeneden 3 hafta sonra hızlıca büyüyen, çıkıntı yapan bir kitle vaginada fark edildi. Köpeğe ovariohisterektomi yapıldı ve bu esnada vaginadaki kitleden de biyopsi alınarak patoloji laboratuvarına yollandı. Histopatolojik ve immunohistokimyasal değerlendirme sonucunda kitle leiomyosarkoma olarak saptandı. Kitlenin ameliyatla uzaklaştırılmasından 1,5 ay sonra nüks gözlemlendi. Köpeğin genel durumu hızlıca kötüledi. Köpeğin kliniğimize geç getirilmesinden ve hasta sahibinin isteği doğrultusunda, tedavi protokollerinin düzenli olarak uygulanamamasından dolayı köpeği kaybettik. Bu olgunun amacı bu tarz reproduktif patolojilerin cerrahi yaklaşımlarının yazına aktarılmasıdır. Sonuç olarak, bu tarz patolojilerin hızlıca tedavi edilmesi gerekliliği saptandı.

Anahtar Kelimeler: Dişi köpek, leiomyosarkoma, vagina, pyometra

Introduction

Canine pyometra is defined as a disease of the uterus in intact bitches after 4 weeks to 4 months subsequent to estrus with vaginal discharge (open cervix pyometra) or without vaginal discharge (closed cervix pyometra) (Smith, 2006). Vaginal discharge can be purulent, sanguinopurulent, mucoid or severe frank hemorrhage (Smith, 2006). The average age of onset of the pyometra is 9.36 ± 0.35 years (Smith, 2006).

Ferreira and Pinto (2008), reported that the most common vaginal neoplasms are leiomyoma and fibroma in old dogs. It has been reported that smooth muscle tumours (leiomyoma and leiomyosarcoma) are observed rarely in domestic animals, most of them are benign and leiomyosarcoma represents 10% of all the smooth muscle tumours (Hulland, 1990). Tumours in vagina or vulva are generally rare in dogs (Thacher and Bradley, 1983). Cooper and Valentina (2002), reported almost all cases of genital leiomyosarcomas in females, mostly in intact females. Leiomyomas must be discerned from leiomyosarcomas from a histological viewpoint (Yeruham et al., 1999). Leiomyosarcomas may represent infiltrative growth within the vaginal or uterine wall and can invade to the pelvic canal. Areas of necrosis can be common (Cooper and Valentine, 2002). Splenic metastasis was reported in a dog (Cooper and Valentine, 2002). Genital leiomyosarcomas were reported in the vaginae of pregnant women and pregnant dairy cattle, uterus and cervix of goats, uteruses of sheep, vagina and vulva of bitches, and in the vulva of cats (Behzatoğlu et al., 2003; Cooper and Valentine, 2002; Firat et al., 2007; Hossein et al., 2009; Vemireddi et al., 2007; Whitney et al., 2000).

The aim of this case report is to transfer the surgical approaches of vaginal leiomyosarcoma and pyometra to the literature.

Case

A 10-years-old, 26 kg Labrador Retriever bitch was referred to Faculty of Veterinary Medicine Department of Obstetrics and

Gynaecology in Istanbul University with the complaint of bloody, malodorous discharge from the vagina for 4 months. According to the signalement, history and the vaginal examination, pyometra was diagnosed (Figure 1). At the physical examination, she was lethargic and weak. At the blood evaluation the bitch showed anaemia and leukocytosis that might be due to uterine infection (Table 1). Although, ovariohysterectomy recommended immediately the owner refused the operation. Three weeks after the examination, rapidly growing mass bulging from vagina (Figure 2) and constant licking of the vulva added to the complaint.

Table 1. The blood profile of the bitch at the first examination.

Tablo 1. Köpeğin ilk muayenedeki kan profili.

Test	Results	Reference Range
HCT	24,2 %	37.0-55.0
HGB	8.0 g/dL	12.0-18.0
MCHC	33.1 g/dL	30.0-36.9
WBC	$22.2 \times 10^9/L$	6.0-16.9
GRANS	$16.4 \times 10^9/L$	3.3-12.0
GRANS%	74%	
L/M	$5.8 \times 10^9/L$	1.1-6.3
L/M%	26%	
PLT	$1130 \times 10^9/L$	175-500

Anesthesia inducted with an iv administration of 6 mg/kg propofol (Pofol; İlsan Hexal, 20 ml/ampul) and maintained with inhalation of 3-4 % isoflurane (Forane; Abbott, 100 ml/flc.) + oxygen. The same anesthesia protocol was used in both of the operations.

Ovariohysterectomy was performed to the bitch and a biopsy from the mass at the vagina was submitted to pathology laboratory at the same surgery. After ovariohysterectomy, macroscopically pus accumulation was detected in the horns of the uterus and thickening of the endometrial wall was detected. Postoperatively, 20 mg/kg Ceftriaxone disodium (Novosef; Eczacıbaşı, 1 gr/flc.) im, ½ ampul B-complex and C vitamin (Epargriseovit; Deva) im, 10-20

ml/kg/day Dextrane 70 (Macrodex; Eczacıbaşı Baxter, 500 ml/iv infusion) iv were prescribed to the bitch for a week.

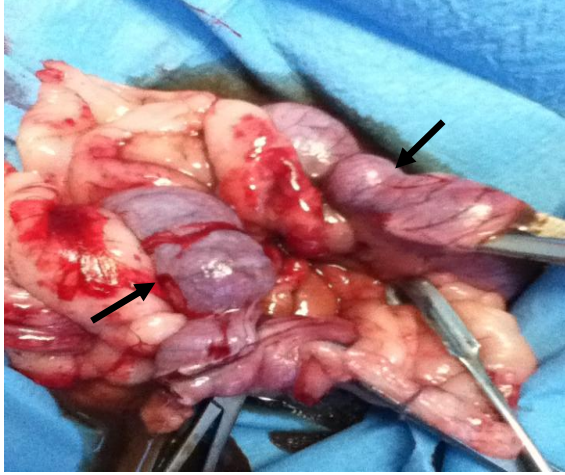


Figure 1. Pyometra was diagnosed and ovariohysterectomy was performed on the bitch. Black arrows show the dilated uterine horns related to pus accumulation.

Şekil 1. Köpekte pyometra teşhis edildi ve köpeğin kısırlaştırılması yapıldı. Siyah oklar irin birikimine bağlı olarak genişlemiş uterus kornularını gösteriyor.

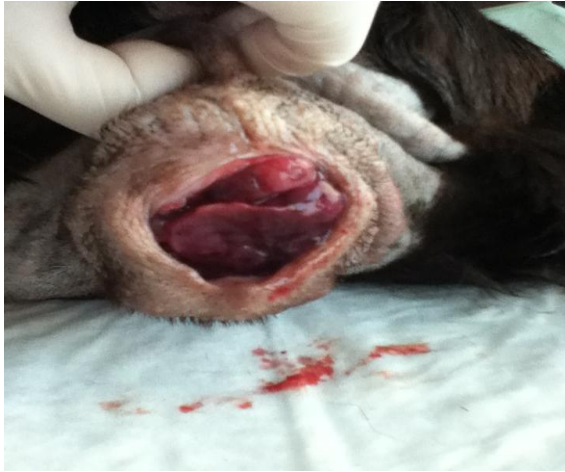

Figure 2. A mass arising from the vagina and hanging from the vulva.

Şekil 2. Vulvadadan sarkan ve vaginadan köken alan kitle.

Ten days later, at the histopathological examination biopsy material was diagnosed as leiomyosarcoma. Due to the good general condition of the bitch, the vaginal mass was extirpated surgically. The bitch was positioned

on her back. An episiotomy was performed to the dorsal commissure of the vulva. The mass was easily visualized and measured as 7.4x6.4 cm, it was rough, dark pink in color and amorphous. There were ulcerative and hemorrhagic foci on the surface of the mass. It was not solid when touched it was rupturing. The urethral orifice was closed by the mass and a catheter was placed in the urethra to aid in defining and avoiding trauma to this structure during the surgery. After the ligation of the vessels, the mass was excised by using electrocauterization. Firstly the stalk of the tumour extirpated by electro-cauterization to avoid bleeding. The mass was fully extirpated which was originated from the vaginal wall. Following the removal of the mass totally, the operation site was controlled for bleeding and if bleeding noticed, it was controlled by electrocauterization and stitches. Closure of the excision site was achieved by simple suture pattern of 3/0 chromic catgut. The episiotomy site was closed routinely. After the operation an Elizabethan collar was placed to the bitch in order to avoid destroying the stitches. Enrofloxacin (Baytril-K; Bayer, 20 ml/flc.) 5 mg/kg/day sc, B complex and C vitamin (Epargriseovit; Deva) ½ ampul im were administered to the bitch for 7 days postoperatively. Ten days later the blood profile was detected normal so, chemotherapy was performed with doxorubicine HCl (Adriblastina; Deva, 10 mg/flk.) at a 30 mg/m² dose to the bitch for to avoid recurrence of the mass. But the owner did not permit for the other chemotherapy administrations so the recurrence was seen one and a half months later postoperatively. The bitch's general condition deteriorated rapidly and she died. The owner did not permit a necropsy.

The specimen that was presented to the Department of Pathology was initially fixed in 10% formalin solution, routinely processed and then stained with hematoxylin and eosin (H&E) and evaluated under light microscopy. Immunohistochemistry (IHC) was performed on paraffin sections according to the avidin-biotin-peroxidase complex method using mouse antibodies alpha smooth muscle actin

(A0002—IFU-IVD, Scytek Laboratories, Logan), mouse desmin Ab-1 (MS-376- S0, Neomarkers, Fremont, CA) and mouse myoglobin A00066—IFU, Scytek Laboratories, Logan). ABC staining kit was used for labeling and the reaction product was visualized with 3.3.9-diaminobenzidine chromagen (Histostain-Kit, Invitrogen, Camarillo, CA) and the sections were counterstained with 0.1% hematoxylin (Labvision Corporation, Fremont, CA), dehydrated and mounted.

Histologically, the mass was encapsulated and poorly demarcated at the surgical border, with variable cellularity ranging from densely packed spindle cells arranged in interwoven short fascicles to loosely spaced spindle cells separated by amorphous matrix (Figure 3-1). Cellular tumour composed of fascicles of spindle cells with eosinophilic cytoplasm and atypical cigar-shaped nuclei (Figure 3-1). There was moderate to marked nuclear atypia present, with frequent karyomegaly (Figure 3-1). Tumour giant cells were observed in some areas (Figure 3-2). The mitotic index ranged from 1 to 5 per high power field, with an average of 1 per 400 high power field (HPF). It was histopathologically concluded that the entity is a leiomyosarcoma. As the neoplastic cells were positive for desmin (Figure 3-3), smooth muscle actin (Figure 3-4) it was confirmed as a leiomyosarcoma also from an immunohistochemical viewpoint.

Discussion

As seen in this case treatment involves primarily surgical excision of the mass. Enginler et al., (2011) reported no ulcerative region and hemorrhage on the surface of the mass in their case report about vaginal leiomyosarcoma in a Holstein cow, however, vulvar and vaginal leiomyosarcomas may be extensively ulcerated (Cooper and Valentine, 2002) as in this case.

Thatcher and Bradley (1983), reported in their retrospective study 10 bitches out of 99 were detected as leiomyosarcoma and only one occurred in a spayed female, in this case the bitch was also intact when the condition occurred.

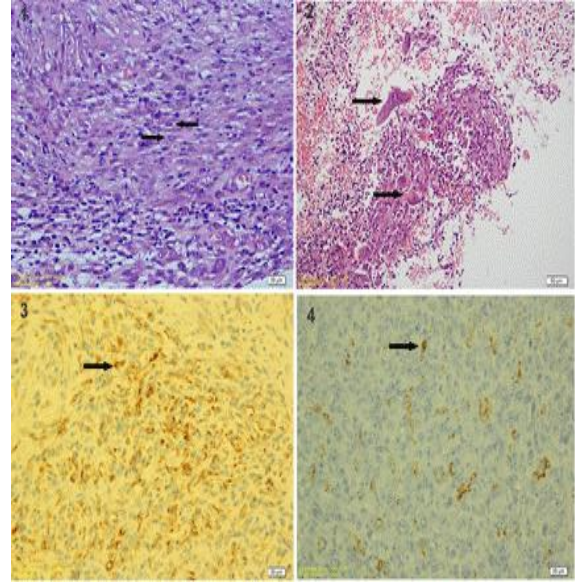


Figure 3. Histologic section shows a cellular neoplasm composed of spindle-shaped cells with fusiform and cigarshapped (left arrow) and atypical nucleus (right arrow) (1). Histologic section shows multinucleated giant cells (arrows) (2). Intracytoplasmic Desmin-positive areas in the tissue (arrow) (3). Intracytoplasmic Smooth Muscle Actin-positive areas in the tissue (arrow) (4).

Şekil 3. Histolojik kesitler mekik şekilli hücrelerle beraber iğ şeklinde puro benzeri hücrelerden oluşan hücresel neoplazmayı (sol ok) ve atipik çekirdeği (sağ ok) gösteriyor (1). Histolojik kesitler çok çekirdekli dev hücreleri (oklar) gösteriyor (2). Dokuda intrasitoplazmik dezmin-pozitif alanlar (ok) (3). Dokuda intrasitoplazmik düz kas aktin-pozitif alanlar (4).

Thatcher and Bradley (1983), reported in their retrospective study that one dog with leiomyosarcoma euthanized 1 month after the surgery because of the persistence of the signs, in this case the recurrence was seen one and a half months later postoperatively.

There is no apparent breed predisposition in dogs (Cooper and Valentine, 2002). In this case, the bitch was a Labrador retriever.

Miller et al. (2003) reported a uterine leiomyosarcoma accompanied by pyometra and nodules throughout uterus in the cat. But we could not evaluate the relation between pyometra and vaginal leiomyosarcoma in this case.

Surgical excision is considered to be the most common type of treatment for leiomyosarcomas in bitches. Chemotherapy can be used for additional therapy in such cases too.

Smooth muscle tumours can be diagnosed histopathologically and immunohistochemically with histogenesis markers. They can demonstrate histological and immunohistochemical features with other mesenchymal tumours, as fibrosarcoma or poorly differentiated tumours (Tsioli et al., 2011). Tsioli et. al. (2011) used intracytoplasmic smooth muscle actin reaction for immunohistochemistry in their case about uterine leiomyosarcoma and pyometra in a dog. In this case, for to diagnose the tumour type; intracytoplasmic smooth muscle actin reaction for immunohistochemistry was used too.

In conclusion, the aim of this case is to transfer the surgical approaches to these kinds of pathologies to the literature.

REFERENCES

- Behzatoğlu, K., Bahadır, B., Inhan, G., Altug, M., 2003.** Primary vaginal leiomyosarcoma in pregnancy. *Gynecologic Oncology* 91, 627-629.
- Cooper, B.J., Valentine, B.A., 2002.** Tumours of Muscle. In: Meuten, D.J. (Ed), *Tumours in Domestic Animals*. Blackwell Publishing Company, USA, pp. 319-363.
- Enginler, S.O., Gündüz, M.C., Sabuncu, A., Senünver, A., Yıldız, F., Arun, S.S., 2011.** Vaginal leiomyosarcoma in A holstein cow. *Kafkas Üniversitesi Veteriner Fakültesi Dergisi* 17 (2), 325-327.
- Ferreira, M.I.C., Pinto, L.F., 2008.** Homeopathic treatment of vaginal leiomyoma in adog: case report. *International Journal of High Dilution Research* 7 (24), 152-158.
- Firat, I., Haktanır-Yatkin, D., Sontas, B.H., Ekici, H., 2007.** Vulvar leiomyosarcoma in a cat. *Journal of Feline Medicine and Surgery* 9, 435-438.
- Hosseini, N., Iraj, K., Bonyadian, M., 2009.** Vaginal leiomyosarcoma in a pregnant dairy cow. *Journal of Comparative Pathology* 141 (4), 301.
- Hulland, T.J., 1990.** Tumours of the muscle. In: Moulton, J. E. (Ed.): *Tumours of domestic animals*, University of California Press, Berkeley, pp. 75-88,
- Miller, M.A., Ramos-Vara, J.A., Dickerson, M.F., Johnson, G.C., Pace, L.W., Kreeger, J.M., Turnquist, S.E., Turk, J.R., 2003.** Uterine neoplasia in 13 cats. *Journal of Veterinary Diagnostic Investigation* 15, 515-522.
- Smith, F.O., 2006.** Canine Pyometra. *Theriogenology* 66, 610-612.
- Thacher, C., Bradley, R.L., 1983.** Vulvar and vaginal tumours in the dog. A retrospective study. *Journal of the American Veterinary Medical Association* 183, 690-692.
- Tsioli, V.G., Gouletsou, P.G., Loukopoulos, P., Zavlaris, M., Galatos, A.D., 2011.** Uterine leiomyosarcoma and pyometra in a dog. *Journal of Small Animal Practice* 52, 121-124.
- Vemireddi, V., Langohr, I.M., Thacker, H.L., 2007.** Polypoid uterine leiomyosarcomas in a sheep. *Journal of the Veterinary Diagnostic Investigation* 19, 309-312.
- Whitney, K.M., Valentine, B.A., Schlafer, D.H., 2000.** Caprine genital leiomyosarcoma. *Veterinary Pathology* 37, 89-94.
- Yeruham, I., Perl, S., Orgad, U., Yakobson, B., 1999.** Tumours of the vulva and vagina in cattle- A 10 - year survey. *The Veterinary Journal* 158, 237-239.