

Is there a relationship between lower lumbar disc herniation and multifidus muscle volume in postmenopausal women?

Ela Kaplan¹, Pınar Kırıcı²

¹ Adiyaman Training and Research Hospital,
Department of Radiology, Adiyaman, Turkey
² Adiyaman University Medicine Faculty,
Department of Obstetrics and Gynecology,
Adiyaman, Turkey

ORCID ID of the author(s)

EK: 0000-0001-5039-9070
PK: 0000-0001-7616-4181

Corresponding Author

Ela Kaplan
Adiyaman Training and Research Hospital,
Department of Radiology, Adiyaman, Turkey
E-mail: elakaplan15@gmail.com

Ethics Committee Approval

The Adiyaman University Non-Interventional
Research Ethics Committee approval was
obtained for the study (2021 / 04-13).
All procedures in this study involving human
participants were performed in accordance with
the 1964 Helsinki Declaration and its later
amendments.

Conflict of Interest

No conflict of interest was declared by the
authors.

Financial Disclosure

The authors declared that this study has received
no financial support.

Published

2021 May 15

Copyright © 2021 The Author(s)

Published by JOSAM

This is an open access article distributed under the terms of the Creative
Commons Attribution-NonCommercial-NoDerivatives License 4.0 (CC
BY-NC-ND 4.0) where it is permissible to download, share, remix,
transform, and build upon the work provided it is properly cited. The work
cannot be used commercially without permission from the journal.



Abstract

Background/Aim: Lumbar disc herniation (LDH) is the most common cause of low back pain. It can also cause radiculopathy, sciatica, loss of sensation and motor loss due to pressure on the nerve roots. The multifidus muscle protects the lumbar axis. The aim of this study is to investigate the relationship between volumetric measurements and the degree of atrophy in the multifidus muscles with LDH in postmenopausal women.

Methods: This case-control, retrospective study included 207 postmenopausal women with disc herniation on lumbar magnetic resonance imaging (MRI) and 183 reproductive period-premenopausal women with a mean age of 47.12 (10.07) years who were admitted to Adiyaman Training and Research Hospital between March 2020 and March 2021. LDH was detected at L4-L5 and L5-S1 levels on axial T2W lumbar MRI images. At these levels, the multifidus muscle volume was measured from the superior and inferior end plates of the vertebral bodies. The measurement of total volume was called multifidus total muscle volume (M-TMV), and the measurement made from the area without fat infiltration was called multifidus functional muscle volume (M-FMV). The M-TMV/FMV value was obtained to determine the degree of fat atrophy. Statistical analyses were performed, in which $P < 0.05$ was considered statistically significant.

Results: The mean age of women in postmenopausal period with L4-L5 and L5-S1 intervertebral disc degeneration was 66.27 (12.33) years (57-84 years). M-TMV and M-FMV values were significantly lower and M-TMV / FMV values were significantly higher in postmenopausal women compared to the control group ($P < 0.001$). In ROC analysis, the sensitivity and specificity of M-TMV / FMV above a cut-off value of 1.67 in diagnosing LDH at L4-L5 in postmenopausal women were 96.1%, and 73.7%, respectively, while the sensitivity and specificity of M-TMV / FMV above a cut-off value of 1.46 in diagnosing LDH at L5-S1 were 89.3%, and 71.4% ($P < 0.001$), respectively.

Conclusions: This study reveals that in patients suffering from LDH in the postmenopausal period, atrophy of the multifidus muscle has negative effects and volumetric measurements of these muscles can be diagnostic in determining the degree of LDH. While planning LDH treatment in postmenopausal women, muscle strengthening programs planned after MRI evaluation may be beneficial for reducing symptoms.

Keywords: Lumbar disc herniation, Multifidus muscle, Muscle degeneration, Fatty infiltration

Introduction

Lumbar disc herniation (LDH) is the most common cause of low back pain in adults. Disc herniation causes radicular pain, loss of sensation or motor weakness as a result of compression on ventral / dorsal nerve roots [1]. The most common levels of LDH are L4-L5, L5-S1 and more rarely, L3-4 [2]. Although the pathogenesis of disc herniation has not been determined precisely, anatomical causes are blamed [3, 4]. Physiologically, the bone and muscle structures of the spine can prevent damage and stenosis of the nerve roots by maintaining stability [5]. Primary muscles involved in the stabilization of the spine are abdominal muscles, psoas muscle and multifidus muscles. The most important muscle group that plays a role in providing local stabilization of the spine is the multifidus muscles, which constitute the largest back muscle group in the lumbosacral region [6, 7]. Multifidus muscles provide physiological lordosis and play a role in the equal distribution of pressure on the intervertebral discs by controlling the stability of the spine [8]. In previous studies, it has been shown that there is a relationship between pathologies such as disc degeneration, scoliosis, radiculopathy and multifidus muscle degeneration [9, 10]. In addition, radiological examinations revealed that degenerative changes in other paravertebral muscle groups and fatty atrophy in LDH patients are also common findings [11, 12].

Although it has been shown in recent studies that multifidus muscles are associated with LDH, there is no study examining age and menopausal status [13]. It has been stated that in the postmenopausal period, women may have more severe LDH than male patients of the same age due to a significant decrease in estrogen concentrations [14, 15]. However, there is no current study investigating the effect of the presence and degree of degeneration in the multifidus muscle on disc herniation in female patients in the postmenopausal period.

The aim of this study is to investigate the relationship between volumetric measurements and the degree of atrophy in the multifidus muscles with LDH in postmenopausal women.

Materials and methods

Patient characteristics

There were 12873 women in the postmenopausal period who visited the gynecology outpatient clinic between March 2020 and March 2021. The age and clinical information of the patients were obtained from the hospital database KARMED. A total 532 patients low back pain complaints who underwent lumbar MRI were identified. Of these patients, 325 patients with motion artifacts on lumbar MRIs, kyphosis in the lumbar axis and / or scoliosis were excluded from the study. After the implementation of these criteria, 207 patients were included. Ethics approval was obtained from Adiyaman University Non-Interventional Research Ethics Committee (2021 / 04-13). This study was carried out in accordance with the Declaration of Helsinki.

Inclusion criteria were being aged 55 years and above, having lumbar disc degeneration and herniation and unilateral or bilateral nerve root compression at L4-L5 and L5-S1 levels.

Having lumbar axis disorders such as spondylolisthesis (>3 mm) or scoliosis (>10), having undergone surgery for

reasons such as lumbar disc herniation, spinal stenosis, history of spinal neoplasm, previous spinal infection (spondylodiscitis, tuberculosis, brucellosis, etc.) or other malignancies constituted the exclusion criteria.

One hundred eighty-three women between the ages of 40-50 years in the reproductive-premenopausal period were included in our study as the control group.

Imaging parameters

Lumbar MRI images were obtained in supine position using a 1.5-T MRI scanner (Gyrosan Intera, Philips Medical Systems, Best, The Netherlands). Imaging parameters were as follows: In sagittal T2-weighted images from T12 to sacrum, TR / TE 2980 / 122.6, matrix, size: 208 x 320, recovery time: 3,000--3,600 ms, echo time: 87--114 ms and slice thickness: 4 mm). In axial T2-weighted images from T12 to S1, TR / TE 2980 / 122.6, matrix size 208 x 320, recovery time: 3,000--3,600 ms, echo time: 87--114 ms, and slice thickness: 4 mm.

Evaluation of disc herniation

The degree of intervertebral disc herniation was determined by sagittal T2W images, and grade 2 and grade 3 patients were included in the study [16].

Evaluation of muscle degeneration

Multifidus muscle was evaluated from axial T2W images. Fatty infiltration involving <10% of normal muscle tissue was considered Grade 1 atrophy, fatty infiltration between 10-50% of normal muscle tissue was considered Grade II atrophy and severe irregular diffuse fatty infiltration (>50% fat infiltration in normal muscle tissue) was considered Grade III atrophy [17].

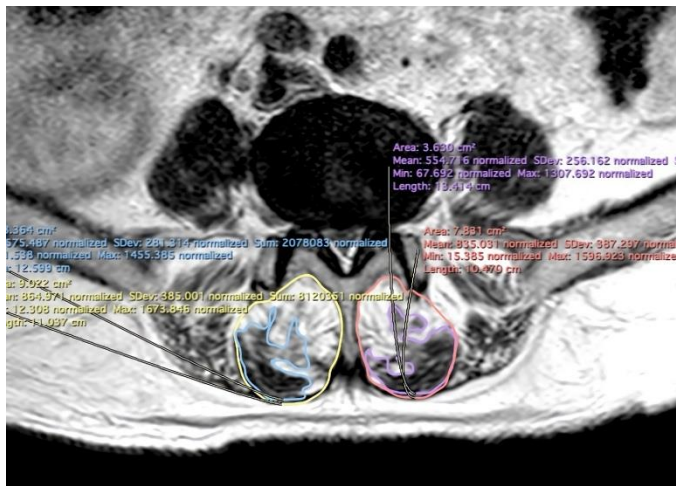
Paraspinal muscle measurements

Images were obtained from KARMED imaging system in DICOM format. Axial and sagittal T2W images were processed using the Horos operating system. The degree of degeneration was detected from sagittal T2W images. Measurements were made at the level of the superior and inferior endplates of the L5 vertebra from the axial T2A sections at the level of disc herniation in those with L4-L5 LDH, and at the level of the superior and inferior endplates of the S1 vertebra at the level of disc herniation in those with L5-S1 LDH. First, the total muscle volume (TMV) of the muscles was measured by hand drawing (Figure 1). Then, the functional muscle volume (FMV), excluding fat infiltration, was measured. FMV/TMV value was calculated to determine the degree of fat infiltration. The total value was obtained by calculating each value separately as right and left. The data obtained for L4-L5 and L5-S1 levels were collected, and the volumetric measurements were made.

Statistical analysis

Statistical analyses were performed using SPSS 22 (International Business Machines Corp., Armonk, New York). Kolmogorov-Smirnov test was used to evaluate normality assumption. Mann Whitney U test was used to compare non-normally distributed independent groups, and ROC analysis was performed to evaluate the diagnostic effectiveness of M-TMV, M-FMV and M-TMV/M-FMV in LDH. Binary logistic regression analysis was used to assess the relationship between LDH, fatty atrophy degree and M-TMV, P-TMV, M-FMV, T-FMV values. A *P*-value <0.05 was considered significant.

Figure 1: Multifidus muscle volume measurements on T2 weighted axial images



Results

In the postmenopausal period, the mean age of women with intervertebral disc degeneration at L4-L5 and L5-S1 levels was 66.27 (12.33) years (57-84 years). The mean age of patients in the control group was 47.12 (10.07) years (40-49 years).

When compared with the control group, the M-TMV, M-FMV values of postmenopausal women had significantly decreased and M-TMV / FMV ratio had significantly increased at both LDH levels ($P < 0.001$) (Table 1).

Table 1: Comparison of postmenopausal women with lumbar disc herniation and control group multifidus muscle volumes

		Groups		P-value
		Control Group	Postmenopausal women	
L4-L5	M-TMV	1092.2 (139.4)	788.7 (99.3)	<0.001
	M-FMV	917.9 (104.7)	433.2 (89.1)	<0.001
	M-TMV/FMV	1.18 (0.07)	1.82 (0.23)	<0.001
L5-S1	M-TMV	1157.4 (212.3)	871.3 (103.2)	<0.001
	M-FMV	1089.3 (121.9)	539.9 (92.7)	<0.001
	M-TMV/FMV	1.06 (0.07)	1.61 (0.17)	<0.001

M-TMV: Multifidus-Total muscle volume; M-FMV: Multifidus functional muscle volume; M-TMV/FMV: Multifidus total muscle volume/functional muscle volume

ROC analysis was performed to determine the effectiveness of M-TMV, M-FMV values and M-TMV/FMV ratio in diagnosing LDH in postmenopausal women. M-TMV / FMV values were strongly diagnostic for LDH at L4-L5 and L5-S1 levels ($P < 0.001$): The sensitivity and specificity of M-TMV / FMV above a cut-off value of 1.67 in diagnosing LDH at L4-L5 in postmenopausal women were 96.1%, and 73.7%, respectively, while the sensitivity and specificity of M-TMV / FMV above a cut-off value of 1.46 in diagnosing LDH at L5-S1 were 89.3%, and 71.4% ($P < 0.001$), respectively (Table 2) (Figure 2).

Table 2: Visibility results and cut off values of multifidus muscle volume measurements

	AUC	P-value	Cut-off	Sensitivity	Specificity
M-TMV/FMV (L4-L5)	0.883	<0.001	1.67	96.1	73.7
M-TMV/FMV (L5-S1)	0.872	<0.001	1.46	89.3	71.4

M-TMV/FMV: Multifidus total muscle volume/functional muscle volume, AUC: Area under curve

Binary logistic regression analysis was performed to analyze the correlation between LDH, age, fatty atrophy degree, and M-TMV, M-FMV, M-TMV / FMV values in the postmenopausal period. All these factors increased the risk of LDH in postmenopausal women ($P < 0.001$ for each). Among them, M-TMV / FMV value increased the LDH risk by 3.9 in postmenopausal women, while the degree of fatty infiltration doubled it (Table 3).

Table 3: Multivariate Logistic Regression Analysis

	B	P-value	Exp(B)	95% CI	
				Lower	Upper
Age	1.394	<0.001	3.42	2.12	7.89
Fatty infiltration grade	1.034	<0.001	3.008	2.512	4.328
M-TMV	-0.703	<0.001	2.312	1.212	3.211
M-FMV	-1.682	<0.001	4.237	2.832	9.183
M-TMV/FMV	3.921	<0.001	8.451	5.291	11.430

M-TMV: Multifidus-Total muscle volume, M-FMV: Multifidus functional muscle volume, M-TMV/FMV: Multifidus total muscle volume/functional muscle volume

Discussion

The results of this study show that lumbar disc herniation may occur due to a decrease in functional muscle in the multifidus muscles, and fatty atrophy is a risk factor for LDH in postmenopausal women. This finding supports other studies investigating the relationship of lumbar disc degeneration with the multifidus muscles [11, 17].

The compression in the nerve root causes denervation and atrophy due to structural changes in the lumbar multifidus muscles [18]. The multifidus muscle plays an important role in protecting the lumbar lordosis and the intervertebral discs by preventing movements such as sudden flexion. It does this by not only providing the necessary muscle strength for stabilization, but also by contributing to the nucleus pulposus and anulus fibrosus in the disc structure [19]. It also supplies support by reducing the pressure in the intervertebral disc at the L5-S1 segment. Restricting daily movements and reducing use is a common trend in patients suffering from LDH. This may result in atrophy due to reduced denervation of the muscles. The innervation of the multifidus muscle occurs through the medial branch of the dorsal ramus of the L5 nerve root. Denervation occurs with stenosis due to LDH in this nerve [18]. In the light of this information, it is not coincidental that there is a decrease in the total volume and functional volume in the multifidus muscle in postmenopausal female patients in our study, and these atrophic changes may have caused LDH at the L4-L5 and L5-S1 levels and secondary nerve root compression.

In a previous study, the degree of degeneration in the multifidus muscle was associated with disc degeneration [20]. The volume of multifidus in women with LDH was significantly different compared to the control group. In addition, the decrease in the functional volume of the multifidus muscle was highly diagnostic for determining LDH in postmenopausal women. To the best of our knowledge, this study is the first in which the cut-off value of the multifidus muscle volume can be determined to diagnose LDH.

This study reveals the relationship between the grade of fatty atrophic changes, which we distinguished visually, with LDH and shows that it is a reliable method in clinical evaluation. This result supports those of other studies in the literature [12, 21]. In another study, although the degree of multifidus fatty infiltration was superior to cross-sectional evaluation in patients with LDH [22], our study showed that cut-off values obtained in volumetric measurements provide superiority in diagnosis.

In previous studies, mild atrophic changes were found in the multifidus muscle after LDH surgery [23, 24]. However, weakness in the paraspinal muscles can be reversed with rehabilitation and exercise programs [25]. Choi et al. showed that lumbar extension strengthening exercises have positive effects on muscles after LDH surgery [26]. The main patient group included and investigated in our study are female patients in the

postmenopausal period. Preferring surgical treatment methods, especially in the elderly female patient group, may be difficult due to additional morbidities. According to the results of our study, it is thought that exercises and rehabilitation practices that strengthen the detected muscle groups may be beneficial. Therefore, MRIs to be performed before treatment may be useful in determining appropriate treatment methods.

Limitations

This study has some limitations. First, disc herniations at the lower levels (L4-L5 and L5-S1) were analyzed first. For this reason, evaluation of LDH at higher levels is limited. Second, our patients consisted of only postmenopausal women. This should be considered before applying our results to the general population. Another limitation of our study is that it is retrospective. Although derived from the hospital database, this may cause bias.

Conclusion

This study reveals that in patients suffering from LDH in the postmenopausal period, atrophy of the multifidus muscle has negative effects and volumetric measurements of these muscles can be diagnostic in determining the degree of LDH. While planning LDH treatment in postmenopausal women, muscle strengthening programs planned after MRI evaluation may be beneficial in reducing symptoms.

References

1. Benzakour T, Igoumenou V, Mavrogenis AF, Benzakour A. Current concepts for lumbar disc herniation. *Int Orthopaed*. 2019;43(4):841–51.
2. Sanderson SP, Houten J, Errico T, Forshaw D, Bauman J, Cooper PR. The unique characteristics of “upper” lumbar disc herniations. *Neurosurgery*. 2004;55(2):385–9.
3. Yüce I, Kahyaoglu O, Mertan P, Çavuşoğlu H, Aydın Y. Analysis of clinical characteristics and surgical results of upper lumbar disc herniations. *Neurochirurgie*. 2019;65(4):158–63.
4. Fortin M, Lazary A, Varga PP, McCall I, Battie MC. Paraspinal muscle asymmetry and fat infiltration in patients with symptomatic disc herniation. *Eur Spine J*. 2016;25(5):1452–9.
5. Cholewicki J, Panjabi MM, Khachatrian A. Stabilizing function of trunk flexor-extensor muscles around a neutral spine posture. *Spine (Phila Pa 1976)*. 1997;22(19):2207–12.
6. MacDonald DA, Moseley GL, Hodges PW. The lumbar multifidus: does the evidence support clinical beliefs? *Man Ther*. 2006;11(4):254–63.
7. Ward SR, Kim CW, Eng CM, Gottschalk LJ, Tomiya A, Garfin SR, et al. Architectural analysis and intraoperative measurements demonstrate the unique design of the multifidus muscle for lumbar spine stability. *J Bone Joint Surg Am*. 2009;91(1):176–85.
8. Macintosh JE, Bogduk N. The biomechanics of the lumbar multifidus. *Clin Biomech (Bristol Avon)*. 1986;1(4):205–13.
9. Freeman MD, Woodham MA, Woodham AW. The role of the lumbar multifidus in chronic low back pain: a review. *PM R*. 2010;2(2):142–6. Quiz 141 p following 167.
10. Mengiardi B, Schmid MR, Boos N, Pfirrmann CW, Brunner F, Elfering A, Hodler J. Fat content of lumbar paraspinal muscles in patients with chronic low back pain and in asymptomatic volunteers: quantification with MR spectroscopy. *Radiology*. 2006;240(3):786–92.
11. Colakoglu B, Alis D. Evaluation of lumbar multifidus muscle in patients with lumbar disc herniation: are complex quantitative MRI measurements needed? *J Int Med Res*. 2019;47(8):3590–600.
12. Altinkaya N, Cekinmez M. Lumbar multifidus muscle changes in unilateral lumbar disc herniation using magnetic resonance imaging. *Skeletal Radiol*. 2016;45(1):73–7.
13. Kalichman L, Carmeli E, Been E. The association between Imaging parameters of the paraspinal muscles, spinal degeneration, and low back pain. *Biomed Res Int*. 2017;2017:1–14.
14. Bailey A. Risk factors for low back pain in women: still more questions to be answered. *Menopause*. 2009;16:3–4.
15. Song XX, Yu YJ, Li XF, et al. Estrogen receptor expression in lumbar intervertebral disc of the elderly: gender- and degeneration degree-related variations. *Joint Bone Spine*. 2014;81:250–253.
16. Lee S, Lee JW, Yeom JS, Kim KJ, Kim HJ, Chung SK, Kang HS. A practical MRI grading system for lumbar foraminal stenosis. *AJR Am J Roentgenol*. 2010 Apr;194(4):1095–8. doi: 10.2214/AJR.09.2772. PMID: 20308517.
17. Ekin EE, Kurtul Yildiz H, Mutlu H. Age and sex-based distribution of lumbar multifidus muscle atrophy and coexistence of disc hernia: an MRI study of 2028 patients. *Diagn Interv Radiol*. 2016a;22(3):273–6.
18. Okada Y. Histochemical study on the atrophy of the quadriceps femoris muscle caused by knee joint injuries of rats. *Hiroshima J Med Sci*. 1989;38(1):13–21.
19. Kader DF, Wardlaw D, Smith FW. Correlation between the MRI changes in the lumbar multifidus muscles and leg pain. *Clin Radiol*. 2000;55(2):145–9.
20. Min SH, Kim MH, Seo JB, Lee JY, Lee DH. The quantitative analysis of back muscle degeneration after posterior lumbar fusion: comparison of minimally invasive and conventional open surgery. *Asian Spine J*. 2009;3(2):89–95.
21. Faur C, Patrascu JM, Haragus H, Anglitoiu B. Correlation between multifidus fatty atrophy and lumbar disc degeneration in low back pain. *BMC Musculoskelet Disord*. 2019;20(1):414.
22. Bouche KG, Vanovermeire O, Stevens VK, Coorevits PL, Caemaert JJ, Cambier DC, et al. Computed tomographic analysis of the quality of trunk muscles in asymptomatic and symptomatic lumbar discectomy patients. *BMC Musculoskelet Disord*. 2011;12:65.
23. Pourtaheri S, Issa K, Lord E, Ajiboye R, Drysch A, Hwang K, et al. Paraspinal muscle atrophy after lumbar spine surgery. *Orthopedics*. 2016;39(2):e209–e214.

24. Putzier M, Hartwig T, Hoff EK, Streitparth F, Strube P. Minimally invasive TLIF leads to increased muscle sparing of the multifidus muscle but not the longissimus muscle compared with conventional PLIF – a prospective randomized clinical trial. *Spine J*. 2016;16:811–9.
25. Oosterhuis T, Costa LO, Maher CG, de Vet HC, van Tulder MW, Ostelo RW. Rehabilitation after lumbar disc surgery. *Cochrane Database Syst Rev*. 2014;3:Cd003007.
26. Choi G, Raiturker PP, Kim MJ, Chung DJ, Chae YS, Lee SH. The effect of early isolated lumbar extension exercise program for patients with herniated disc undergoing lumbar discectomy. *Neurosurgery*. 2005;57(4):764–72. discussion 764–772.

This paper has been checked for language accuracy by JOSAM editors.
The National Library of Medicine (NLM) citation style guide has been used in this paper.