

# Journal of Pediatric Sciences

Low Molecular Weight Heparin therapy during gestation:  
is it really innocent for both mother and fetus?

*Surhan M. Arda, Dilsad Demet Dereli, Huseyin Ilhan, Baran Tokar*

Journal of Pediatric Sciences; 2010; 6; e61

**How to cite this article:**

**Arda SM, Dereli DD, Ilhan H, Tokar B. Low Molecular Weight Heparin therapy during gestation: is it really innocent for both mother and fetus? Journal of Pediatric Sciences 2010;6:e61**

## CASE REPORT

## Low Molecular Weight Heparin therapy during gestation: is it really innocent for both mother and fetus?

*Surhan M. Arda, Dilsad Demet Dereli, Huseyin Ilhan, Baran Tokar*

### **Abstract:**

*The etiology of gastric perforation in newborn has not been described yet. It is a rare pathology and has been accepted mostly as spontaneously occurring. In this case report, we present a newborn who was admitted with hematemesis, hematochezia, abdominal distension and pneumoperitoneum at the abdominal x-ray. A gastric perforation was found at abdominal exploration. The symptoms, signs and our exploration findings support a strong possibility of association of low molecular weight heparin (LMWH) and the gastric perforation. LMWH treatment during the pregnancy may cause a massive gastric bleeding in baby so that gastric outlet obstruction with coagulum plug and perforation may occur secondarily.*

**Key words:** newborn, low molecular weight heparin, gastric perforation

**Received:** 20/12/2010; **Accepted:** 27/12/2010

### **Introduction**

Gastric perforation (GP) in neonates is described in 1826 for the first time and treated successfully in 1943. Although it seems to occur spontaneously, if there are some clues on why it occurs, those factors should be investigated. In this case report, we present a newborn with gastric perforation that has a strong possibility of association with low molecular weight heparin (LMWH).

### **Case Report**

A 3-day-old girl was referred to our department with hematemesis, hematochezia, abdominal distension and pneumoperitoneum at the abdominal x-ray (Figure 1). She was born at 39<sup>th</sup> week of gestation with 3100 gr of weight. It was third gestation of 19-year old mother who was suffering from Leiden mutation of factor 5 and had been treated with low molecular weight heparin (LMWH) during gestation because of tendency to thrombosis.

A day before applying to our clinic, the patient was admitted to another hospital with hematemesis, hematochezia and treated with fresh frozen plasma, suspension of erythrocytes and vitamin-K. The symptoms did not resolve with

**Arda SM, Dereli DD, Ilhan H, Tokar B**

*Eskisehir Osmangazi University, Faculty of Medicine,  
Department of Pediatric Surgery, Eskisehir Turkey*

**Corresponding Author: Surhan M. Arda, MD**

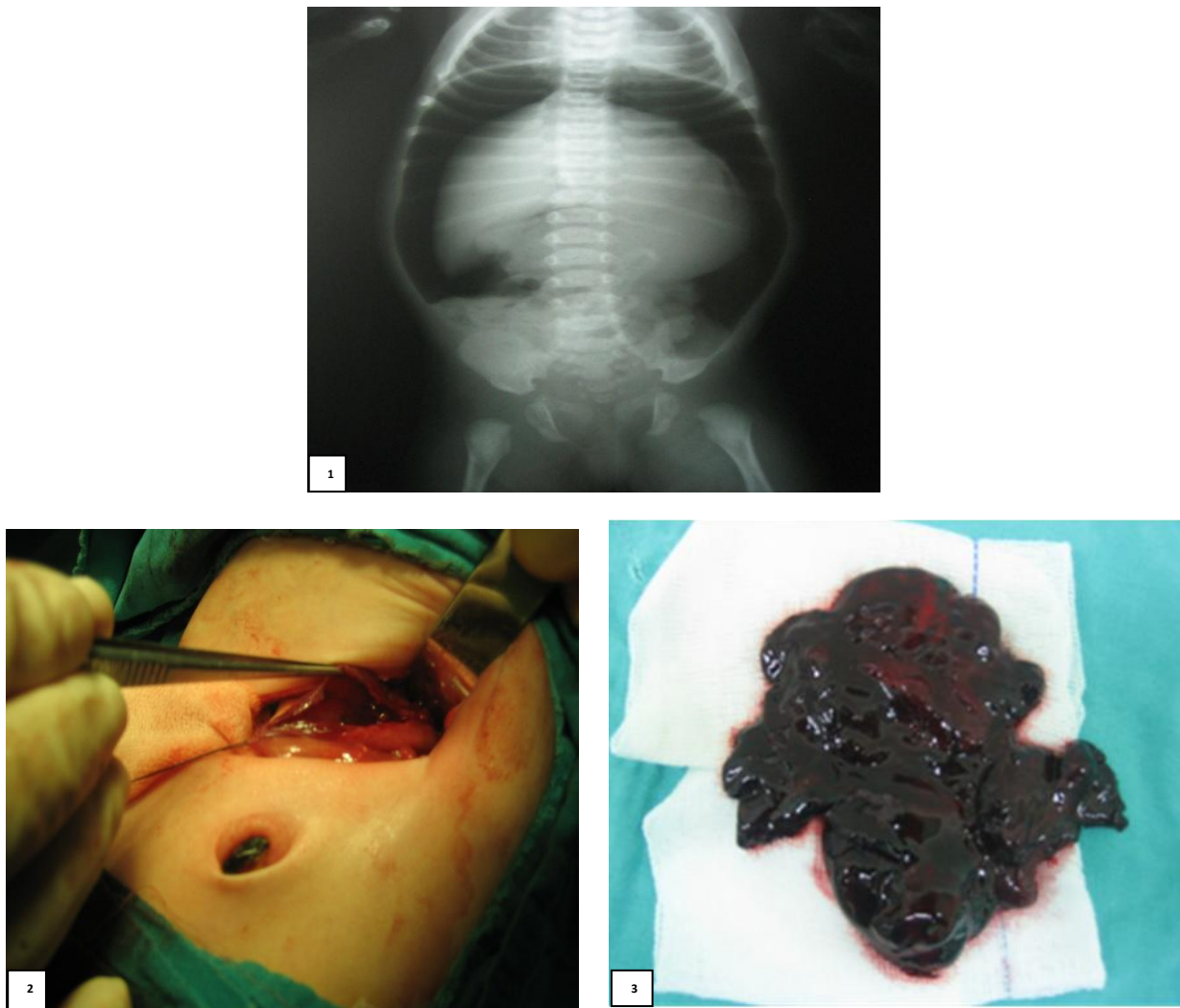
*Eskisehir Osmangazi University, Faculty of Medicine,  
Department of Pediatric Surgery, Meselik, Eskisehir  
Turkey*

**Phone:** + 90 222 239 2979/3254

**E-mail:** drrahul\_2000@yahoo.com

medical treatment during follow up, also a distention developed and progressed so that the patient was transported to our pediatric surgery clinic.

Since there was a significant abdominal distension and pneumoperitonium on the abdominal X-ray, she was operated promptly. The abdominal exploration showed a 5 cm long stomach perforation line on the anterior surface of greater curvature of the stomach (Figure 2). Inside of the stomach was filled with coagulum (Figure 3). The coagulum was aspirated and stomach was repaired



**Figure 1-3.** *Pneumoperitoneum at the abdominal x-ray(1), Gastric perforation line from fundus to corpus on the greater curvature(2) and Coagulum aspirated out from inside of the stomach(3)*

primarily and drain was inserted to the operation zone. Patient did well postoperatively and was tolerated oral feeding at the postoperative 5<sup>th</sup> day. She was discharged without any problem at the postoperative 8<sup>th</sup> day.

#### **Discussion**

The studies in the literature on GP of newborn could not describe the pathology with a specific etiological factor. It is mostly defined as a pathology occurring spontaneously [1-4]. LMWH treatment during gestation has been accepted as a safe procedure for both mother and fetus [5-7].

Grosfeld JL *et al* mentioned in their study that during newborn period while intestinal perforations are determined between the 5<sup>th</sup> – 15<sup>th</sup> days of birth, GP occurs between the 3<sup>th</sup> – 5<sup>th</sup> days [8]. In their study, they stated that at birth and before the symptoms of gastrointestinal bleeding appear in a patient with GP, the baby has a normal feeding, defecation pattern and no significant pathological finding. In our case, as it was described in Grosfeld's study, symptoms like hematemesis, hematochezia began in the second day of birth and pneumoperitonium appeared in the third day.

Gastric perforation is rarely seen in newborn; but it is observed more frequently in small for gestational age (SGA) or premature babies [9,10]. In our case, the patient was neither SGA nor premature.

A gastric perforation may occur secondary to the pathologies and conditions such as esophageal atresia with tracheoesophageal fistula; intra-esophageal intubation of a patient who is on a mechanical ventilation; during resuscitation; iatrogenic trauma and inappropriate orogastric tube insertion [8,11,12]. These pathologies and conditions are well known in pediatric surgery practice but our patient did not have any of these situations.

Intrapartum or postpartum anoxia; intestinal ischemia and absence of muscular layer of gastric mucosa have also been described as an associated factors in GP of newborn [13-16]. We did not determine any of these pathologies in our patient.

A recent report suggests that abnormal distribution of intestinal pacemaker cells may predispose some neonates to idiopathic gastric perforation. Endothelial damage during medical treatment with several drugs, feeding with hyperosmolar formula, bacterial colonization and insufficiency of immunity are also the underlying risk factors for GP in newborn [8, 17]. In our case, these risk factors also were not present. All these literature findings may state that GP in newborn most probably is a multifactorial and multisystemic pathology.

On the other hand although there are too many reports about safety of LMWH therapy during gestation [7] and non-transplacental migration of LMWH to the fetus [6]; we can not answer the question of “whether if the mother did not get treatment with LMWH during gestation, gastric bleeding and GP of the baby would occur or not”. The other question is the dosage of LMWH in pregnancy. Is there any possible association of low or high doses of LMWH and GP in a newborn? If there is an association, when exactly the treatment of LMWH should be stopped might also be asked. Some other points should also be clarified such as the effects of LMWH to the

placenta and placental circulation and what its impact to the fetus is.

Gastric perforation in newborn is an emergency situation which should interfered immediately to decrease morbidity and mortality. To explain the pathophysiology in our case, we may speculate that LMWH treatment during the pregnancy could be a risk factor causing massive gastric bleeding so that gastric outlet obstruction and perforation occur with coagulum plug. This is a very rare case and not reported in English literature yet.

## REFERENCES

1. Soo AI, Gye-Yeo L, Hahn ST. Spontaneous gastric perforation in a neonate presenting with massive hydroperitoneum *Pediatr Radiol* 2005; 35:1212-14
2. Kawasey Y , Ishii T, Arai H and Uga N. Gastrointestinal perforation in very low-birthweight infants *Pediatrics International* 2006; 48:599-603
3. Jawad AJ *et al.* Spontaneous neonatal gastric perforation *Pediatric Surgery Int* 2002; 18:396-99
4. Leone RJ, Krasna IH Spontaneous neonatal gastric perforation: Is it really spontaneous? *Journal of Pediatric Surgery* 2000; 35:1066-69
5. Carmen R, Tayyaba H, Milner *et al.* Efficacy and safety of once daily low molecular weight heparin (tinzaparin sodium) in high risk pregnancy. *Blood Coagulation and Fibrinolysis* 2008; 19: 689-92.
6. Deruellea P, Coulonb C. The use of low-molecular-weight heparins in pregnancy – how safe are they? *Current Opinon in Obstetrics and Gynecology* 2007; 19:573-77.
7. Maslovitz S, Many A, Landsberg JA *et al.* The safety of low molecular weight heparin therapy during labor. *The Journal of Maternal-Fetal and Neonatal Medicine*, 2005; 17:39-43

8. Grosfeld JL, Molinari F, Chaet M, Engum SA, West KW, Rescorla FJ, Scherer LR 3rd. Gastrointestinal perforation and peritonitis in infants and children: experience with 179 cases over ten years. *Surgery* 1996;120:650-55
9. Pelizzo G, Dubois R, Lapillonne A, Laine X, Claris O, Bouvir R, Chappuis JP. Gastric necrosis in newborn: a report of 11 cases. *Pediatr Surg Int* 1998; 13:346-49.
10. Abadir J, Emil S, Nguyen N. Abdominal foregut perforations in children: a 10-year experience. *J Pediatr Surg* 2005;40:1903-07.
11. Kara CS, Ilce Z, Celayir S, Sarimurat N, Erdogan E, Yeker D. Neonatal gastric perforation: review of 23 years' experience. *Surg Today* 2004;34:243-45.
12. Gauderer MW. Percutaneous endoscopic gastrostomy-20 years later: a historical perspective. *J Pediatr Surg*. 2001;36:217-19.
13. Lyold JR: The etiology of gastrointestinal perforation in the newborn. *J pediatr Surg* 1969; 4:77-84
14. Lyold J, Espiasse E, Bernstein J: Etiology of gastrointestinal perforation in newborn. *Harper Hosp Bull* 1964; 22:224
15. Richard J Leone, Irwin H. Krasna. 'Spontaneous' neonatal gastric perforation: is it really spontaneous? *J Pediatr Surg* 2000; 35: 1066-69.
16. Miserez M, Barten S, Geboes K, et al: surgical therapy and histological abnormalities in functional isolated small bowel obstruction and idiopathic gastrointestinal perforation in very low birth weight infant. *World J Surg* 2003;27:350-55
17. Shoerter N, Liu J, Money D et al: Indomethacin-associated bowel perforation: A study of possible risk factors. *J pediatr Surg* 1999;34:442-44