

Journal of Pediatric Sciences

Recurrent Chest Infection And Congenital Anomalies in Children With Morgagni's Hernia: An Unusual Case Series During Childhood

Ayşe Esin Kibar, Mehmet Burhan Oflaz, Sevcan Erdem,

Bahar Cakır, Tugrul Tiryaki, Emrah Senel

Journal of Pediatric Sciences 2012;4(4):e159

How to cite this article:

Kibar AE, Oflaz MB, Erdem S, Cakir B, Tiryaki T, Senel E. Recurrent chest infection and congenital anomalies with Morgagni's hernia: an unusual case series during childhood. Journal of Pediatric Sciences. 2012;4(4):e159.

Recurrent Chest Infection And Congenital Anomalies in Children With Morgagni's Hernia: An Unusual Case Series During Childhood

Ayşe Esin Kibar¹, Mehmet Burhan Oflaz², Sevcan Erdem³,
Bahar Cakır¹, Tugrul Tiryaki⁴, Emrah Senel⁴

¹Department of Pediatric Cardiology, Mersin Women's and Children's Hospital, Mersin; ²Department of Pediatric Cardiology, Cumhuriyet University Faculty of Medicine, Sivas, ³Department of Pediatric Surgery, Ankara Diskapi Children's Hospital Ankara, TURKEY

Abstract:

Aim: Congenital diaphragmatic hernias are common, whereas defects through the foramen of Morgagni are much more rarely observed. This study aimed to summarize clinically relevant three-year data on Morgagni's hernia (MH) in children.

Methods: A retrospective review was conducted on all the patients who underwent MH repair from 2005 to May 2008. A total of 7 children with MH were reviewed (4 females, aged 3.5 months to 9 years), and demographic data, clinical presentation, morbidity, and outcome were studied. Contrast studies and computed tomography (CT) scans of the thorax were performed for diagnosis.

Results: The most common complaints of the patients with respiratory disorders included cough and wheezing. Chest auscultation revealed rales, rhoncus, and/or wheezing, especially at the right hemithorax. Associated anomalies were documented in 6 patients (85.7%), most of whom presented pectus carinatum, malrotation, caput quadratum, undescended testes, micropenis, Down syndrome, and Marfan syndrome. The X-ray radiography and CT scans revealed a gas-filled cystic mass (5 cases) and homogeneous mass image (2 cases). MH diagnosis was confirmed following colonography. Of the 7 patients, 6 had right-sided MH and 1 had bilateral hernia. The MHs were most commonly accompanied by a hernia sac, whose contents were primarily limited to the colon. All the patients underwent transabdominal repair. The patients recovered well postoperatively.

Conclusions: Our study shows a relatively high frequency of MH compared with that reported in literature. MH should be considered as a diagnosis for patients who present unexplained radiological images associated with congenital anomalies and recurrent chest infection.

Keywords: Morgagni's hernia, recurrent chest infection, congenital anomalies, child

Accepted: November 1, 2012

Corresponding author: Ayşe Esin Kibar, MD, PhD, Mersin Children's Hospital, Halkkent Mahallesi Fatih Sultan Mehmet Bulvarı No: 23, 33240 Mersin, Turkey +90.3242230701 dreseresin@yahoo.com

Introduction

Morgagni's hernia (MH) is the rarest type of congenital diaphragmatic hernia (CDH) in the pediatric age group, representing about 2%–3% of all types of CDH in large series; it has unique features in terms of clinical presentation and a high incidence of associated anomalies [1-6].

The nonspecificity of symptoms contributes to delays in diagnosis of MH, especially when a child is inadequately examined [2]. The complaints of symptomatic patients primarily include recurrent chest infection (RCI) and occasional gastrointestinal symptoms in childhood [7]. In the neonatal period, it may present as acute respiratory distress (ARD) syndrome.

MH can also be confused with infections, tumors, or masses on chest radiographs [8-10]. Its presentation is extremely varied and may be associated with misleading clinical and radiologic assessments. Misdiagnosis can lead to life-threatening complications, such as obstruction and strangulation, so that preventing misdiagnosis and subsequent inappropriate or delayed management is crucial [11].

This report describes our experience with seven children at our hospital. All the patients were retrospectively reviewed for age at diagnosis, presenting symptoms, associated anomalies, operative findings, treatment, and outcome. This study was to evaluate the timely diagnosis and characteristics features associated with child. Literature devoted to MH occurrence was also reviewed. Our goal is to draw the attention of clinicians toward this unusual condition.

Patients and Methods

The medical records of all the patients diagnosed with MH and treated at our hospital were retrospectively reviewed. From 2005 to 2008, 7 patients with MH were treated. All of them were reviewed for age at diagnosis, gender, clinical presentation, associated anomalies, diagnosis, operative findings, treatment, and outcome. Diagnosis was achieved by contrast studies (chest X-ray, lateral radiography, and colonography) on all the cases and computed tomography (CT) scans of the thorax of 5 patients. Chest X-rays were performed every 2 months postoperatively as a control measure, and yearly thereafter.

Results

During a three-year period, 7 cases of MH were evaluated at our hospital. The relevant demographics, as well as clinical and operative findings on the MH patients, are shown in Table 1. A total of 3 males and 4 females were studied; their ages at presentation range from 3 months to 9 years (mean age, 3.1 years), and most of them (71.4%) were younger than 2 years at the onset of the condition. Of the 7 patients, 6 had right-sided MH and 1 had bilateral hernia. No relevant family history was observed in all the patients. Three of the patients are the offspring of a consanguineous marriage and two are sisters (Cases 6 and 7; Table 1). All the patients were delivered full term after uneventful gestation.

Most of the patients (85.7%) presented with chronic cough and RCI, which most of them have had since early infancy. Only Case 7 showed gastrointestinal symptoms. Constipation and abdominal distention for 6 months were observed. Respiratory complaints included severe coughing, wheezing, and respiratory distress with or without fever. The other symptoms were weakness, abdominal pain, loss of appetite, and upper respiratory tract infection. For 4 of the cases, chest auscultation revealed rales especially at the right thorax, and rhoncus and/or wheezing in 2 patients. A grade II systolic murmur was heard at the cardiac apex of Case 6. The echocardiogram measured normal cardiac chamber volumes and ejection fraction, but 1 patient (Case 6) with Marfan syndrome and mitral valve prolapse also had tricuspid valve prolapse. Associated malformations were found in 6 (85.7%) of the cases; 5 had pectus carinatum, 2 showed malrotation of the bowel, 1 had congenital valve disease associated with Marfan syndrome, 1 had Down's syndrome and pelvicalyceal ectasia, and 1 exhibited caput quadratum, micropenis, and undescended testes. All the children had normal motor and mental developmental milestones except for 2 (Cases 3 and 5; Table 1). The laboratory values were in normal range.

All the children were evaluated by posteroanterior (**Fig. 1.a**) and lateral radiography (**Fig. 1b**). A gas-filled cystic mass in 5 cases, and a homogeneous mass image in 2 cases were observed in the thoracic cavity. A CT scan of the thorax was performed in 5 patients (**Fig. 2**), 2 of whom exhibited mass contents. The diagnosis of MH was confirmed following colonography (**Fig. 3**).

One patient with Down's syndrome (Case 3) presented RCI at the age of 13 months. One of these attacks was

Table 1: Clinical characteristics and operative findings in 7 patients with Morgagni's hernia

Case No	1	2	3	4	5	6	7
Age / Sex	3 months / Female	11 months / Male	13 months / Male	16 months / Male	7 years / Female	9 years / Female	2 years / Female
Cause of admission	Chronic cough, wheezes	Chronic cough	Chronic cough, fever, weakness, respiratory distress	Chronic cough, wheezes	Chronic cough, wheezes	Chronic cough, wheezes	constipation
History	RCI	RCI	RCI	RCI	RCI	RCI	Abdominal distation after eating
Physical Findings	Bilateral rales	Declined respiration in inferior right lung	Crackles right lung	Bilateral crackles	Bilateral rales and rhonchi	Rchonchi and wheezing in right hemithorax	normal
Site of hernia	right	right	right	right	right	right	bilateral
Contents of hernial sac	Small bowel, colon, and omentum	colon	colon	colon	Part of liver on right side and colon	Part of right lobe of liver and colon	Large and small intestines, colon, omentum and part of liver on right side
Radiological Findings	Gas-filled cystic area in the right thoracic cavity	Homogenous mass in the right cardiophrenic angle	Gas-filled cystic area in the right thoracic cavity	Homogenous mass in the right cardiophrenic angle	Gas-filled cystic area in the right thoracic cavity	Lateral graphy showed uncertain (small size) air-fluid	Gas-filled cystic area in the right thoracic cavity
Congenital anomalies	None Malrotation	Pectus carinatum	Down's syndrome Umbilical hernia Pectus carinatum Bilateral pelvicalixiel ectasia	Caput quadratum Micropenis Undescended testes	Pectus carinatum Cerebral palsia	Marfan's syndrome Pectus carinatum MVP TVP Malrotation	Malrotation Pectus carinatum

RCI: Recurrent chest infection, MVP: Mitral valve prolapse, TVP: Tricuspid valve prolapse

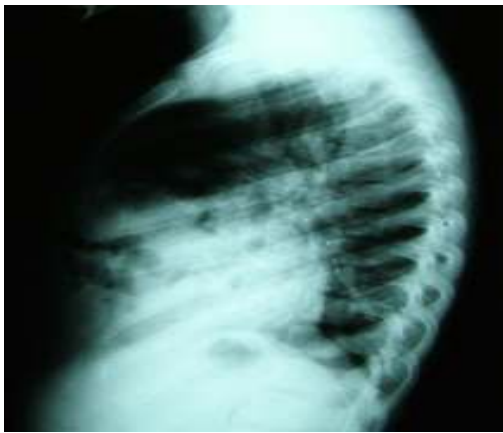
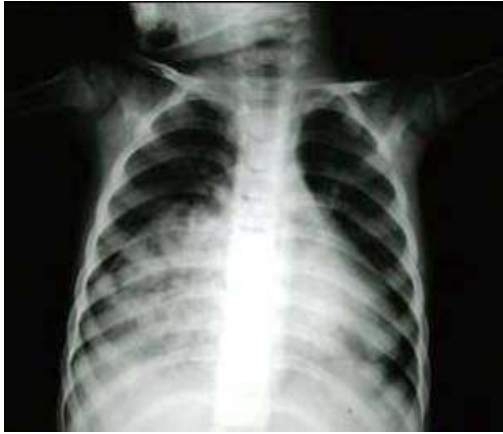
Fig. 1. (a) Antero posterior and (b) lateral chest radiograph demonstrating retrosternal gas shadow. These findings were interpreted as anterior herniation of bowel loops.

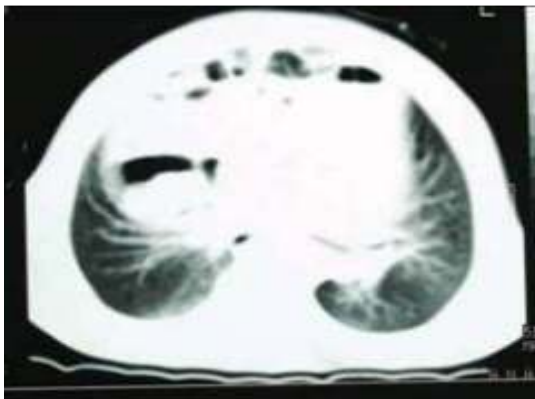


Fig. 2: Computed tomography image showing multiple bowel loops within the right thoracic cavity (white arrow) consistent with a Morgagni hernia. The diaphragm can be identified below the hernia contents.

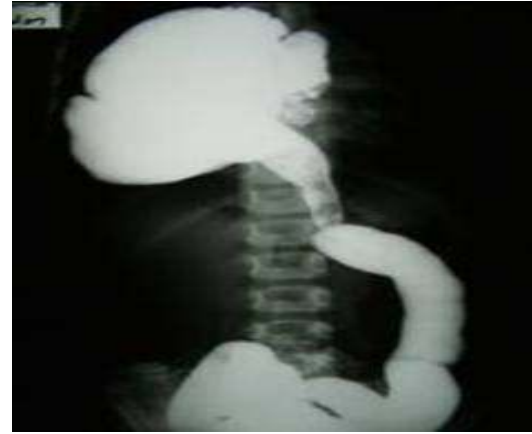

Fig. 3: Barium enema examination confirmed the diagnosis hernia of Morgagni

severe, necessitating admission to the intensive care unit. The patient with Marfan syndrome (Case 6) had RCI for one year. After most recent pediatric visit, she had been evaluated due to a chest infection. No prior history of abdominal trauma was observed, and a previous chest X-ray and colonography were noted as unremarkable without evidence of abdominal herniation or lung pathology. However, the lateral radiography showed unexplained air fluid levels. A thoracic CT scan was performed on Case 6 after observing multiple bowel loops in the right hemithorax. After 3 weeks, her respiratory complaints (cough and wheezing episodes) continued, and a chest X-ray was repeated, showing anterior herniation of bowel loops. Her sister (Case 7) had chronic constipation. The chest X-ray and lateral radiography findings (a gas-filled cystic mass in the right-middle and inferior region of the lung) led us to suspect MH. Her thoracic CT scan showed bowel loops herniating to the right side of the chest. The diagnosis was confirmed by colonography. Surprisingly at surgery, the patient was found to have bilateral MH.

All our patients underwent transabdominal repair because this procedure is less traumatic, enables the repair of rotational abnormalities and defects, and enhances the ease of hernial content reduction. The hernia sacs were excised and the defect was repaired by suture or patch closure. A hernia sac was present in all the patients. The contents of the hernia sac extended to the colon, small intestines, and part of the liver and omentum, with the colon being the most widely covered (85.7%; Table 1). No mortality occurred, and all the patients exhibited good postoperative recovery.

Table 2. A review of published cases: associated congenital anomalies and symptoms hernia of morgagni

Study /year	Type of publication	Participants	Common symptoms	Associated anomalies
Roy et al.¹⁵ 2011	Case report	A young boy	Obstructive jaundice	Malrotation of duodenum
Kim et al.¹⁶ 2008	Case report	One child	Bowel obstruction	Malrotation incarcerated small bowel hernia
Al-Salem¹³ 2007	Case series	20 children	Respiratory symptoms	Congenital heart disease, malrotation of bowel, Down's syndrome
Picard et al.¹⁷ 2007	Case series	2 children	RCI	Down's syndrome
Cigdem et al.¹⁸ 2007	Case series	16 children	respiratory symptoms	Down's syndrome Turner syndrome
Al-Salem et al.² 2002	Case series	15 children	RCI evaluation of trauma acute respiratory distress	Malrotation Congenital heart disease Down's syndrome
Singh et al.³ 2001	Case report	A case of twins	Acute gastric volvulus	Malrotation
Soylu et al.⁸ 2000	Case series	7 children	Acute or chronic respiratory symptoms	Congenital heart disease Right inguinal hernia Pectus carinatum Obstruction of utero-pelvic junction
Etheridge et al.¹⁹ 2001	Case report	An infant	cyanosis	-
Nawaz et al.¹ 2000	Case series	5 children	respiratory symptoms	Down's syndrome malrotation
Al-Arfaj AL.²⁰ 1998	Case series	5 children	Respiratory distress or pulmonary infection	Hypertrophic pyloric stenosis, malrotation of the gut, and left inguinal hernia; Down syndrome; and multiple Mongolian spots and umbilical hernia
Berman et al.²¹ 1989	Case series	15 children	Gastrointestinal and respiratory,	Abnormal bowel fixation
Pokorny et al.²² 1984	a review of the literature	17 children	Acute or chronic respiratory symptoms	Congenital heart disease Trisomy 21 Cantrell's syndrome

RCI: Recurrent chest infection

Discussion

Our study shows a relatively high frequency of MH compared with that reported in literature. A high incidence of clinical presentation (85.7%) showed RCI since early infancy. In addition, 6 patients had additional anomalies, with most of them presenting with pectus carinatum.

Of all types of CDH, MH is usually undetected in children [12,13]. In the pediatric age group, the majority of MH occurrence is asymptomatic and nonspecific, thereby leading to delays in diagnosis [9,10,14]. Pediatric cases with this condition are shown in Table 2; a review of literature focusing on such cases is also presented [1-3,8,13,15-22]. Seven children (4 females and 3 males) with congenital MH (6 right-sided, 1 bilateral) were treated over a period of three years at our hospital. This frequency is high compared to that of other series, but the cause of this frequency remains unknown (Table 2). The high occurrence of MH may be attributed to long-standing respiratory symptoms. In a 2007 study by Al-Salem in Saudi Arabia, the review of more than 18 years of records revealed only 20 cases of CDH through the foramen of Morgagni [13] (Table 2). A small-scale three-center study in Turkey, conducted between 1994 and 1999, showed 7 patients with Morgagni CDH diagnosed by chest X-ray and confirmed by barium-contrast radiographs [8]. Salman from Turkey reported 6 cases (3%) of MH among 20 children with anterior diaphragm hernia during a 15-year period (1980–1995) [23]. Of interest is the relatively high frequency of MH seen in this part of the world.

MH stems from anteromedial diaphragmatic defects [23,24]. Although it usually lies on the right side and slightly posterior to the xiphoid process, it is rarely found on the left or bilateral side. The omentum and transverse colon are the most common abdominal contents to herniate into the sac [8,9]. In our series, 6 of the patients presented with right-sided hernia. Case 7 had bilateral hernia. The contents of the hernia sac were limited to the small bowel, colon, and part of the liver and omentum. The contents of the hernia sac usually extended to the colon (Table 1).

Although MH is a surgical condition, for its asymptomatic course, diagnosis is usually incidental in the pediatric age group [2,8,25]. The presentation of children with MH is variable and can present in any of three forms: (1) During infancy, it can lead to ARD [12]. Case 3 presented with ARD at the age of 13 months. (2) MH can be asymptomatic and discovered accidentally, or precipitated by trauma and rapid weight gain. [3] Commonly,

presentation in the pediatric age group begins with RCI and is rarely accompanied by gastrointestinal symptoms [1,13,17,18,22] (Table 2). Most of our patients (85.7%) presented with RCI, and although no mortality occurred, a significant number had sustained morbidity. The cases presented with chronic cough, wheezing, and constipation.

Soylu et al. reported that 3 out of 7 infants had respiratory distress, while the remaining patients showed weakness, limping, and upper respiratory tract infection [8]. In a review of 15 cases with MH, Berman et al. presented 6 children with gastrointestinal symptoms (constipation, diarrhea, vomiting, and postprandial fullness), 4 children with respiratory symptoms, including 3 cases with respiratory infection and 1 with ARD [21]. Al-Salem et al. treated MH, and all the patients suffered from RCI (2) (Table 2). Our observations confirm those of other researchers that MH presents in infancy and childhood.

MH is usually diagnosed with routine chest X-rays, although many patients may have initially negative diagnostic imaging. Therefore, lateral chest radiographs are the most important diagnostic tools for this condition [2,26]. The majority of MH occurrence appears as gas-filled bowel loops, air-fluid levels, and a soft tissue mass in the thoracic cavity, or lucency in the chest with deviation of the heart. Mediastinum may be observed, making final diagnosis complicated and challenging. A good lateral film will reveal that the hernia is located anteriorly [8,27]. If the herniation is intermittent, however (as in Case 6), the plain radiograph may be normal.

If the omentum or part of the liver is present in the sac, a solid paracardiac shadow will appear on the chest radiograph [1,2,11,28]. Differential diagnoses would include intrathoracic tumor, pericardial cyst, bronchogenic cyst, cyst adenomatoid malformation, paraesophageal hernia, diaphragmatic evantration, lobe collapse and/or pneumonic consolidation, pericardial fat pad, sequestration of the lung, and mediastinal mass [2,8,14]. Gas-filled bowel loops were observed in 5 cases, and homogeneous mass density images were seen in the right thoracic cavity of 2 cases. Our observations suggest that the considerable variability in radiographic appearance may lead to misdiagnosis. Many patients are initially misdiagnosed, secondary to the constellation of vague symptoms and X-ray findings [13].

CT can help further characterize anterior mediastinal masses that are detected on chest radiographs, as well as aid preoperative diagnosis and operative planning [20,28].

In our review, CT was performed on 5 cases (2 had solid contents). Therefore, our experience supports that described in other reports, which state that thoracic CT is a useful and non-invasive method of diagnosing MH [9,28]. However, Fagelman et al. did not confirm diagnosis after chest radiography, so that the fluctuations in bowel defects were undetected [29]. The absence of confirmation may make diagnosis difficult and confusing. Interestingly, Case 6 was diagnosed with Marfan syndrome at another children's hospital; the patient had it for one year and suffered from RCI. This patient's chest X-ray and colonography looked normal despite the presence of a retrosternal defect, but the lateral radiography showed unexplained air fluid levels. The CT scan showed bowel loops in the right hemithorax. If MH is suspected upon evaluation, a lateral radiography and CT scan may also be useful, with further diagnostic imaging including lower GI contrast studies. In our opinion, the herniation was intermittent and asymptomatic, thereby making MH diagnosis difficult (Case 6, Table 1) in children.

Although there is no known genetic cause of MH, it is often observed in conjunction with other congenital defects such as heart defects and Down's syndrome [1-3,12,30]. Five of our patients had associated anomalies; two had genetic anomalies, 1 exhibited Down's syndrome, and 1 had Marfan syndrome. Additional anomalies included pectus carinatum, bilateral undescended testis, micropenis, pelvicalyceal ectasia, cerebral palsy, malrotation, and caput quadratum. These anomalies existed in most of our patients (71.4 %), suggesting a link between MH and congenital anomalies. When MH is diagnosed, therefore, the presence of cardiac, gastrointestinal, urogenital, and skeletal anomalies should be examined.

MH repair is indicated immediately after diagnosis because of the risk of visceral complications such as obstruction or strangulation [7]. The treatment of MH in our patients was surgical repair, including the reduction of abdominal contents and repair of diaphragmatic defects. No postoperative complications occurred.

Conclusion

Our study shows a relatively high frequency of MH compared with that reported in literature. We have described interesting cases of children initially presenting with RCI and congenital anomalies. Vague symptoms at presentation may be associated with late-presenting CDH with previously normal radiological imaging studies. In the

differential diagnosis of any child with long-standing respiratory problems, unexplained radiological images or other congenital anomalies, especially pectus carinatum, may exist. MH can be diagnosed via contrast studies. CT would be the preferred imaging modality for diagnostic confirmation and operative planning in children because this method facilitates appropriate management in a timely fashion.

REFERENCES

- 1- Nawaz A, Matta H, Jacobsz A, Al-Khouder G, Al-Salem AH. Congenital Morgagni's hernia in infants and children. *Int Surg.* 2000;85:158-62.
- 2- Al-Salem AH, Nawaz A, Matta H, Jacobsz A. Herniation through the foramen of Morgagni: early diagnosis and treatment. *Pediatr Surg Int.* 2002;18 :93-7.
- 3- Singh S, Bhende MS, Kinnane JM. Delayed presentations of congenital diaphragmatic hernia. *Pediatr Emerg Care.* 2001;17:269-71.
- 4- Estevão-Costa J, Soares-Oliveira M, Correia-Pinto J, Mariz C, Carvalho JL, da Costa JE. Acute gastric volvulus secondary to a Morgagni hernia. *Pediatr Surg Int.* 2000;16:107-8.
- 5- Azzie G, Maoate K, Beasley S, Retief W, Bensoussan A. A simple technique of laparoscopic full-thickness anterior abdominal wall repair of retrosternal (Morgagni) hernias. *J Pediatr Surg.* 2003;38:768-70.
- 6- Karamustafaoglu YA, Kuzucuoglu M, Tarladacalisir T, Yoruk Y. Transabdominal subcostal approach in surgical management of Morgagni hernia. *Eur J Cardiothorac Surg.* 2011; 39:1009-11.
- 7- Loong TP, Kocher HM. Clinical presentation and operative repair of hernia of Morgagni. *Postgrad Med J.* 2005;81:41-4.
- 8- Soylu H, Koltuksuz U, Kutlu NO, Sarihan H, Sen Y, Ustün N et al. Morgagni hernia: an unexpected cause of respiratory complaints and a chest mass. *Pediatr Pulmonol.* 2000;30:429-33.
- 9- Kurkcuoglu IC, Eroglu A, Karaoglanoglu N, Polat P, Balik AA, Tekinbas C. Diagnosis and surgical treatment of Morgagni hernia: report of three cases. *Surg Today* 2003;33:525-8.
- 10- Tarım A, Nursal TZ, Yildirim S, Ezer A, Caliskan K, Törer N. Laparoscopic repair of bilateral morgagni hernia. *Surg Laparosc Endosc Percutan Tech.* 2004;14:96-7.

- 11- Elhalaby EA, Abo Sikeena MH. Delayed presentation of congenital diaphragmatic hernia. *Pediatr Surg Int.* 2002;18:480-5.
- 12- Robnett-Filly B, Goldstein RB, Sampior D, Hom M. Morgagni hernia: a rare form of congenital diaphragmatic hernia. *J Ultrasound Med.* 2003;22:537-9.
- 13- Al-Salem AH. Congenital hernia of Morgagni in infants and children. *J Pediatr Surg.* 2007;42:1539-43.
- 14- Ponsky TA, Lukish JR, Nobuhara K, Powell D, Newman KD. Laparoscopy is useful in the diagnosis and management of foramen of Morgagni hernia in children. *Surg Laparosc Endosc Percutan Tech.* 2002;12:375-7.
- 15- Roy M, Bala AK, Biswas S, Peters T. Morgagni hernia presenting as obstructive jaundice. *Indian Pediatr.* 2011; 48:59-61.
- 16- Kim SW, Jung SH, Kang SH. A case of left-sided Morgagni hernia complicating incarcerated small bowel hernia. *Korean J Gastroenterol.* 2008; 51:52-5.
- 17- Picard E, Ben Nun A, Fisher D, Schwartz S, Goldberg M, Goldberg S. Morgagni hernia mimicking pneumonia in Down syndrome. *J Pediatr Surg.* 2007; 42:1608-11.
- 18- Cigdem MK, Onen A, Okur H, Otcu S. Associated malformations in Morgagni hernia. *Pediatr Surg Int.* 2007;23:1101-3.
- 19- Etheridge SP, Ruttenberg HD, Williams RV. An unusual cause of severe cyanosis in infancy. *Ann Thorac Surg.* 2001;71:1016-8.
- 20- Latif Al-Arfaj A. Morgagni's hernia in infants and children. *Eur J Surg.* 1998 ;164:275-9.
- 21- Berman L, Stringer D, Ein SH, Shandling B. The late-presenting pediatric Morgagni hernia: a benign condition. *J Pediatr Surg.* 1989;24:970-2.
- 22- Pokorny WJ, McGill CW, Harberg FJ. Morgagni hernias during infancy: presentation and associated anomalies. *J Pediatr Surg.* 1984;19:394-7.
- 23- Salman AB, Tanyel FC, Senocak ME, Büyükpamukçu N. Four different hernias are encountered in the anterior part of the diaphragm. *Turk J Pediatr.* 1999;41:483-8.
- 24- Laituri CA, Garey CL, Ostlie DJ, Holcomb GW 3rd, St Peter SD. Morgagni hernia repair in children: comparison of laparoscopic and open results. *J Laparoendosc Adv Surg Tech A.* 2011;21:89-91.
- 25- Matsushita T, Seah PW, Gani J. Giant Morgagni Hernia Causing Cardiac Tamponade. *Heart Lung Circ.* 2007; 16 :392-393.
- 26- Nasr A, Fecteau A. Foramen of Morgagni hernia: presentation and treatment. *Thorac Surg Clin.* 2009;19:463-8.
- 27- Zaleska-Dorobisz U, Bağlaj M, Sokołowska B, Ladogórska J, Moroń K. Late presenting diaphragmatic hernia: Clinical and diagnostic aspects. *Med Sci Monit.* 2007;13:137-46.
- 28- Bağlaj M, Dorobisz U. Late-presenting congenital diaphragmatic hernia in children: a literature review. *Pediatr Radiol.* 2005;35(5):478-88.
- 29- Fagelman D, Caridi JG. CT diagnosis of hernia of Morgagni. *Gastrointest Radiol.* 1984;9:153-5.
- 30- Ceylan E, Onen A, Sanli A, Yilmaz E, Uçan ES. Morgagni hernia: late diagnosis in a case with Down syndrome. *Respiration* 2004;71:641.