

A morphometric evaluation of anterior fontanel and cranial sutures in infants using computed tomography

Hadi SASANI^{1,*}, Sinan TUFEKCI², Aysen HAKSAYAR³

¹Department of Radiology, Faculty of Medicine, Tekirdag Namik Kemal University, Tekirdag, Turkey

²Department of Pediatrics, Division of Neonatology, Faculty of Medicine, Tekirdag Namik Kemal University, Tekirdag, Turkey

³Department of Pediatrics, Faculty of Medicine, Tekirdag Namik Kemal University, Tekirdag, Turkey

Received: 16.07.2021

Accepted/Published Online: 17.01.2022

Final Version: 18.03.2022

Abstract

To retrospectively analyze anterior fontanel (AF) and the morphometric findings of cranial sutures in infants under two years of age who underwent cranial computed tomography (CT). A total of 227 cases, who had cranial CT examination, were studied retrospectively. Forty-five patients were excluded. The study was conducted with 182 patients who had adequate imaging with optimum quality. The diameter and area of AF and cranial sutures of the patients were measured using three-dimensional CT reformat and axial CT images. Male patients made up 53.8% of the total patients and the median age was 6 months. Normocephaly in 86.3%, plagiocephaly in 10.4%, scaphocephaly in 2.7% and trigonocephaly in 0.5% of the cases were present. The median AF transverse diameter was 29.75 mm, the median anteriorposterior diameter was 27.25 mm, and the median fontanel area was 400 mm². AF was closed in 30.4% in 13-18 months old patients and 85.7% in 19-24 months old patients. Metopic suture was closed 10% in the first 3 months of age / their lives, 74.3% in 7-9 months of age, and 100% in 19-24 months of age. There was a significant negative correlation between head circumference and suture diameters in infants with open and normosephalic AF, in the CT examination ($p < 0.05$, $R = -0.106 - 0.271$). In this study, it was observed that 14.3% of AF did not close radiologically in 19-24 months in the Turkish population living in the Europe - Balkan region. This suggests that AF closes in some patients after the age of two.

Keywords: infant, cranial fontanel, computed tomography, anterior fontanel

1. Introduction

At birth, a baby has six fontanelles as anterior, posterior, two mastoids and two sphenoids. It is known that mastoid, sphenoid, posterior fontanelles ossify at 6 months or earlier (1,2) and the anterior fontanel (AF) ossify at around 18 months old (1,3). AF is the largest and most important fontanel in the newborn, consisting of a rhomboid non-mineralized fibrous membrane located between the frontal and parietal bones (4-6). This fibrous area provides enough flexibility to allow the brain to grow and the head to pass through the birth canal during birth without putting pressure on the skull (7).

There is a variation in the basic characteristic of a normal AF and it may differ according to populations and races. AF is on average 2.1 cm (0.6 - 3.6 cm) on the first day of life, and black babies have larger fontanelles (1.4 - 4.7 cm). AF closure (AFC) usually occurs within the first two years of life, with some studies reporting average closure times of 13-16 months. It can close in the first few months of life and the median age of closure is 13.8 months. When babies are three months old, 1% AF closes; 38% by 12 months and 96% by 24 months. AF tends to close earlier in boys than in girls (3, 8, 9).

Cranial sutures are a type of hyaline cartilage joint with a fibrous structure that occurs only in the skull, and is called

synchondrosis. In a study conducted by Caffey et al. with an X-ray in 1978, it was reported that the metopic suture usually closes at the age of six, but may not close in 10% of the patients until adulthood (10). Vu et al. conducted a three-dimensional cranial computed tomographic (CT) study in 2001. This study showed that metopic (or frontal) suture fusion can normally occur at 3 months of age, and complete fusion can occur at 9 months of age. This proved that 3D CT scans can be used at an early age (3-9 months). Complete closure of the suture cannot be considered as evidence of metopic synostosis (11).

The sagittal suture is typically the suture that closes at the age of about 22 years, the coronal suture at approximately 24 years and the lambdoid and squamous sutures at approximately 26 and 60 years, respectively (12).

It is recommended to evaluate the size of AF using the index finger in the physical examination proposed by Popich (1972). However, in recent years, cross-sectional imaging methods have been more useful to accurately evaluate morphometric properties such as fontanel size and closure.

In this study, we aimed to examine the morphometric findings of AF and sutures in infants under two years of age with cranial CT.

*Correspondence: hhasani@nku.edu.tr

2. Materials and Methods

2.1. Ethical statement

The study was designed as a retrospective study which has been approved by local ethical committee of Tekirdag Namik Kemal University, Faculty of Medicine, Tekirdag, Turkey (Approval number: 2020.261.12.06). The study protocol conforms to the ethical guidelines of the 1975 Declaration of Helsinki as reflected in a prior approval by the institution's human research committee.

2.2. Patient population

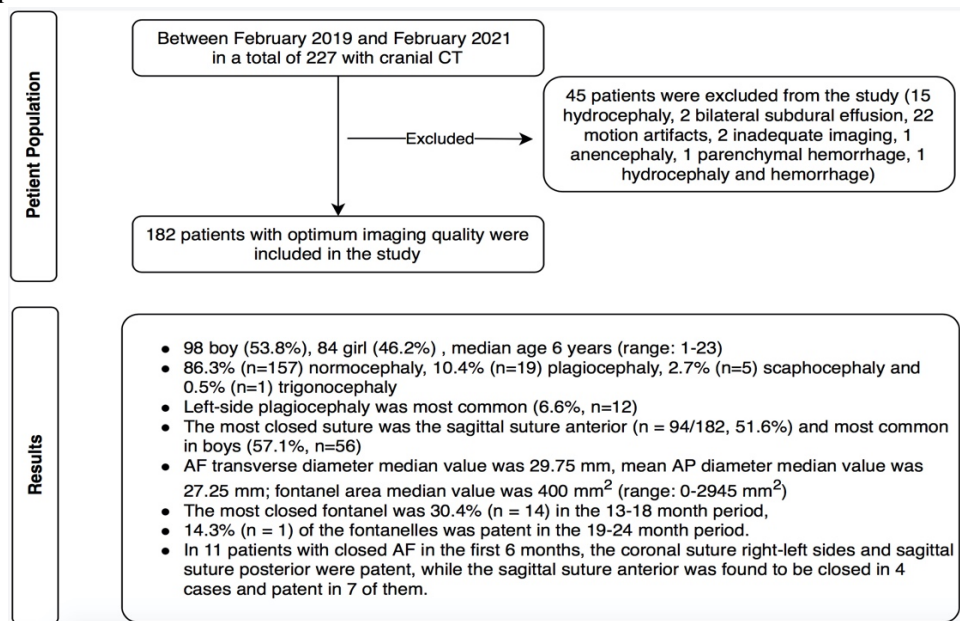


Fig. 1. Flow chart of the study

2.3. CT scanning and parameters

In the study, a 128-row multi-detector CT device (Aquilion™ Prime; Canon Medical Systems) was used for image acquisition. All scans were performed with the patient's supine, head first starting from below the base of skull to vertex, using the following parameters: tube voltage: 120 kV, 150 effective mAs; slice thickness: 1 mm.

2.4. CT image evaluation

CT images assessment was performed by a radiologist. The clinical and laboratory evaluation was done by a pediatrician. CT images with optimum imaging quality were included in the evaluation.

By using 3D reconstructions and a volume-rendering technique (VRT) methods in Sectra 7.0 workstation (Sectra AB, Linköping, Sweden), on 3D images the diameters (anterioposterior-AP and transvers) and area measurement of the AF, cranial shape and suture aperture status were evaluated (Fig. 2). On axial CT images, diameters of cranial sutures (metopic, sagittal, coronal) were measured. On axial CT images of normocephalic groups, the head circumference measurements were calculated using formulas as following:

$$\text{Head circumference} = \left[\frac{(\text{Cranial AP} + \text{Transvers diameters})}{2} \right] \times 3.14$$

A total of 227 patients, with cranial CT examination, were studied retrospectively between February 2019 and February 2021. Forty-five patients were excluded from the study due to the following reasons: fifteen hydrocephaly, two bilateral subdural effusion, one hydrocephaly and hemorrhage, twenty-two CT images with motion artifacts, two inadequate imaging, one anencephaly and one parenchymal hemorrhage. The remaining 182 patients with optimum imaging quality were included in the study (Fig. 1).

AFC Referring to the publications using our data on clinical evaluation, fontanel areas smaller than 114 mm² were considered as closed (13-16).

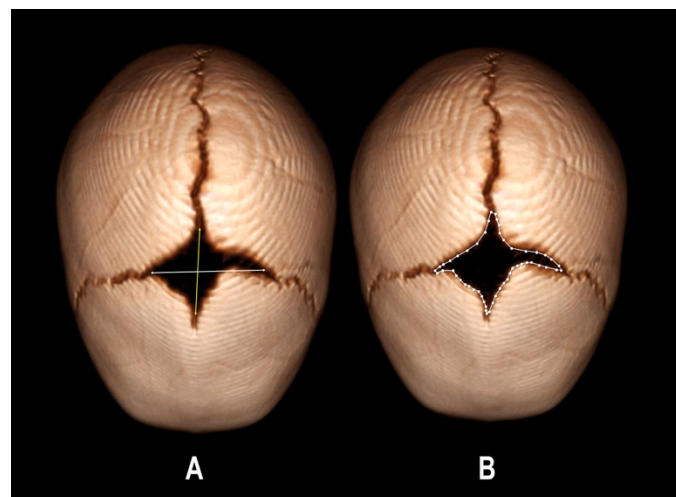


Fig. 2. AF diameters (AP and transverse) (A) and area measurement (B) in 3D reformatted images

2.5. Statistical analysis

Data analysis was performed using the statistical package program 22 (SPSS, Inc., Chicago IL, USA). Normality tests of the data showed an abnormal distribution. Descriptive analyses

of all data were performed and median (minimum- maximum) were given. In the evaluation of variance between age groups, Kruskal-Wallis test and in categorical data assessment Chi-square tests were used. The Spearman rho test was used to evaluate the correlation between groups. The statistical significance level was accepted as $p < 0.05$.

3. Results

3.1. Total patient population

The study population comprised of 98 boys (53.8%) and 84 girls (46.2%), and the median age was six months (range: 1-23). Normocephaly was found in 86.3% (n = 157) of the cases, plagiocephaly in 10.4% (n = 19), scaphocephaly in 2.7% (n = 5) and trigonocephaly in 0.5% (n = 1). Plagiocephaly was mostly observed on the left side (63%) and in the male gender (13.3% in boys, 7.1% in girls).

Metopic suture was the most closed suture (51.6%), followed by coronal suture right side (4.4%), coronal suture left side (3.8%) and sagittal suture. (2.2%). In our study, metopic suture closure was 57.1% (n = 56) in boys and 45.2% (n = 38) in girls. During the 19-24 months period, the sagittal suture was 100%, and 85.7% of the right and left coronal

sutures were patent. In the 0-24 months period of the sutures, the median of metopic suture was 0 (0-11mm), sagittal suture median was 1.60 mm, coronal suture was 1.15 mm on the right, and the median of coronal suture was 1.30 mm on the left. In the first 6 months, the metopic suture was mostly closed at 23.7%.

AF median transverse diameter was 29.75 mm (range: 0 - 71.30), median AP diameter was 27.25 (range: 20-89.50) mm; median fontanel area was 400 mm² (range: 0-2945). In the first six months 11.3% of AF, in 7-12 months 28.3%, in 13-18 months 56% and in 19-24 months 85.7% of AF were closed (Fig. 3, 4; Table 1).

A statistically significant difference was found between age groups and fontanel area and diameter ($p < 0.05$). A negative correlation was observed between age and fontanel diameters (transverse, AP) and area ($p < 0.05$, $r = -319$, -538 , -483 , respectively). The Fontanel area and diameter decreased with increasing age.

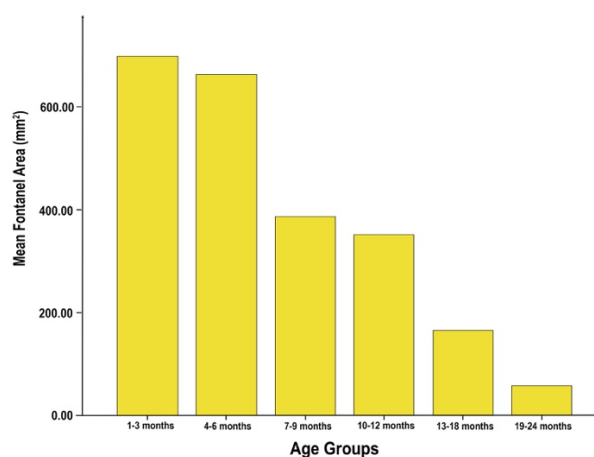
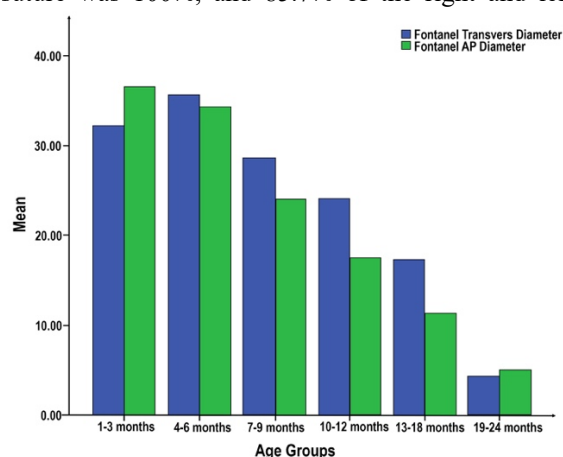


Fig. 3. Anterior fontanel AP diameter and area gradually decreasing according to age groups

Table 1. Patency of AF according to age groups (Field measurements are median values)

| Anterior Fontanel Patency Status | | | |
|----------------------------------|---|---|---------------|
| Age groups | Closed (Below 114 mm ²) | Patent (Above 114 mm ²) | Total (n=182) |
| 1-3 months | 10.0% (n=6) 58.34 ± 36.14 mm ² | 90% (n=54) 709 ± 445.57 mm ² | n= 60 |
| 4-6 months | 13.5% (n=5) 0 ± 26.31 mm ² | 86.5% (n=32) 646.5 ± 556.63 mm ² | n= 37 |
| 7-9 months | 25.7% (n=9) 17 ± 46.33 mm ² | 74.3% (n=26) 433 ± 310.20 mm ² | n= 35 |
| 10-12 months | 33.3% (n=6) 0 ± 42.85 mm ² | 66.7% (n=12) 359 ± 371.07 mm ² | n= 18 |
| 13-18 months | 56.0% (n=14) 0 ± 39.82 mm ² | 44.0% (n=11) 220 ± 216.10 mm ² | n= 25 |
| 19-24 months | 85.7% (n=6) 0 mm ² | 14.3% (n=1) 397 mm ² | n= 7 |

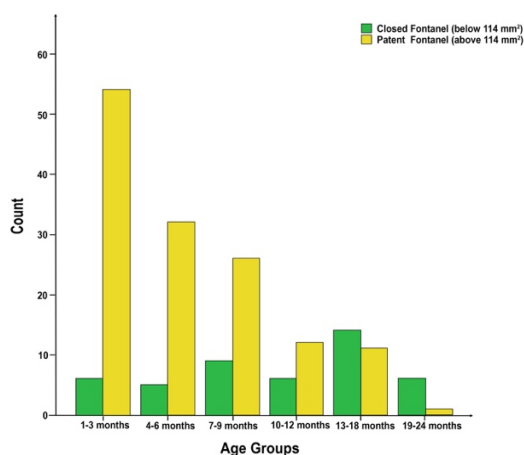


Fig. 4. Although it is shown that patent AF gradually decreases with age according to age groups, the presence of patent AF in the 19-24 months period (n = 1, 14.3%) has been shown and closed AF is mostly in 13-18 months

3.2. Normocephalic group

The measurements of AF and the sutures are given in Table 4. A statistically significant difference was observed between age groups in these defined parameters (p<0.05). A negative correlation was found between the fontanel area and the head circumference (p<0.05, r=-0.393). While age and head circumference were positively correlated, fontanel area, diameters and suture diameters showed a negative correlation (p <0.05) and decreased with increasing age. In the comparison between the head circumference according to gender, a statistically significant difference was observed in the head circumference (p <0.05) and the head size was more prominent in male gender. In the group with normocephalic and patent AF, the median head circumference was 391.56 mm (range: 300.18-458.44), and a negative significant correlation was found between the head circumference and the suture diameters (p<0.05, r=-0.106 -0.271).

Table 2. Comparison of the studies in the literature with the current study

| Race | n | Modality | 0-3 months, AFC % | 4-6 months, AFC % | 7-9 months, AFC % | 10-12 months, AFC % | 13-18 months, AFC % | 19-24 months, AFC % |
|---|-----|--------------|-------------------|-------------------|-------------------|---------------------|---------------------|---------------------|
| Maori/Pasifika (21) | 116 | CT, Clinical | 0 | 25 | 30 | 47 | 80 | 100 |
| NZ European (21) | 47 | CT, Clinical | 0 | 11 | 38 | 60 | 100 | 50 |
| Nigerian (4) | 337 | Clinical | 4 | 11 | 35 | 54 | ND | ND |
| American (20) | 459 | CT, Clinical | 0 | 4 | 7 | 44 | 72 | 93 |
| Iranian (30) | 550 | Clinical | 0 | 0 | 11 | 50 | 94 | 100 |
| Indian (36) | 445 | Clinical | 0 | 2 | 4 | 23 | 64 | 87 |
| Current Study (Turkish population, Balkan region) | 182 | CT | 10 | 135 | 25.7 | 33.3 | 56 | 85.7 |

This indicates that there is a large amount of variation in fontanel size at birth and this variation continues throughout the AF closure process. In addition, in the present study, there is a case in which AF was still open during the 19-24 months period; it was similar to the case stated in the study in the Maori/Pasifika group (21). The average of the AF area in the first three months was 606 mm² (n = 32/116) in the

4. Discussion

AFC requires investigation due to early, delayed, abnormal AF size and underlying mechanism of pathophysiology. Premature closure and reduced size of AF is thought to be syndromic craniosynostosis due to premature fusion of sagittal and coronal sutures (17, 18) Small size of AF or other etiologies of early AFC are thought to reflect the causes of microcephaly and may be due to fetal alcohol syndrome, hypoxic-ischemic damage or abnormal brain development due to congenital infections, malnutrition, chromosome abnormalities or dysmorphic syndromes (8).

In the literature, the AFC reported average closure times of 13-16 months (3, 9). Aisenson et al. showed that there was a normal fusion distribution between 4 and 26 months, and that AF closure occurred between 7 and 19 months in 90% (19). In studies using the CT modality (20, 21) in the first six months, the AFC rates in different populations were 30% in the Maori/Pasifika group, 38% in the New Zealand (NZ)-European group, 7-14% in the American group, and 25.7% in the current study had AFC in accordance with the literature (Table 2). This is due to the differences among races, but may be due to children living in countries with and without adequate sunlight or nutritional factors such as vitamin D (8, 9, 22).

The reported average AF area in the Maori/Pasifika group was initially 668 mm², this area had dropped to about 75% of its original size in 4-6 months, and it takes another 12 months for the next 25% to fully fuse, to about 25% in 10-12 months. Average area of AF in the NZ-Europe group in the 1-3 months period decreased to 854 mm², 650 mm² in 7-9 months and 45 mm² in 13-18 months (21). In our study, the median AF value was 599 mm², 47.07% was fused in 7-9 months, 60.1% was fused in 10-12 months and 85.30% in 13-18 months (Table 3)

Maori/Pasifika group, 854 mm² (n = 11/47) in the NZ / Europe group (21). The median of AF area in the first 3-4 months in the study by Pindrik et al. was found as 794.8 mm² (n = 37/459) (16). In our study, the median of AF area in the first three months was 599 ± 475.96 mm² and it was found to be lower than the other studies. This may be due to racial differences, geographic location, and nutritional status (8, 9, 22).

Table 3. AF area by age group

| Age Groups | Anterior Fontanel Area (mm ²) | Total (n= 182) |
|--------------|---|----------------|
| 1-3 months | 599 (range: 0 - 2248) | n= 60 |
| 4-6 months | 605 (range: 0 - 2945) | n= 37 |
| 7-9 months | 317 (range: 0 - 1173) | n= 35 |
| 10-12 months | 239.5 (range: 0 - 1360) | n= 18 |
| 13-18 months | 88 (range: 0 - 691) | n= 25 |
| 19-24 months | 0 (range: 0 - 397) | n= 7 |

Table 4. Measurements of the anterior fontanel and sutures in normocephalic group

| Normocephalic group (n=157) | Anterior fontanel | | Sutures | |
|-----------------------------|-------------------------------------|--------------------------|------------------------|-------------|
| | Transvers diameter | 29.5 mm (range: 0-71.30) | Metopic | 0 (0-11 mm) |
| Anteroposterior diameter | 27.2 mm (range: 0-89.50) | Sagittal | 1.5 mm (range: 0-16.8) | |
| Area | 403 mm ² (range: 0-2945) | Coronal right-side | 1.2 mm (range: 0-15.6) | |
| | | Coronal left-side | 1.3 mm (range: 0-14.2) | |

Median AF and sutures are given

The mean size of AF in the first six months in the Maori/Pasifika group was 580 mm² (21) and with an average value of 693 mm² was in the Australian study (25). In our study, the median of the AF area was 605 ± 514.30 mm² which was higher than the Maori/Pasifika study and lower than the Australian study, which indicates the variation of AF among populations. In a study conducted on 105 human fetuses in pregnant women, AF area increased with the increase in head circumference in the last trimester (26). In our study, unlike the antenatal study, a negative correlation ($p < 0.05$) was found between the fontanel area and head circumference, and as the head circumference increased, the fontanel area decreased.

In the present study, in the normocephalic group the head circumference was statistically significantly larger in boys when compared to girls. In the total population of our study, no statistically significant difference was observed between the diameter and area of AF according to gender groups. While some studies reported significantly larger AF size in boys than girls (27) other studies reported no significant difference in AF size between genders (28-30). This suggests that structural and hormonal differences between the sexes may be related. The fontanel closure that occurs at the age of three months may be within normal limits, but the correlation of the head circumference should exclude the presence of a pathological condition. Craniosynostosis and abnormal brain development are associated with a small fontanel or early fontanelle closure. It is characterized by premature closure of one or more cranial sutures and an abnormal head shape (31). Although fusion of AF before six months or after 18 months is considered abnormal (23, 24, 32, 33) studies have shown that fusion can occur as early as 76 days or as late as 32 months in healthy individuals (7, 16). Early or delayed closure alone is not

necessarily a pathological condition, but may represent a normal variant in a subset of healthy children. Therefore, these patients should be investigated in terms of various syndromes, diseases and toxic exposures that should be taken into account. Although a small AF or early closure may be idiopathic, conditions such as craniosynostosis, hyperthyroidism, abnormal cerebral development or fetal alcohol syndrome, hypoxic ischemic damage, congenital infections, malnutrition, chromosomal abnormality or Apert, Crouzon and Pfeiffer syndrome should be considered in the differential diagnosis (3, 7, 8, 31). In cases with delayed closure or increased AF size, congenital hypothyroidism, achondroplasia, chromosomal abnormalities, skeletal disorders (osteogenesis imperfecta, cleidocranial dysostosis or rickets), increased intracranial pressure (hydrocephalus, intracranial tumor, arteriovenous malformation) and dysmorphogenic syndromes should be considered (3, 16, 24).

In cranial CT study, approximately 30% of the metopic suture at 3-4 months of age, 50% at 5-6 months of age, 70% at 7-8 months of age, 100% in children 9 months and older has been found to be closed (11). In our study, 10% (n = 6/60) of the metopic suture was found to be closed in the first 3 months, 74.3% (n = 26/35) in 7-9 months and 100% (n = 7) closed in 19-24 months; the metopic suture was closing with increasing age. In the present study, metopic suture closure occurs at a later age according to the study data conducted by Vu et al (2001). There is a suggestion that racial, geographical and nutritional factors may play an important role in the American population.

The mean width of the sagittal suture at birth is 5.0 ± 0.2 mm, at one-month of age it is 2.4 ± 0.1 mm and gets narrower over time. In case of early closure of the sagittal suture, the skull becomes long, narrow and wedge-shaped and is called scaphocephalus. Sagittal suture is the most common suture in craniosynostosis (34, 35). In the current study, the median sagittal suture was 3.1 mm (1-16.80) at 1 month old, 2.5 mm (0-4.5) at 2 months old and 1.8 mm (0.80-5.0) at 3 months old, which was consistent with the literature. Similarly, the coronal suture narrows to 2.5 ± 0.1 mm at birth and to 1.3 mm ± 0.1 at 1 month of age. It remains without complete fusion throughout childhood and closes at 24 years old. In case of early closure, deformity such as brachiocephaly occurs (34). In the current study, the coronal suture narrowed from the median 1.7 mm to 1.4 mm on the right and the median from 2.15 mm to 1.70 mm on the left in the first three months. Trigenocephaly was detected in only one case (4%) morphologically on CT. The advantage of the study was quite adequate compared to the literature (in the Maori/Pasifika and NZ-European groups). The disadvantage was that the patients after 24 months were not included in the study. Due to the retrospective nature of the study, only patients with cranial CT examination under emergency conditions were included, and the lack of heterogeneity and standardization between age groups and genders may lead to differences in results between the groups.

The rate of non-AF closure in 19-24 months in the Turkish population living in the Europe-Balkan region was 14.3%, indicating that AF closure is at a later stage. Therefore, retrospective studies involving children over the age of two are needed.

Acknowledgements

None to declare.

Funding

None to declare.

Conflict of interest

No conflict of interest was declared by the authors.

References

- Scheuer L, Black S. Developmental juvenile osteology. 2nd ed. Bath: Elsevier Academic Press; 2000.
- Franklin D, Cardini A, Flavel A, Kuliukas A. Estimation of sex from cranial measurements in a Western Australian population. *Forensic Sci Int*. 2013; 229(1-3): 158.e1-8.
- Duc G, Largo RH. Anterior fontanel: size and closure in term and preterm infants. *Pediatrics* 1986; 78(5): 904-908.
- Omotade OO, Kayode CM, Adeyemo AA. Anterior fontanelle size in Nigerian children. *Ann Trop Paediatr*. 1995; 15(1): 89-91.
- Adeyemo AA, Omotade OO. Variation in fontanelle size with gestational age. *Early Hum Dev*. 1999; 54(3): 207-214.
- Moffett EA, Aldridge K. Size of the anterior fontanelle: three-dimensional measurement of a key trait in human evolution. *Anat Rec (Hoboken)*. 2014; 297(2): 234-239.
- D'Antoni AV, Donaldson OI, Schmidt C, Macchi V, De Caro R, Oskouian RJ, et al. A comprehensive review of the anterior fontanelle: embryology, anatomy, and clinical considerations. *Childs Nerv Syst*. 2017; 33(6): 909-914.
- Kiesler J, Ricer R. The abnormal fontanel. *Am Fam Physician*. 2003; 67(12): 2547-2552.
- Wu T, Li HQ. [Changes of anterior fontanel size in children aged 0 - 2 years]. *Zhonghua Er Ke Za Zhi*. 2012; 50(7): 493-497. Chinese.
- Caffey J. Pediatric x-ray diagnosis. 7th ed. London, England: Year Book Medical Publishers; 1978, p.10-25.
- Vu HL, Panchal J, Parker EE, Levine NS, Francel P. The timing of physiologic closure of the metopic suture: a review of 159 patients using reconstructed 3D CT scans of the craniofacial region. *J Craniofac Surg*. 2001; 12(6): 527-532.
- Nakahara K, Utsuki S, Shimizu S, Iida H, Miyasaka Y, Takagi H, et al. Age dependence of fusion of primary occipital sutures: a radiographic study. *Childs Nerv Syst*. 2006; 22(11): 1457-1459.
- Murai M, Lau HK, Pereira BP, Pho RW. A cadaver study on volume and surface area of the fingertip. *J Hand Surg Am*. 1997; 22(5): 935-941.
- Peters RM, Hackeman E, Goldreich D. Diminutive digits discern delicate details: fingertip size and the sex difference in tactile spatial acuity. *J Neurosci*. 2009; 29(50): 15756-15761.
- Seah SA, Griffin MJ. Thermotactile thresholds at the fingertip: effect of contact area and contact location. *Somatosens Mot Res*. 2010; 27(3): 82-92.
- Pindrik J, Ye X, Ji BG, Pendleton C, Ahn ES. Anterior fontanelle closure and size in full-term children based on head computed tomography. *Clin Pediatr (Phila)*. 2014; 53(12): 1149-1157.
- Agrawal D, Steinbok P, Cochrane DD. Pseudoclosure of anterior fontanelle by wormian bone in isolated sagittal craniosynostosis. *Pediatr Neurosurg*. 2006; 42(3): 135-137.
- Woods RH, Johnson D. Absence of the anterior fontanelle due to a fontanelar bone. *J Craniofac Surg*. 2010; 21(2): 448-449.
- Aisenson MR. Closing of the anterior fontanelle. *Pediatrics*. 1950; 6(2): 223-226.
- Rosset A, Spadola L, Ratib O. OsiriX: an open-source software for navigating in multidimensional DICOM images. *J Digit Imaging*. 2004; 17(3): 205-216.
- Kirkpatrick J, Bowie S, Mirjalili SA. Closure of the anterior and posterior fontanelle in the New Zealand population: A computed tomography study. *J Paediatr Child Health*. 2019; 55(5): 588-593.
- Elder CJ, Bishop NJ. Rickets. *Lancet*. 2014; 383(9929): 1665-1676.
- Amiel-Tison C, Gosselin J, Infante-Rivard C. Head growth and cranial assessment at neurological examination in infancy. *Dev Med Child Neurol*. 2002; 44(9): 643-648.
- De Gaetano HM, De Gaetano JS. Persistent open anterior fontanelle in a healthy 32-month-old boy. *J Am Osteopath Assoc*. 2002; 102(9): 500-501.
- Noble J, Flavel A, Franklin D. Quantification of the timing of anterior fontanelle closure in a Western Australian population. *Aust J Forensic Sci*. 2017; 49(2): 142-153.
- Malas MA, Sulak O. Measurements of anterior fontanelle during the fetal period. *J Obstet Gynaecol*. 2000; 20(6): 601-605.
- Mir NA, Weislaw R. Anterior fontanelle size in Arab children: standards for appropriately grown full term neonates. *Ann Trop Paediatr*. 1988; 8(3): 184-186.
- Faix RG. Fontanelle size in black and white term newborn infants. *J Pediatr*. 1982; 100(2): 304-306.
- Lyll H, Ogston SA, Paterson CR. Anterior fontanelle size in Scottish infants. *Scott Med J*. 1991; 36(1): 20-22.
- Esmaili M, Esmaili M, Ghane Sharbaf F, Bokharaie S. Fontanel Size from Birth to 24 Months of Age in Iranian Children. *Iran J Child Neurol*. 2015; 9(4): 15-23.
- Tunnessen WW, Roberts KB. Signs and symptoms in pediatrics. 3rd ed. Philadelphia, PA: Lippincott Williams & Wilkins; 1999.
- Popich GA, Smith DW. Fontanels: range of normal size. *J Pediatr*. 1972; 80(5): 749-752.
- G/meskel T, Kinfu Y, Worku B. The size of anterior fontanel in neonates and infants in Addis Ababa. *Ethiop Med J*. 2008; 46(1): 47-53.
- Mitchell LA, Kitley CA, Armitage TL, Krasnokutsky MV, Rooks VJ. Normal sagittal and coronal suture widths by using CT imaging. *AJNR Am J Neuroradiol*. 2011; 32(10): 1801-1805.
- Vijay Kumar AG, Agarwal SS, Bastia BK, Shivaramu MG, Honnunar RS. Fusion of Skull Vault Sutures in Relation to Age-A Cross Sectional Postmortem Study Done in 3rd, 4th & 5th Decades of Life. *J Forensic Res*. 2012; 3(10):173.
- Mathur S, Kumar R, Mathur GP, Singh VK, Gupta V, Tripathi VN. Anterior fontanel size. *Indian Pediatr*. 1994; 31(2): 161-164.