

Chronic mucocutaneous candidiasis: a rare disease

Kronik mukokutanöz kandidiyazis: nadir bir hastalık

Tugba Erat¹, Isa An², Murat Ozturk³, Mustafa Aksoy⁴, Erhan Ayhan⁵, Egemen Ucan⁶

¹Dept. of Pediatric Infectious Diseases, Sanliurfa Training and Research Hospital, Sanliurfa, Turkey, ²Dept. of Dermatology, Sanliurfa Training and Research Hospital, Sanliurfa, Turkey, ³Dept. of Dermatology, Health Sciences University, Van Training and Research Hospital, Van, Turkey, ⁴Dept. of Dermatology, Harran University Medical Faculty, Sanliurfa, Turkey, ⁵Dept. of Dermatology, University of Health Sciences Gazi Yasargil Training and Research Hospital, Diyarbakir, Turkey, ⁶Dept. of Dermatology, Dicle University Medical Faculty, Diyarbakir, Turkey

Dear editor,

An 11-year-old female patient was admitted to our clinic with complaints of whiteness in the mouth and crusty lesions on the nose. It was learned that the patient's complaints started two years ago, recurred every 3-4 months, and partially regressed with antifungal treatments. Dermatological examination revealed hypopigmented patches with irregular borders on the face, consistent with vitiligo, and plaques with yellowish crusts on the nose. White plaques consistent with candida infection were seen on the tongue. Yellowish discoloration and hyperkeratosis were observed on the 5th nail of the left hand (Fig. 1). Microscopic examination of the whitish tongue and scrapings of the hyperkeratotic lesion of the nail revealed fungal hyphae and pseudospores. *C. Albicans* was positive in fungal culture made from samples taken from tongue and nail.

Based on the current findings, the patient was diagnosed with chronic mucocutaneous candidiasis (CMC). Complete blood count, liver function tests, blood glucose, calcium, phosphate and magnesium levels,

Human Immunodeficiency virus (HIV) test, thyroid function tests, parathyroid stimulating hormone, follicle stimulating hormone, luteinizing hormone, prolactin, testosterone, corticotropin test and serum cortisol values were within normal ranges. Systemic fluconazole treatment was started for the patient, but since a fixed drug eruption developed 1-day after the drug use, systemic itraconazole treatment was started. At the follow-up, it was observed that the lesions on the oral mucosa were completely resolved, and the lesion on the nail was partially resolved after four weeks. CMC is a rare disease characterized by chronic and refractory infections of the skin, mucous membranes or nails caused by fungi of the genus *Candida*.¹ Some immunological and hormonal abnormalities have been associated with CMC. Factors that predispose the host to CMC infection may be autosomal or acquired.¹⁻³ Genetic mutations, such as mutations in the signal transducer and activator of transcription 1 are known to cause immune system dysfunctions in some forms of CMC. In addition, an imbalance between T helper

Key words: *Candidiasis, mucocutaneous, vitiligo*

Corresponding author: Isa An, Dept. of Dermatology and Venereology, Sanliurfa Training and Research Hospital, Sanliurfa, Turkey.

Phone: + 90 414 317 17 17, E-mail: is_an89@hotmail.com

Received: 22 June 2021 **Accepted:** 13 November 2021

Conflicts of Interest: None

Funding: None

How to cite this article: Erat T, An I, Ozturk M, Aksoy M, Ayhan E, Ucan E. Chronic mucocutaneous candidiasis: a rare disease. *Mucosa* 2022;1:30-32



This work is licensed under a Creative Commons Attribution-NonCommercial 4.0 International License.

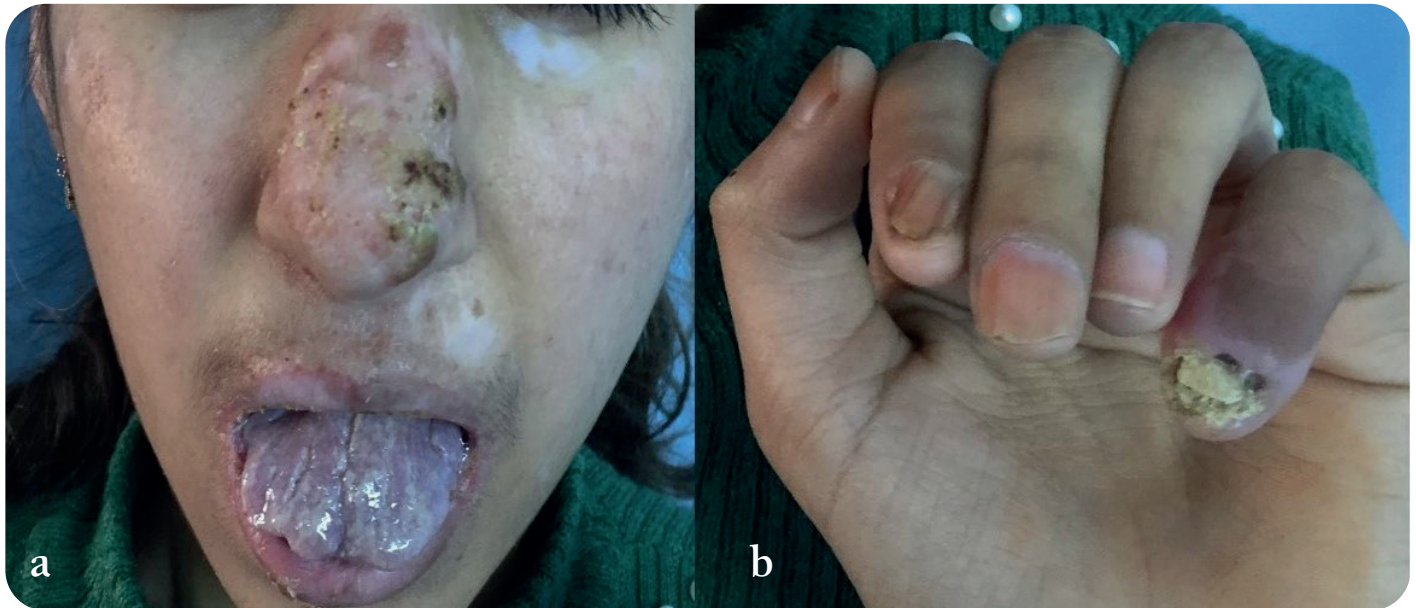


Fig. 1a. Hypopigmented patch with irregular borders on the face and plaques with yellowish crusts on the nose. Whiteness on the tongue consistent with candidiasis in the oral mucosa, **1b.** Yellowish discoloration and hyperkeratosis on the 5th nail of the left hand

I (Th1) and Th2 immune responses has been reported in patients with CMC.^{3,4,6} No genetic analysis was performed in our patient. Immunoglobulin levels were found to be within normal range in our patient.

CMC is seen with equal frequency in men and women and usually occurs in infancy or early childhood.² In patients with CMC, chronic or recurrent candidal infections are seen especially in the nails, skin, mouth and genital mucosa due to *C. albicans*.^{2,4,7} Various disorders such as vitiligo, alopecia, bone marrow abnormalities, myasthenia gravis, thymoma, endocrine dysfunctions and malabsorption syndromes may occur in patients with CMC.^{2,4,8-10} Our patient also had vitiligo. In our patient, vitiligo started 1 year after the diagnosis of mucocutaneous candidiasis.

The diagnosis of CMC is made on the basis of physical examination findings, potassium hydroxide (KOH) preparation results, fungal culture, and history of recurrent and resistant candidiasis.^{2,10} To detect endocrine dysfunctions and other diseases associated with CMC, complete blood count, liver function tests, blood glucose or glycosylated hemoglobin test, serum electrolyte levels, HIV test, thyroid function

tests, follicle stimulating hormone, luteinizing hormone, parathyroid stimulating hormone, prolactin, testosterone, corticotropin test and serum cortisol levels should be measured.^{1,2,4,7-10} No accompanying endocrinopathy was detected in our patient.

Topical treatments are generally not effective in the treatment of CMC. Systemic fluconazole, itraconazole and posaconazole are mostly first-line treatment options. Voriconazole and liposomal amphotericin B are used as second-line therapies. Treatment of CMC can be difficult and recurrence is common following discontinuation of therapy.⁹⁻¹⁰ We treated our patient with itraconazole because fix drug eruption developed due to fluconazole use.

In conclusion, it should be kept in mind that CMC, which is a rare disease, may be seen together with skin diseases such as vitiligo and should be followed closely in terms of accompanying endocrinopathies.

Informed consent: The author certifies that he has obtained all appropriate consent forms from the patient.

Peer-review: Externally peer-reviewed

Authorship contributions:

Conception and design, or analysis and interpretation of data: TE, IA

Drafting the manuscript or revising the content: TE, IA, MO, MA, EA, EU

Final approval of the version to be published: TE, IA, MO, MA, EA, EU

and therapeutic approaches. *Allergol Immunopathol* 2021;49:118-27.

References

1. Shamriz O, Tal Y, Talmon A, Nahum A. Chronic mucocutaneous candidiasis in early life: Insights into immune mechanisms and novel targeted therapies. *Front Immunol* 2020;11:593289.
2. Green L, Dolen WK. Chronic candidiasis in children. *Curr Allergy Asthma Rep* 2017;17:31.
3. Veverka KK, Feldman SR. Chronic mucocutaneous candidiasis: what can we conclude about IL-17 antagonism? *J Dermatolog Treat* 2018;29:475-80.
4. Khosravi AR, Mansouri P, Saffarian Z, Vahedi G, Nikaein D. Chronic mucocutaneous candidiasis, a case study and literature review. *J Mycol Med* 2018;28:206-10.
5. Ostadi V, Sherkat R, Migaud M, et al. Functional analysis of two STAT1 gain-of-function mutations in two Iranian families with autosomal dominant chronic mucocutaneous candidiasis. *Med Mycol* 2021;59:180-8.
6. Wang X, Netea MG, van de Veerdonk FL. Genetics of chronic mucocutaneous candidiasis. *Immunogenetics of fungal diseases*. Springer, 2017, p.85-103.
7. Lehman H, Gordon C. The skin as a window into primary immune deficiency diseases: Atopic dermatitis and chronic mucocutaneous candidiasis. *J Allergy Clin Immunol Pract* 2019;7:788-98.
8. Kirkpatrick CH. Chronic mucocutaneous candidiasis. *Pediatr Infect Dis J* 2001;20:197-206.
9. van de Veerdonk FL, Netea MG. Treatment options for chronic mucocutaneous candidiasis. *J Infect* 2016;72:56-60.
10. Egri N, Esteve-Sole A, Deya-Martinez A, et al. Primary immunodeficiency and chronic mucocutaneous candidiasis: pathophysiological, diagnostic,