



Renal vein transposition in nutcracker syndrome

Yakup Bostanci^{a*}, Yarkin Kamil Yakupoglu^a, Fatih Atac^a, Hasan Cetin^a, Gurkan Genc^b, Hulya Nalcacioglu^b, Ender Ozden^a, Ozan Ozkaya^b, Saban Sarikaya^a

^a Department of Urology, Faculty of Medicine, Ondokuz Mayıs University, Samsun, Turkey

^b Department of Pediatric Nephrology, Faculty of Medicine, Ondokuz Mayıs University, Samsun, Turkey

ARTICLE INFO

ABSTRACT

Article History

Received 15 / 04 / 2013

Accepted 06 / 05 / 2013

* Correspondence to:

Yakup Bostanci,
Department of Urology,
Faculty of Medicine,
Ondokuz Mayıs University, Samsun, Turkey
e-mail: dryakupbostan@yahoo.com

Nutcracker syndrome (NS), caused by compression of the left renal vein (LRV) between the superior mesenteric artery (SMA) and the aorta, results in elevation of LRV pressure and collateral vein development. This meso-aortic compression may present with hematuria, left flank pain and proteinuria. Several treatment options have been described to relieve associated symptoms. In this paper we report a 16-years-old girl with episodic macroscopic hematuria and left flank pain who was diagnosed as NS and successfully treated with LRV transposition.

J. Exp. Clin. Med., 2013; 30:201-203

Keywords:

Hematuria
Left renal vein
Nutcracker syndrome
Transposition

© 2013 OMU

1. Introduction

Nutcracker syndrome (NS) refers to compression of the left renal vein (LRV) by the superior mesenteric artery (SMA) and aorta which results in LRV hypertension, leading to congestion of the left kidney and development of collateral veins. It is a rare clinical entity, and patients typically present with flank pain, hematuria and associated pelvic congestion symptoms. Documentation of a hemodynamically significant pressure gradient across the point of compression is important prior to undertaking treatment. The treatment of NS is controversial and depends on the severity of the symptoms (Ahmed et al., 2006). Conventional treatment has been surgical, commonly through transposition of the LRV to a more caudal location on the inferior vena cava (IVC). Additionally, endovascular approaches, primarily via renal vein stenting, have been described for treatment of this syndrome (Neste et al., 1996). In this paper we aimed to share our experience in a patient diagnosed with NS who was successfully treated with LRV transposition and completely recovered.

2. Case

A 16 years-old-female patient was investigated for recurrent macroscopic hematuria and left flank pain for about 6 months. She had no medical history of note. Physical examination, blood pressure, all blood tests, including complete blood cell count, blood chemistry and blood coagulation profile were normal. Urine analysis revealed 18 red blood cells/high power field. Urine culture was negative. Renal ultrasonography (USG) was normal and Doppler USG of the left kidney revealed LRV dilatation up to the angle between SMA and aorta. The LRV anteroposterior diameters in the hilar and meso-aortic junction were 6 and 3 mm, respectively. Measurements of peak velocities were 23 cm/s in the proximal portion and 150 cm/s in the compressed meso-aortic junction. Cystoscopy disclosed bloody urine draining through the opening of the left ureter. The diagnosis was confirmed with magnetic resonance (MR) angiography by showing pre- and post-narrowing diameters of 7 and 2 mm, respectively (Fig. 1).

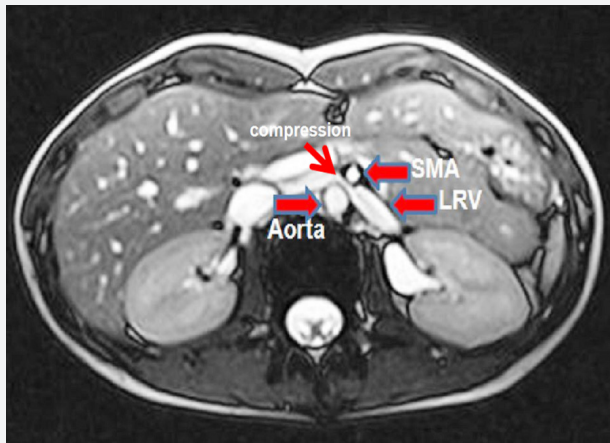


Fig. 1. Contrast-enhanced magnetic resonance (MR) angiographic image shows compression of the LRV between SMA and aorta

After placing the patient in a 45 degrees left lateral decubitus position a transabdominal Chevron incision was made. By the completion of left kidney and hilar dissection three renal arteries and one renal vein which was entrapped between the SMA and aorta were isolated individually. The fibrous bundle between the aorta and SMA was divided and the LRV freed. The left inferior adrenal vein and lumbar veins draining into the LRV were ligated and transected. IVC was completely freed from the surrounding tissues and secured with a silicon vascular tape (Fig. 2A). Following heparinization, bulldog clamps were placed on the renal arteries and the left kidney was peripherally cooled with sterile ice slush. After placing a vascular Satinsky clamp on IVC, the LRV was excised with a small rim of the vena cava wall and irrigated with heparinized saline. The defect on IVC was closed continuously with a running 5/0 polypropilene suture. A 2 cm cavotomy was made 5 cm distal to the native renal vein ostium after placing a side clamp on the IVC. LRV was reanastomosed to IVC in an end to side fashion by using 6/0 polypropilene sutures (Fig. 2B). After releasing the clamps the kidney was reperfused normally (Fig. 2C).

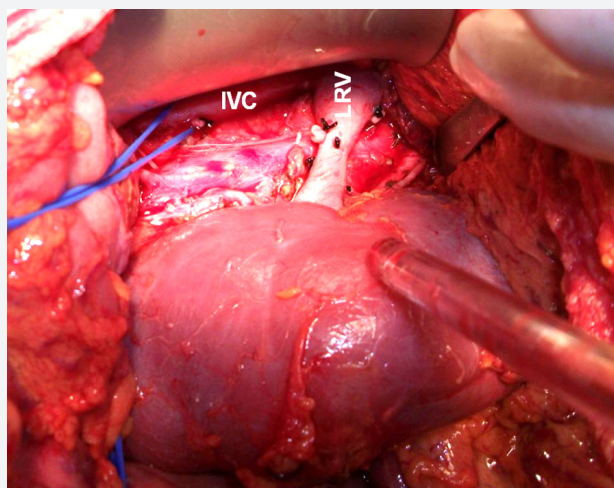


Fig. 2A. Dissected left renal vein and inferior vena cava
Intraoperative photograph of LRV transposition in patient with NS

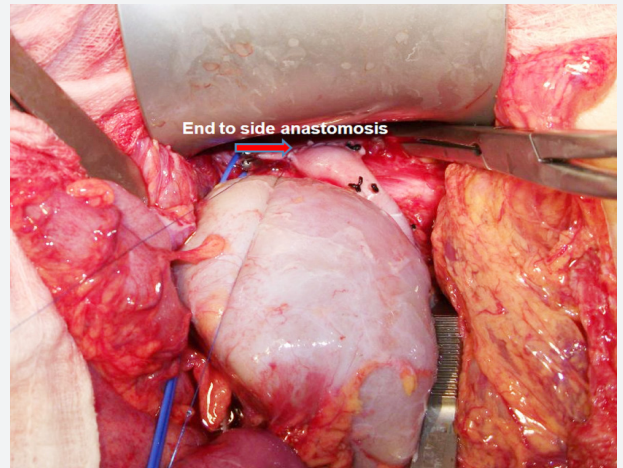


Fig. 2B. Caudal transposition of the LRV with end-to-side caval vein anastomosis

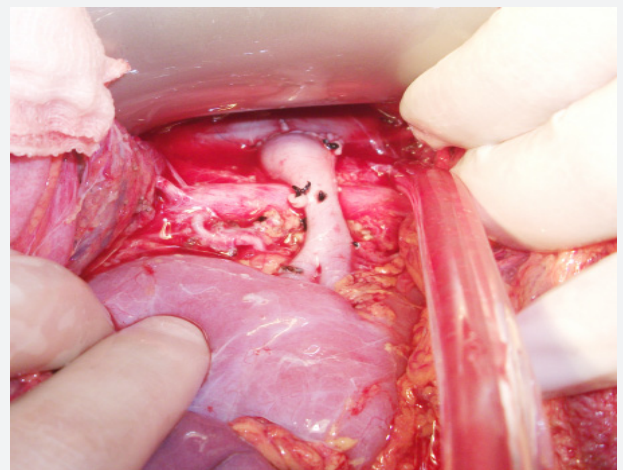


Fig. 2C. Completed anastomosis

Operative and cold ischemia times were 210 mins and 30 mins respectively. Total blood loss was 130 cc. The postoperative course was uneventful, and the patient was discharged without complication on postoperative day 4. One month later the patient was free of symptoms, eGFR values were not changed. Follow-up Doppler USG at 3-months postsurgery revealed the resolution of the compression findings. The anteroposterior diameters of the LRV in the proximal hilar and meso-aortic junction were measured as 7.6 and 3.4 mm, respectively. Measurements of peak velocities were 13 cm/sec in the proximal portion and 60 cm/sec in the meso-aortic portion. In 18 months follow-up, there was no recurrence of symptom.

3. Discussion

The NS is a rare condition, and no largescale experience with such cases has been published. The majority of patients with NS are young or middle aged. The most commonly observed clinical findings in NS are that of flank pain and gross or microscopic hematuria, and orthostatic proteinuria. Additional symptoms stem from associated pelvic congestion seen in more progressive stages of disease and include left lateral vaginal tenderness, dyspareunia, post-coital ache, dysuria, chronic fatigue, and dysmenorrhea. Pelvic, vulvar and scrotal

varices are common (Rudloff et al., 2006). The underlying pathophysiological principle of NS is not fully understood. The association between NS and hematuria was explained by Macmahon and Latorraca in 1954. They documented communications between the dilated venous sinuses and the adjacent renal calyces as an explanation for the hematuria. Compression of the LRV leads to venous hypertension and development of varices in the renal pelvis with resultant hematuria and flank pain. Our patient had only hematuria and left flank pain.

The diagnostic criteria for NS remain diverse. Clinical suspicion of the diagnosis based on history and physical examination should be confirmed with radiographic documentation of compression of the LRV. If a patient has symptoms of unilateral hematuria and orthostatic proteinuria, the association of flank pain with pelvic discomfort and left sided varicocele in the male and pelvic varices in the female constitutes a strong basis for the diagnosis. Hematuria from the left ureter orifice, as confirmed by cystoscopy, in the absence of any other detectable pathologic findings is one of the indicators of the NS (Wang et al., 2009). Doppler USG can be used as the initial diagnostic test in patients with suspected NS, and confirmation should be done with other imaging techniques, if required. Peak velocity ratios between meso-aortic and LRV hilar portion were used to diagnose NS (Shin et al., 2007). Suggested cut-off value is 4.8 for peak velocity ratio and that was 6.5 in our patient. Takebayashi et al., (1999)

indicated that the NS can exist even in nondistended LRV and normal flow also can exist in distended LRV. Therefore, it must be emphasized that the primary diagnostic tool should be the clinical examination (Takebayashi et al., 1999).

Therapeutic options of NS depends on the severity of the symptoms which include observation, open surgical correction or intra-extravascular stenting. Patients with mild and tolerable symptoms may be followed closely without treatment especially in puberty in whom the likelihood of spontaneous remission is higher due possibly to physical development (Tanaka and Waga, 2004). Although the indications for surgical treatment in patients with the NS continue to be debated, persistent macroscopic hematuria, severe pain, progressive renal function impairment, and inefficacy of conservative treatment are potential surgical indications (Wang et al., 2009).

The aim of any intervention is to reduce LRV hypertension. Pastershank reported the first case of surgical treatment of a patient with the NS (Pastershank, 1974). Since then, a wide variety of surgical procedures have been described to achieve venous decompression, the most popular being that of LRV transposition which is associated with excellent short-term and long-term results (Menard, 2009). Considering these facts, we preferred LRV transposition. In selected patients who require surgical treatment for the NS, transposition of the LRV is a safe and effective surgical approach for restoring free renal venous outflow.

REFERENCES

- Ahmed, K., Sampath, R., Khan, M.S., 2006. Current trends in the diagnosis and management of renal nutcracker syndrome: A review. *Eur. J. Vasc. Endovasc. Surg.* 31, 410-416.
- Macmahon, H.E., Latorraca, R., 1954. Essential renal hematuria. *J. Urol.* 71, 667-676.
- Menard, M.T., 2009. Nutcracker syndrome: When should it be treated and how? *Perspect. Vasc. Surg. Endovasc. Ther.* 21, 117-124.
- Neste MG, Narasimham DL, Belcher KK., 1996. Endovascular stent placement as a treatment for renal venous hypertension. *J Vasc Interv Radiol.* 7, 859-861.
- Pastershank, S.P., 1974 Left renal vein obstruction by a superior mesenteric artery. *J. Can. Assoc. Radiol.* 25, 52-54.
- Rudloff, U., Holmes, R.J., Prem, J.T., Faust, G.R., Moldwin, R., Siegel, D., 2006. Meso-aortic compression of the left renal vein (nutcracker syndrome): Case reports and review of the literature. *Ann. Vasc. Surg.* 20, 120-129.
- Shin, J.I., Park, J.M., Lee, J.S., Kim, M.J., 2007. Doppler ultrasonographic indices in diagnosing nutcracker syndrome in children. *Pediatr. Nephrol.* 22, 409-413.
- Takebayashi, S., Ueki, T., Ikeda, N., Fujikawa, A., 1999. Diagnosis of the nutcracker syndrome with color Doppler sonography: Correlation with flow patterns on retrograde left renal venography. *Am. J. Roentgenol.* 172, 39-43.
- Tanaka, H., Waga, S., 2004. Spontaneous remission of persistent severe hematuria in an adolescent with nutcracker syndrome: Seven years' observation. *Clin. Exp. Nephrol.* 8, 68-70.
- Wang, L., Yi, L., Yang, L., Liu, Z., Rao, J., Liu, L., Yang, J., 2009. Diagnosis and surgical treatment of nutcracker syndrome: A single-center experience. *Urology.* 73, 871-876.