



## A typical epiphyseal injury of the distal radius accompanying with median nerve neuropathy

Cem Coskun Avci\*, Necdet Saglam, Tuhun Kurtulmus, Gursel Saka

Department of Orthopedics and Traumatology, Umraniye Education and Research Hospital, Istanbul, Turkey

### ARTICLE INFO

### ABSTRACT

#### Article History

Received 01 / 04 / 2014

Accepted 29 / 06 / 2014

#### \* Correspondence to:

Cem Coskun Avci  
Department of Orthopedics and  
Traumatology,  
Umraniye Education and Research Hospital,  
İstanbul, Turkey  
e-mail: cemcoskunavci@hotmail.com

Distal radius epiphyseal injuries are common fractures in childhood. Displaced physeal fractures are at risk for development of median neuropathy. We have described similar type of physeal injury in two adolescent patients with median nerve neuropathy. Because of the loss of periosteal integrity in metaphyseal region, these injuries are unique which can be accepted as a variant of Salter Harris Type 2. The patients were treated surgically and the median nerve symptoms resolved. At the final follow-up the patients were symptom free and there was no growth disturbance or deformity.

#### Keywords:

Distal radius  
Median nerve neuropathy  
Physeal injury  
Surgical treatment

© 2015 OMU

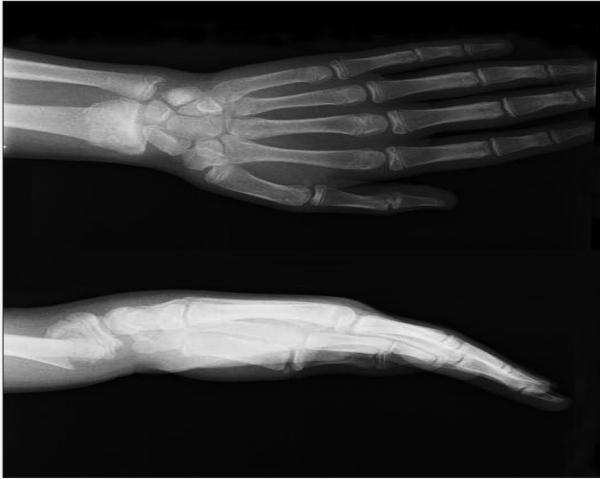
### 1. Introduction

Radius metaphyseal and distal epiphyseal injuries are the most common fractures in childhood (Mizuta et al., 1987). The majority of these fractures heal rapidly and without complications (Peterson, 2013). Nerve injuries are rarely accompanied distal radius fractures. Although ulnar nerve and median nerve neuropathies are less often than in adults, they can occur in pediatric population (Waters et al., 1994). Possible causes of the median nerve injuries are direct trauma to the nerve, ischemic compression from displaced fragments or compartment syndrome developing in the forearm or carpal tunnel. The two cases presented here were evaluated initially as Salter Harris (SH) Type II, but as the free metaphyseal fragment was on the volar surface, a different epiphyseal injury pattern was identified. Interestingly, both cases had

symptoms of median nerve neuropathy before and after reduction . Due to the persistent symptoms of median nerve neuropathy following closed reduction and casting, surgical treatment was performed to the patients on the third day after the trauma.

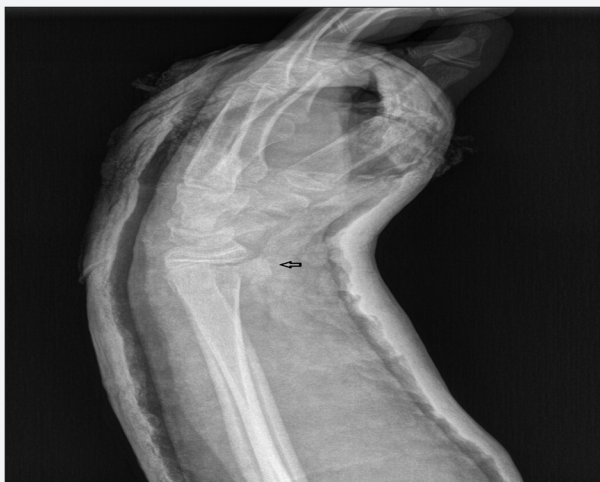### 2. Case 1

Fifteen-year old male patient presented at the Emergency Department after a fall onto his outstretched hand while playing football. The clinical examination revealed a fracture deformity showing apex volar angulation with severe pain and hypoesthesia in the median nerve distribution. After the detailed neurological examination there were absence of light touch and two-point discrimination in the median nerve sensory distribution. On the radiological examination, there

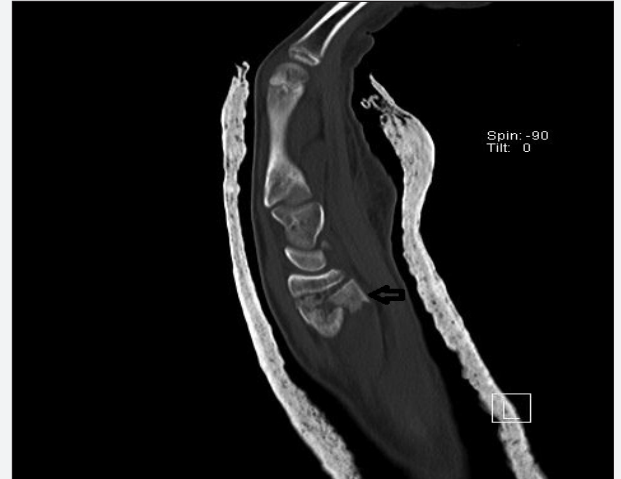

**Fig. 1.** X-rays of the Case 1 at presentation

was a displaced fracture in the distal radius conforming with SH type II epiphyseal injury (Fig. 1). Closed reduction and short arm cast was applied. Although acceptable reduction was obtained, there was a free metaphyseal fragment in the volar side of the distal radius (Fig. 2a-c). During casting, there was not stability which is seen in Type II epiphyseal injuries and tendency to displacement was also determined. The symptoms of median nerve neuropathy did not change after the procedure. The extremity was elevated and the patient was monitored closely. The symptoms had not receded at the end of 24 hours observation, the cast was opened in the form of a plaster splint. There was no marked degree of swelling or tightness in the forearm and volar surface of the wrist. Compartment pressures were measured (Stryker STIC, Mississauga, Ontario, Canada) 7 mmHg in the forearm and 11 mm Hg in the carpal tunnel. Due to the ongoing symptoms of median nerve neuropathy, open reduction was performed via volar incision and plate osteosynthesis was performed (TST, Rakor tibbi aletler, Istanbul) During surgery, it was seen that the capsule and pronator quadratus had been torn thus the fragment had caused the contusion on the nerve. After open reduction of the fragment, osteosynthesis was performed with a locking plate. Carpal tunnel release was not performed because of the normal compartment pressures. The symptoms of the median nerve subsided on postoperative day one. A



**Fig. 2a.** Case 1 after closed reduction and casting

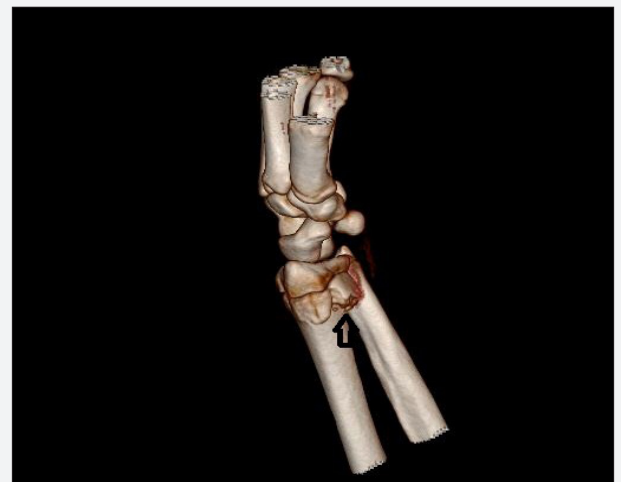

**Fig. 2b.** The appearance of the free volar metaphyseal fragment

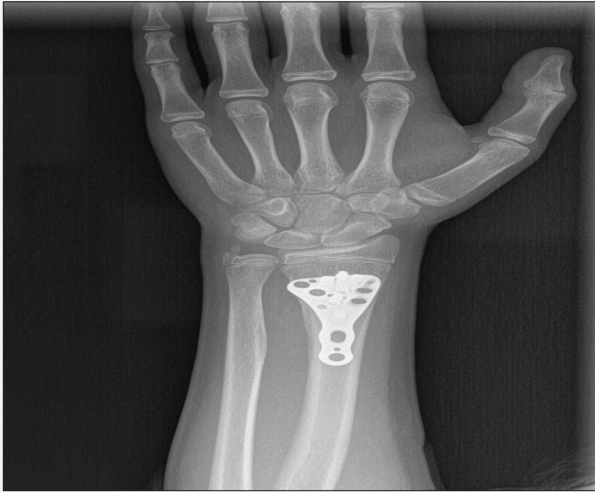brace was used until the stitches were removed on the 15<sup>th</sup> day then after removal of the brace, active wrist movements were begun. At the final follow-up at postoperative 14 months, the patient had pain-free and full range of motion of the wrist. There was no growth disturbance or deformity. Radial inclination, palmar tilt angle and ulnar variance were within normal limits (Fig. 3a-b).

#### Case 2

Sixteen-year old male patient presented at the Emergency Department after a fall on his outstretched hand while playing football. After the radiological examination we have initially evaluated a SH Type II epiphyseal injury in the distal radius (Fig. 4a-b). Prior to reduction, there was severe pain, tingling and hypoesthesia in the median nerve distribution. There was also impaired ligh touch sensation. In addition to these findings two point discrimination was absent and abductor pollicis motor strength was measured 3/5. Immediate closed reduction and short arm cast was applied. As in Case I, X-rays was taken after casting revealed that the metaphyseal fragment was free and the fracture pattern differed from that of a classic Type II epiphyseal injury (Fig. 5a-b). As the complaints had not subsided after 48 hours observation, the cast was opened and compartment pressures were measured. The compartment pressures in the volar forearm and carpal

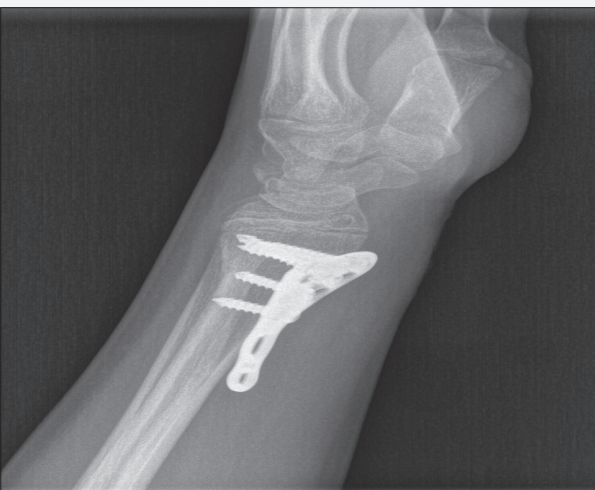

**Fig. 2c.** The appearance of the free volar metaphyseal fragment



**Fig. 3a.** At the 14<sup>th</sup> month after the operation

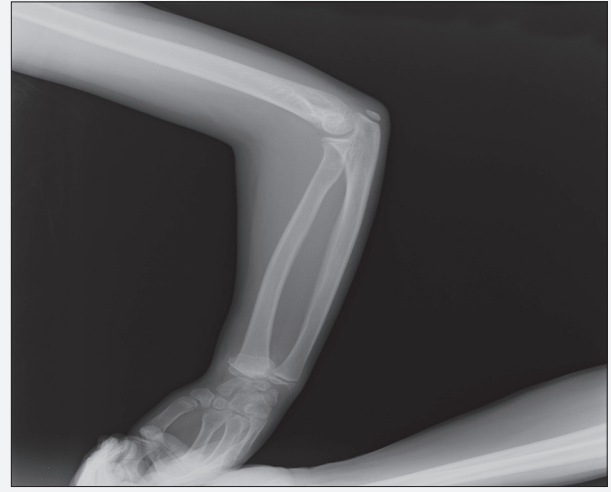tunnel was 6 mmHg and 14 mmHg respectively. The patient did not have any marked swelling or edema but the symptoms were severe and there was a high tendency to displacement, it was decided to surgical treatment. Plate osteosynthesis was performed via volar approach. After exposure of the fracture, the metaphyseal fragment was free, the capsule and pronator teres had been torn. There was no other evident finding except for hematoma in the volar region. The symptoms receded immediately after the surgical treatment and the hypoesthesia was resolved on postoperative second day. Two-point discrimination was measured 15 mm at the 7<sup>th</sup> day. At the follow-up in the 3<sup>rd</sup> week, two-point discrimination was measured below 5mm and abductor pollicis strength was measured 5/5. Final follow-up at 16 months, the patient was symptom-free and there was no deformity (Fig. 6a-b).



**Fig. 3b.** At the 14<sup>th</sup> month after the operation

### 3. Discussion

Distal radius are the most commonly injured bone in childhood (Mizuta et al., 1987; Cheng and Shen, 1993; Khosla et al., 2003). While the metaphyseal fractures are more often in young children, epiphyseal injuries increases with age. Particularly in the prepubertal period, accelerated growth which results in relative osteoporosis has been held responsible for the increase in epiphyseal injuries (Jones et al., 2002). The majority of epiphyseal injuries are stable,

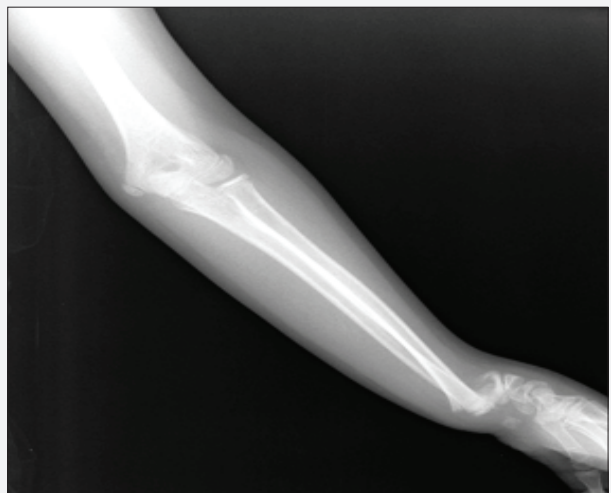

**Fig. 4a.** Case 2 which was evaluated type I epiphyseal injury

they can be treated conservatively. However, in SH Type III and Type IV injuries with an intra-articular pattern, surgical treatment is required (Stutz and Mencia, 2010).

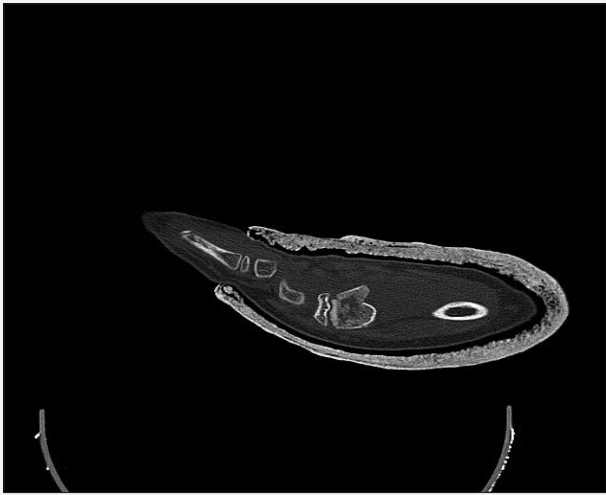For the classification of epiphyseal injuries, although several modifications have been made such as those by Poland, Peterson, Aitken and Ogden, but the most widely-used classification in practice is the Salter Harris (Salter, 1992). But all epiphyseal fracture types does not fit in this system. Therefore, other modifications added different types. These are the perichondrial ring injury called as Type VI by Rang, the metaphyseal fracture extending to the physis called as Type I by Peterson, and the open injuries characterised by loss of a part of the physis named as Type VI by Peterson (Rang, 1993; Peterson, 2013).

The treatment principles for distal radius epiphyseal injuries are generally the same as for metaphyseal fractures. The possibility of displacement in epiphyseal fractures after reduction is less than in metaphyseal fractures. In other words, the internal stability of the epiphyseal fractures is better than that of metaphyseal fractures (Waters et al., 2000). Particularly in SH Type II fractures, surgical treatment is almost never required because of the stability maintained by the metaphyseal fragment. Although the injuries in both of the cases presented here evaluated initially to be Type II but they were completely different from Type II injuries.



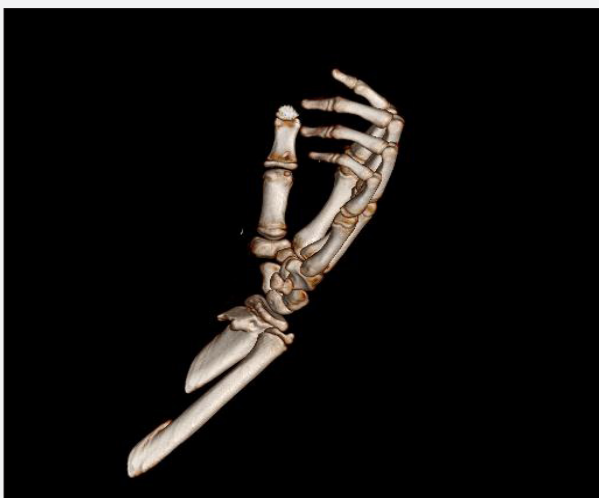
**Fig. 4b.** Case 2 which was evaluated type I epiphyseal injury





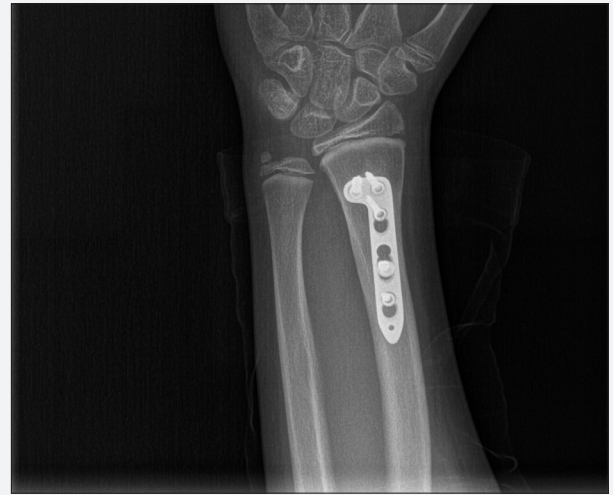**Fig. 5a.** After the closed reduction

The main differences were that radiologically the fragment in the metaphysis was not a classic triangle shape and was separate from the physal line besides the free cubic-shaped, cortical continuity was lost. This difference can be reflected in the stability. Moreover, it was interesting to see median nerve neuropathy in both cases. It is well known that median and ulnar nerve neuropathy may be seen following distal radial fractures (Widmann et al., 1995). But this condition is encountered more in adults and is quite rare in children. The median nerve neuropathy may occur because of neuropraxia or axonothmesis developing from tenting of the nerve or tractional injury caused by the displacement of the fracture fragments. In these types of injuries, if there is no axonal damage, the symptoms regress rapidly after reduction. Neuropathy in the median nerve with increasing compartment pressure or marked hematoma in the volar region may result in acute carpal tunnel syndrome (Widmann et al., 1995; Niver and Ilyas, 2012). Plaster casting with the wrist in flexion or in excessive mould for prevention to displacement prepares a base for the median nerve lesion.



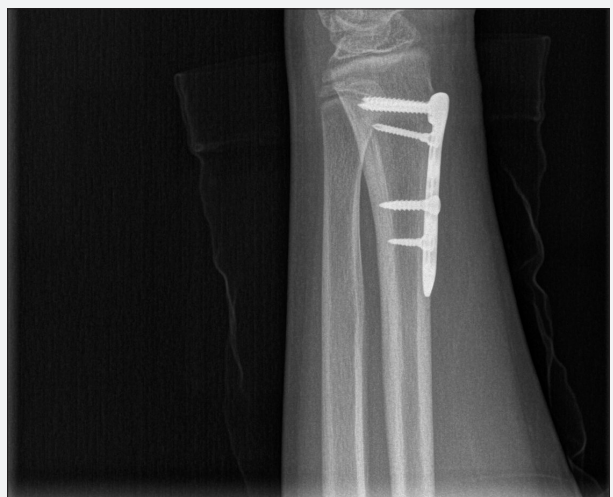**Fig. 5b.** After the closed reduction

In a study by Waters et al. (1994), the treatment and follow-up of 8 children with median nerve neuropathy and Type II epiphyseal injury, he recommended an algorithm for these



**Fig. 6a.** Final radiograph of the Case 2

types of injuries. According to this algorithm, in patients with symptoms of neuropathy persisted after closed reduction, if compartment pressure is measured over 30 mmHg, pin fixation and compartment release was recommended. In the cases presented here, as symptoms persisted after closed reduction and casting, the casts were removed and compartment pressures was measured three times in both the forearm and the carpal tunnel. Although compartment pressures were raised, it was not seen to be at a level that required fasciotomy or carpal tunnel release. The epiphyseal injury pattern was different from Type II injuries and there was potential instability it was thought that there had not been recovery because of the metaphyseal fragment pressure on the median nerve. We had not performed carpal tunnel release during the osteosynthesis procedure, the complaints started to decrease after surgery view that the metaphyseal fragment had caused compression on the median nerve. In both cases, we have preferred the plate osteosynthesis with a volar approach. Surgical treatment is rarely required for epiphyseal injuries in children (Houshian et al., 2004; Jordan and Westacott, 2012). As a general rule, the use of K-wires is recommended for surgical treatment in children (Miller et al., 2005; Jordan and Westacott, 2012). As the use of K-wires on the volar side is not reliable and because of the patients



**Fig. 6b.** Final radiograph of the Case 2

ages, an approach was required like an adult. In addition, the median nerve was directly visible in this approach and stable osteosynthesis was performed. There was no need for cast so decompression was made on the median nerve. Because of the metaphyseal fragment was free and accompanied with median nerve neuropathy, the injuries described in the patients presented here can be accepted as a variant of Type II epiphyseal injuries in the distal radius.

Distal radius fractures are the most common bone injuries

in childhood. The healing is fast and generally without complications. Surgical treatment is rarely required except for the intra-articular forms (Type III and Type IV), In this epiphyseal injury, which can be accepted as a variant of Type II, the periosteal integrity of the metaphyseal fragment had been lost (Thurston Holland Sign). Median nerve lesion accompanying this type of fracture may be a specific event. In contrast to Type II injuries which can almost all be treated conservatively, surgical treatment is required.

## REFERENCES

- Cheng, J.C., Shen, W.Y., 1993. Limb fracture pattern in different pediatric age groups: A study of 3350 children. *J. Orthop. Trauma.* 7, 15-22.
- Houshian, S., Holst, A.K., Larsen, M.S., Torfing, T., 2004. Remodeling of Salter Harris type II epiphyseal plate injury of the distal radius. *J. Pediatr. Orthop.* 24, 472-476.
- Jones, I.E., Williams, S.M., Dow, N., Goulding, A., 2002. How many children remain fracture-free during growth? A longitudinal study of children and adolescent. *Osteoporos. Int.* 13, 990-995.
- Jordan, R.W., Westacott, D.J., 2012. Displaced paediatric distal radius fractures-when should we use percutaneous wires? *Injury.* 43, 908-911. doi: 10.1016/j.injury.2012.01.006.
- Khosla, S., Melton, L.J., Dekutoski, M.B., Achenbach, S.J., Oberg, A.L., Riggs, B.L., 2003. Incidence of childhood distal forearm fractures over 30 years: A population-based study. *JAMA.* 290, 1479-1485.
- Miller, B.S., Taylor, B., Widmann, R.F., Bae, D.S., Snyder, B.D., Waters, P.M., 2005. Cast immobilization versus percutaneous pin fixation, of displaced distal radius fractures in children:a prospective randomized study. *J. Pediatr. Orthop.* 25, 490-494.
- Mizuta, T., Benson, W.M., Foster, B.K., Paterson, D.C., Morris, L.L., 1987. Statistical analysis of the incidence of physeal injuries. *J. Pediatr. Orthop.* 7, 518-523.
- Niver, G.E., Ilyas, A.M., 2012. Carpal tunnel syndrome after distal radius fracture. *Orthop. Clin. North Am.* 43, 521-527. doi: 10.1016/j.ocl.2012.07.021.
- Peterson, H.A., 2013. Physeal fractures: Part 2. Two previously unclassified types. *J. Pediatr. Orthop.* 33, 438-448.
- Rang, M., 1993. Injuries of the epiphysis, growth plate and perichondral ring. *Children's Fractures*, Philadelphia JB. Lippincott: 23.
- Salter, R.B., 1992. Injuries of the epiphyseal plate. *Instr. Course Lect.* 41, 351-359.
- Stutz, C., Mencio, G.A., 2010. Fractures of the distal radius and ulna: Metaphyseal and physeal injuries. *J. Pediatr. Orthop.* 30 suppl; 85-89.
- Waters, P.M., Kolettis, G.J., Schwend, R., 1994. Acute median neuropathy following physeal fractures of the distal radius. *J. Pediatr. Orthop.* 14, 173-177.
- Waters, P.M., Miller, B., Taylor, B., 2000. Prospective study of displaced radius fractures in adolescents treated with casting vs. percutaneous pinning. *AAOS Annual Meeting.*
- Widmann, R.F., Waters, P.M., Reeves, S., 1995. Complications of closed treatment of distal radius fractures in children. Paper presented at the annual meeting of Pediatric Orthopaedic Society of North America.5.