

■ Case Report

## An Unusual Case of Large Vulvar Soft Fibroma In An Adult Patient: A Case Report <sup>§</sup>

### *Erişkin Bir Hastada Nadir Görülen Sıradışı Büyük Vulvar Soft Fibrom Olgusu: Olgu Sunumu*

Orhan Sahin\* 

Department of Obstetrics and Gynecology, Prof. Dr. Cemil Tascioglu City Hospital, Istanbul, Turkey

#### Abstract

A 25-year-old female patient applied to our clinic with a complaint of a growing mass in external genitalia. Patient's complaint began 10 years ago as a small papillomatous lesion in the right labia majora, which increased in size progressively reaching to present size of 20-30 cm in 2-3 years after the first symptom. The mass was prediagnosed as vulvar soft fibroma, and surgical excision was decided. The histopathological findings were compatible with fibroepithelial polyp. The patient had no postoperative complication, and there was no residue or recurrence at the last assessment on postoperative 3rd month.

**Keywords:** Fibroma; Soft Fibroma; Vulva; Vulvar mass

#### Öz

25 yaşında kadın hasta kliniğimize dış genital bölgede büyüyen kitle şikayeti ile başvurdu. Hastanın şikayeti 10 yıl önce sağ labia majorada küçük bir papillomatöz lezyon olarak başlamış ve ilk semptomdan 2-3 yıl sonra giderek artan şekilde 20-30 cm olarak günümüz büyüklüğüne ulaşmıştır. Kitleye vulvar soft fibrom ön tanı konuldu ve cerrahi eksizyona karar verildi. Histopatolojik bulgular fibroepitelyal polip ile uyumluydu. Hastanın postoperatif komplikasyonu yoktu ve postoperatif 3. ayda yapılan son değerlendirmede rezidü veya rekürrens yoktu.

**Anahtar Kelimeler:** Fibrom; Yumuşak fibrom; Vulva; Vulvar kitle

<sup>§</sup> This study was presented as an oral presentation by Dr. Orhan SAHİN at the 1st International KKTC Obstetric and Gynecology Congress, 03-06 December 2020, in Turkish Republic of Northern Cyprus.

Corresponding Author \*: Department of Obstetrics and Gynecology, Prof. Dr. Cemil Tascioglu City Hospital, Istanbul, Turkey.

Email: drorhansahin@gmail.com

ORCID: 0000-0002-7216-3816

DOI: 10.46969/EZH.987398

Received: 26.08.2021

Accepted: 23.02.2022

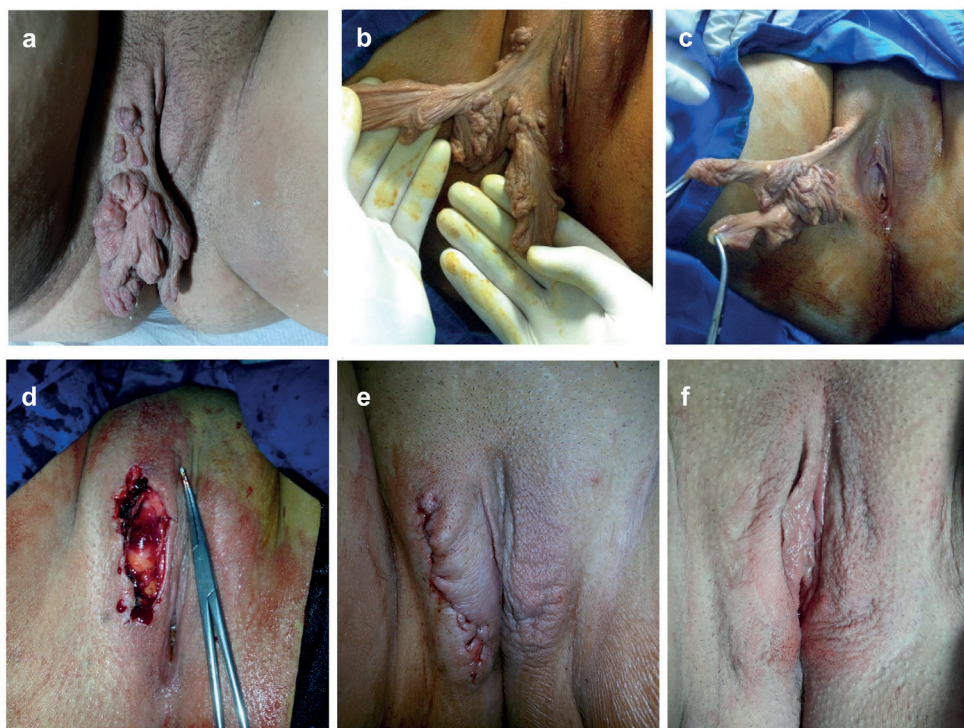
## 1. Introduction

A wide variety of tumors, mostly malignant, can develop in the vulva (1). Among these tumors, fibroma is a very rare and usually benign tumor accounting for less than 0.5% of all gynecologic tumors. Vulvar fibromas originate from connective tissue structures and mostly located in the labium majora. It has a tendency to grow larger and become pedunculated in years, reaching to huge sizes and weights (2-4). Although they are mostly benign tumors, vulvar fibromas adversely affect the sexual life and psychology of the patient, commonly causing social inhibition. Therefore, they should be treated without delay. Only a few cases of vulvar soft fibroma have been reported in the literature (2,4,5). More experience is needed for understanding and management of this debilitating lesion. Here, we present a case of large vulvar fibroma that was effectively treated with surgical excision. The present case is among the largest case reported in the literature. This case report was edited according to the CARE guideline instructions (6).

## 2. Case Presentation

A 25-year-old female patient applied to our clinic with a complaint of a growing mass in external genitalia. She is married for 8 years, and gave birth two times by cesarean section. Patient's

complaint began 10 years ago as a small papillomatous lesion in the right labia majora, which increased in size progressively reaching to present size of 20-30 cm in 2-3 years after the first symptom. During this period, the patient had no obvious complaints in her sexual life. She had no pain, bleeding or other lesional complaints either. She had no similar lesion in rest of her body. She reported that size of the lesion did not change during two pregnancies, and obstetricians who performed cesarean section had no suggestions for the lesion. She did not apply until now since she was embarrassed. Otherwise patient was healthy without any chronic disease or drug usage. She had no history of vaginal birth, episiotomy, vaginismus, vulvar trauma, or family history of tumor. On physical examination, there was a loose, irregular-shaped, papillomatous mass covered with skin, which originated from entire right labia majora axis extending out up to 20-30 cm (Figure 1). The mass was prediagnosed as vulvar soft fibroma, and surgical excision was decided with the request and approval of the patient. No radiological evaluation was performed. Under general anesthesia, when patient was in the lithotomy position, the mass was excised from its base in the labia majora, and wound was closed with sutures (Figure 1). For histopathologic evaluation of the specimen, H&E and HPV immunohistochemistry staining were applied. Under light microscopy, polypoid lesions covered with acanthotic



**Figure 1.** Preoperative images of 25-year-old patient show papillomatous, lobulated, irregular-shaped, loose mass originating from entire right labia majora axis extending out up to 20-30 cm (a-c). Under general anesthesia, the mass was excised from its base in the labia majora (d), and wound was closed with sutures (e). Image of external genitalia at postoperative 3rd month shows complete healing without any residue or recurrence (f).

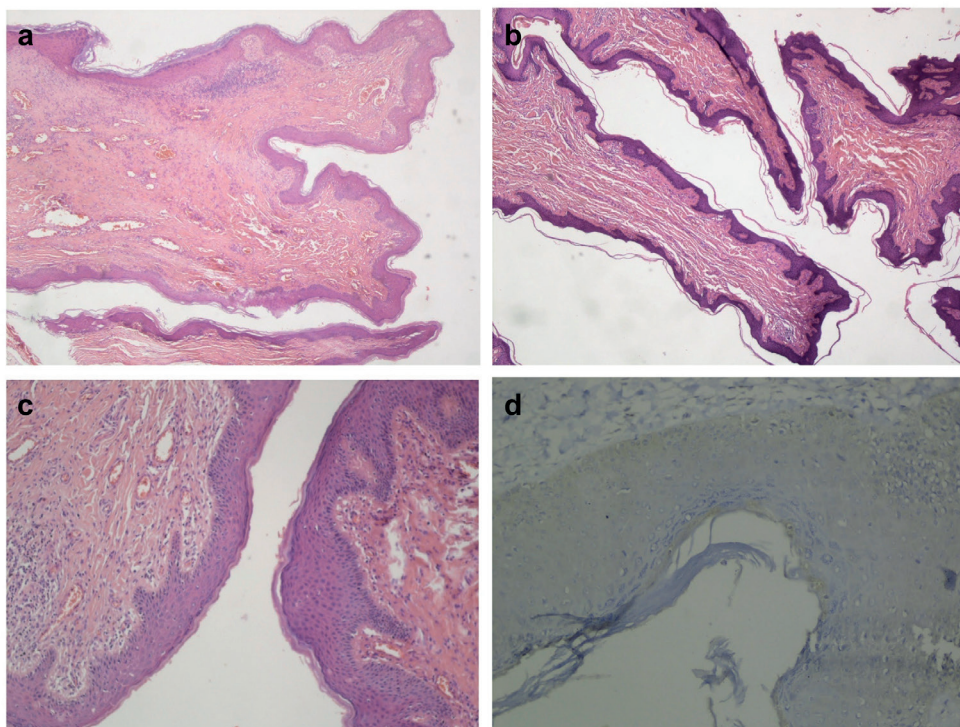
squamous epithelium were seen in serial sections. Stroma was rich in collagen with homogenous structure and had fibroblastic proliferation in loose-lined, randomized bundles. Thick-walled and ectatic vascular proliferations were observed especially in the central part of the lesion. Chronic inflammatory cell infiltration was present in the subepithelial area. Immunohistochemically, there was no positivity for HPV Biocare / BPV1 in squamous epithelial cells. The histopathological findings were compatible with fibroepithelial polyp (Figure 2). The patient had no postoperative complication, and there was no residue or recurrence at the last assessment on postoperative 3rd month (Figure 1).

### 3. Discussion

Vulvar tumors can be classified as cystic or solid according to structure, or epithelial or mesenchymal according to their origin (7). The common types of benign vulvar tumors are Bartholin gland cysts, epidermoid inclusion cysts, syringoma and vascular tumors (7,8). AbdulGaffar et al. (9) retrospectively analysed 115 vulvar specimens of benign lesions and reported a variety of polypoid and papular lesions including epithelial cysts, vascular lesions, glandular neoplasms, endometrioses, and skin lesions due to histologic complexity of the vulva. Majority of benign vulvar lesions are pruritic lesions smaller than 2 cm incidentally diagnosed usually by dermatologists (10).

Since vulvar fibroma is an extremely rare entity, it is not fully characterized. In literature, most cases belong to prepubertal or adolescent age, which is sometimes considered as physiological labial asymmetry of early puberty (11-13). However, it has been reported in all ages including late postmenopausal period (14,15). Due to social inhibition and reluctance to consulting a gynecologist, patients usually seek medical help after a very long period of disease, 5 to 20 years when tumor reaches to huge sizes (5,16). The present patient was 25 years old, and had complaints as long as 10 years. This indicates that, similar to the some previous cases, vulvar fibroma has started during adolescent period in our patient (11-13). Since the patient has not applied to the doctor due to her shyness during these 10 years, the mass reached to very large sizes. However, patient did not report any complaint related to the tumor or her sexual or social life. She also had no evident psychological problems.

The cause of vulvar fibroma is largely unknown. The effect of reproductive hormones was largely eliminated after showing negative estrogen and progesterone receptors on the tumor and upon reports of vulvar fibroma developed in postmenopausal period (2,14,17). Chronic inflammatory process and trauma have been also considered as factors related to some cases of fibroepithelial polyps (18), however, these factors have not been common to vulvar fibroma cases. In the present case,



**Figure 2.** Histopathologic sections of the specimen stained with H&E (a and b, x100; c, x200) showed polypoid lesions covered with acanthotic squamous epithelium. Stroma was rich in collagen with homogenous structure and had fibroblastic proliferation in loose-lined, randomized bundles. Thick-walled and ectatic vascular proliferations were observed especially in the central part of the lesion. Chronic inflammatory cell infiltration was present in the subepithelial area. Immunohistochemically, there was no positivity for HPV Biocare / BPV1 in squamous epithelial cells (d).





no apparent etiologic factor was found. The patient was at reproductive age, but there was no clear evidence for the role of reproductive hormones on development of vulvar fibroma. There was also no history of trauma or injection. Therefore, the etiology of present vulvar fibroma case was unknown. Vulvar fibromas are mesenchymal tumors originating from connective tissue of external genitalia. It is important to distinguish the vulvar fibromas from other vulvovaginal soft tissue tumors that can be potentially malignant (19). The soft tissue tumors that originate from vulvovaginal region and have similar clinical appearance with vulvar fibromas are epithelial stromal polyp, vulvar smooth muscle tumors, cellular angiofibroma, angiomyofibroblastoma, superficial angiofibroma and aggressive angiofibroma (19). Some of these lesions may also arise in other parts of body, as some are unique to vulvovaginal region, such as aggressive angiofibroma, angiomyofibroblastoma, cellular angiofibroma and superficial cervicovaginal myofibroblastoma (20). These mesenchymal lesions usually have overlapping clinical and morphological characteristics, thus produce a diagnostic challenge. However, distinction and definitive diagnosis of vulvar fibromas still depends on histopathological evaluation of H&E-stained specimen. Microscopically, vulvar fibromas are usually hypocellular neoplasms containing spindle-shaped cells in increased collagenous or myxoid stroma without cytologic atypia (13). Histopathological evaluation of the excised specimen in the present case revealed increased loose connective tissue stroma and thin hypercellular papillary epidermis without any sign of atypia, and confirmed the diagnosis of vulvar fibroma.

In addition to vulvovaginal soft tissue tumors, the differential diagnosis of vulvar fibroma includes other benign or malignant vulvar tumors, lymphangioma, inguinal hernia, and vulvar elephantiasis (21,22). Before surgical excision and pathological diagnosis, patient should undergo extensive physical examination of external and internal genitalia and body to eliminate other possible gynecological and distant tumors. Radiologic evaluation of tumor has also been suggested for complete diagnosis before surgery. The extensive fibrous tissues indicated by marked hypointensity on T1- and T2-weighted magnetic resonance images have been proposed to be suggestive of vulvar fibroma (14). On extensive physical examination, our patient had no other tumoral lesion in either gynecological system or rest of body. We haven't performed any radiological study for diagnosis or follow-up. For most of the benign vulvar tumors, follow-up measures and minimum excisions are sufficient without extensive surgery (7). Standard treatment of vulvar fibroma is complete excision. Although some prepubertal cases treated with incomplete excision

developed local recurrence, majority of adult cases treated with complete excision do not recur. Our patient was evaluated three months after the total surgical excision, in which no recurrence or residue was detected. Now, patient was at postoperative 18 months without any complaints or complications. This shows that tumor was effectively treated, however, for early diagnosis of any recurrence, we suggest close follow-up of patient for longer period.

In conclusion, vulvar fibroma is an extremely rare benign tumor of external female genitalia that can reach to huge sizes due to patients' late referral to gynecology clinics. Although it is clinically and morphologically benign tumor, it can cause serious impairment on patients' social, psychological, and sexual life. In order to avoid this unwanted consequence, vulvar fibroma should be excised without delay and also histologically differentiated from other tumors originating from vulva that can be potentially malignant.

#### **Abbreviations and Acronyms**

H&E: Hematoxylin and eosin

HPV: Human Papilloma virüs

BPV1: Bovine papillomavirus type 1

CARE: Consensus-based Clinical Case Reporting

#### **Acknowledgments**

I would like to acknowledge to Pathologist Dr. Tulay Sayilgan for her great contributions.

#### **Author contribution**

Study conception and design: OS; data collection: OS; analysis and interpretation of results: OS; draft manuscript preparation: OS. All authors reviewed the results and approved the final version of the manuscript.

#### **Ethical approval**

The study was approved by the Istanbul Prof. Dr. Cemil Taşcıoğlu City Hospital Clinical Research Ethics Committee (Protocol no. 54/09.02.2021).

#### **Funding**

The authors declare that the study received no funding.

#### **Conflict of interest**

The authors declare that there is no conflict of interest.

#### **Yazar katkısı**

Araştırma fikri ve tasarımı: OS; veri toplama: OS; sonuçların analizi ve yorumlanması: OS; araştırma metnini hazırlama: OS. Tüm yazarlar araştırma sonuçlarını gözden geçirdi ve araştırmanın son halini onayladı.

**Etik kurul onayı**

Bu makale için İstanbul Prof. Dr. Cemil Taşcıoğlu Şehir Hastanesi Klinik Araştırmalar Etik Kurulundan onay alınmıştır (Karar no: 54/09.02.2021).

**Finansal destek**

Yazarlar araştırma için finansal bir destek almadıklarını beyan etmiştir.

**Çıkar çatışması**

Yazarlar herhangi bir çıkar çatışması olmadığını beyan etmiştir.

**Kaynaklar**

1. AbdullGaffar B, Keloth TR, Raman LG, et al.. Unusual benign polypoid and papular neoplasms and tumor-like lesions of the vulva. *Ann Diagn Pathol* 2014; 18:63-70.
2. Bagga R, Dhaliwal LK, Gupta I, Kalra N, Rajwanshi A. Pedunculated cavernous lymphangioma of the vulva. *Acta Obstet Gynecol Scand* 2004; 83:1095-6.
3. Basbug M, Tayyar M, Erdogan N. Fibroma of the vulva and uterine leiomyoma. *Int J Gynaecol Obstet* 1997; 59:55-6.
4. Berlin M, Berlin S. Fibroma of the vulva: a case report. *J Reprod Med* 2007; 52:533-4.
5. Chen DC, Chen CH, Su HY, et al. Huge pedunculated fibroma of the vulva. *Acta Obstet Gynecol Scand* 2004; 83:1091-2.
6. Gagnier JJ, Kienle G, Altman DG, et al. The CARE guidelines: consensus-based clinical case report guideline development. *J Clin Epidemiol.* 2014;67(1):46-51.
7. Filho LLL, Lopes IMRS, Filho ESF, et al. Giant soft fibroma located in the vulva: a case report. *Surg Cosmet Dermatol* 2012; 4:200-2.
8. Goldrat O, Lingier P, Massez A, Noël JC. Prepubertal vulvar fibroma: neoplasm or physiological condition? *J Pediatr Adolesc Gynecol* 2016;29: e67-e70.
9. Heller DS. Benign papular lesions of the vulva. *J Low Genit Tract Dis* 2012; 16:296-305.
10. Heller DS. Benign tumors and tumor-like lesions of the vulva. *Clin Obstet Gynecol* 2015;58: 526-35.
11. Isoda H, Kurokawa H, Kuroda M, et al. Fibroma of the vulva. *Comput Med Imaging Graph* 2002; 26:139-42.
12. Iwasa Y, Fletcher CD. Distinctive prepubertal vulvar fibroma: a hitherto unrecognized mesenchymal tumor of prepubertal girls: analysis of 11 cases. *Am J Surg Pathol* 2004; 28:1601-8.
13. Jayi S, Laadioui M, El Fatemi H,, et al. Vulvar lipoma: a case report. *J Med Case Rep* 2014; 8:203.
14. Kim HS, Kim SM, Lee JD. A Pedunculated Mass on the Thigh. *Am Fam Physician* 2016; 94:1003-1004.
15. Lee MH, Hwang JY, Lee JH, Kim DH, Song SH. Fibroepithelial polyp of the vulva accompanied by lymphangioma circumscriptum. *Obstet Gynecol Sci* 2017; 60:401-4.
16. Maldonado VA. Benign vulvar tumors. *Best Pract Res Clin Obstet Gynaecol* 2014; 28:1088-97.
17. McCluggage WG. A review and update of morphologically bland vulvovaginal mesenchymal lesions. *Int J Gynecol Pathol* 2005; 24:26-38.
18. Najam R, Chowdhury HH, Awasthi S. A Large Fibroma Polyp of Labia Majora—A Case Report. *J Clin Case Rep* 2013; 3:297.
19. Nibhoria S, Tiwana KK, Yadav A. Vulvar syringoma: a rare case report. *J Clin Diagn Res* 2014;8: FD06.
20. Nucci MR, Fletcher CD. Vulvovaginal soft tissue tumours: update and review. *Histopathology* 2000; 36:97-108.
21. Pelit FÇ, Pelit ES. A giant pedunculated fibroma of labia majora: a case report. *Göztepe Tıp Dergisi* 2014; 29:239-21.
22. Velemínský M Jr. Extremely large vulvar fibroma in a 15-year-old girl. *Neuro Endocrinol Lett* 2012; 33:600-2.