



## Case Report | Olgu Sunumu

# HYDATID CYST EMBOLISM MASQUERADING AS PULMONARY NODULE: A CASE REPORT

## PULMONER NODÜL GÖRÜNÜMÜNDE KİST HİDATİK EMBOLİSİ: OLGU SUNUMU

Elmir Dervişoğlu<sup>1\*</sup>, Sevtap Doğan<sup>1</sup>, Nurettin Özgür Doğan<sup>2</sup>

<sup>1</sup>Kocaeli University, Faculty of Medicine, Department of Radiology, Kocaeli, Turkey. <sup>2</sup>Kocaeli University, Faculty of Medicine, Department of Emergency Medicine, Kocaeli, Turkey.



### ABSTRACT

Echinococcosis is still a public health problem in developing countries presenting with hepatic and pulmonary manifestations. Rarely, the clinical condition can manifest with cystic embolization to pulmonary artery and causes significant morbidity. We present a case with hydatid embolism who has multiloculated cystic lesions in the liver and protruding into the right hemithorax through inferior vena cava. She was diagnosed with non-contrast enhanced computed tomography and the diagnosis was confirmed with magnetic resonance imaging because of her allergy to radiocontrast material.

**Keywords:** Echinococcosis, pulmonary embolism, CT, MRI

### ÖZ

Ekinokokkozis, gelişmekte olan ülkelerde hepatik ve pulmoner bulgularla kendini gösteren bir halk sağlığı sorunudur. Nadiren pulmoner artere kistik embolizasyon ile kendini gösterebilir ve önemli morbiditeye neden olabilir. Karaciğerde multiloküle kistik lezyonları olan ve vena kava inferior aracılığı ile sağ hemitoraksa uzanan hidatik emboli olgusu sunuyoruz. Hastanın tanısı kontrastsız bilgisayarlı tomografi ile kondu ve radyokontrast maddeye alerjisi olması nedeniyle manyetik rezonans görüntüleme ile doğrulandı.

**Anahtar Kelimeler:** Ekinokokkozis, pulmoner emboli, BT, MR



## Introduction

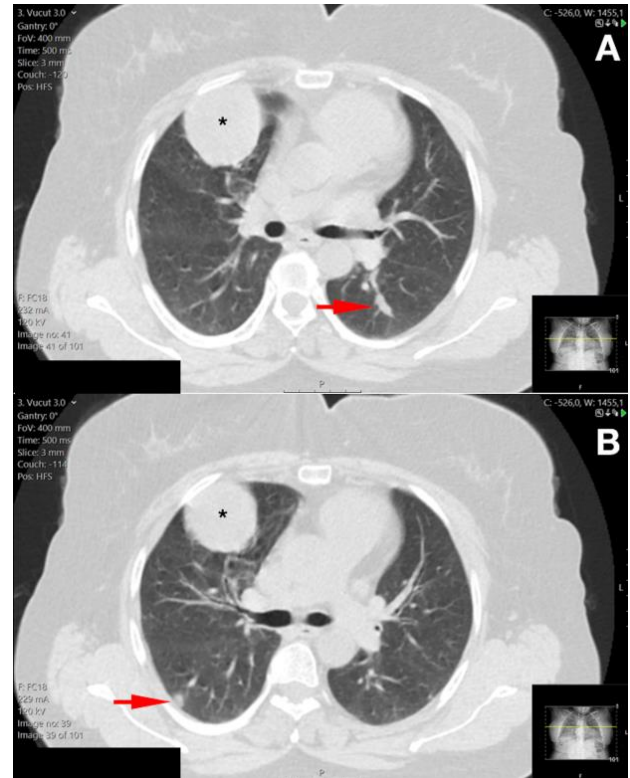
Echinococcosis is a parasitic disease affecting most commonly the liver and caused by the larval forms of *Echinococcus granulosus*. Organisms that reach the gastrointestinal system transported to the liver through the portal vein and it may rarely extend into the heart and pulmonary arteries via the inferior vena cava.<sup>1,2</sup> Two mechanisms are proposed to explain the clinical scenario of pulmonary embolism due to hydatid cyst: It may occur after rupture of a hydatid cyst in the right side of the heart, or rarely a haematogenous dissemination occurred from a hepatic focus by rupturing into the inferior vena cava.<sup>3,4</sup>

The patients with both clinical scenarios may present to the hospital with similar features suggesting pulmonary thromboembolism. Frequent symptoms and findings of hydatid pulmonary embolism are included but not limited to dyspnea, chest pain, cough, hemoptysis and tachycardia.<sup>5-7</sup> It can be mistaken for pulmonary embolism with thrombotic origin based on the abovementioned clinical manifestations. Many cases diagnosed with autopsies and embolisms are mainly the result of mechanical obstruction of the blood flow by vesicles and cysts.<sup>8</sup> Here, we present a case with hydatid pulmonary embolism who was allergic to radiocontrast material and diagnosed with non-contrast enhanced computed tomography (CT) and magnetic resonance imaging (MRI).

## Case Report

A 53-year-old female patient was admitted to our hospital with abrupt onset of dyspnea. Three months ago, a pulmonary nodule was detected in her left lung and a follow-up visit was scheduled. In addition, she was known to have a hydatid cyst in the liver and operated two times for her hepatic lesion. She had also asthma for 20 years and her physical examination was unremarkable except decreased lung sounds at the current presentation. Electrocardiogram was normal. All blood investigations were normal except for eosinophilia (21%), increased CRP (10, 6) and presence of antihydatid cyst antibody (measured by ELISA). The patient did not have any predisposing factors of thromboembolic diseases or any findings of deep vein thrombosis in the lower extremities.

Before her initial visit to our hospital, she presented to another medical center for her dyspnea and a non-contrast enhanced chest CT was obtained due to her allergy to radiocontrast material. On CT imaging, there was a multiloculated cystic lesion in the dome of the liver, adjacent to the inferior vena cava, protruding into the right hemithorax. Besides there were small peripheral nodules, some of them had a branching pattern (Figure 1). These nodules seemed to be questionable after learning about her history of echinococcus and a non-contrast enhanced MRI of chest was ordered to confirm the diagnosis.



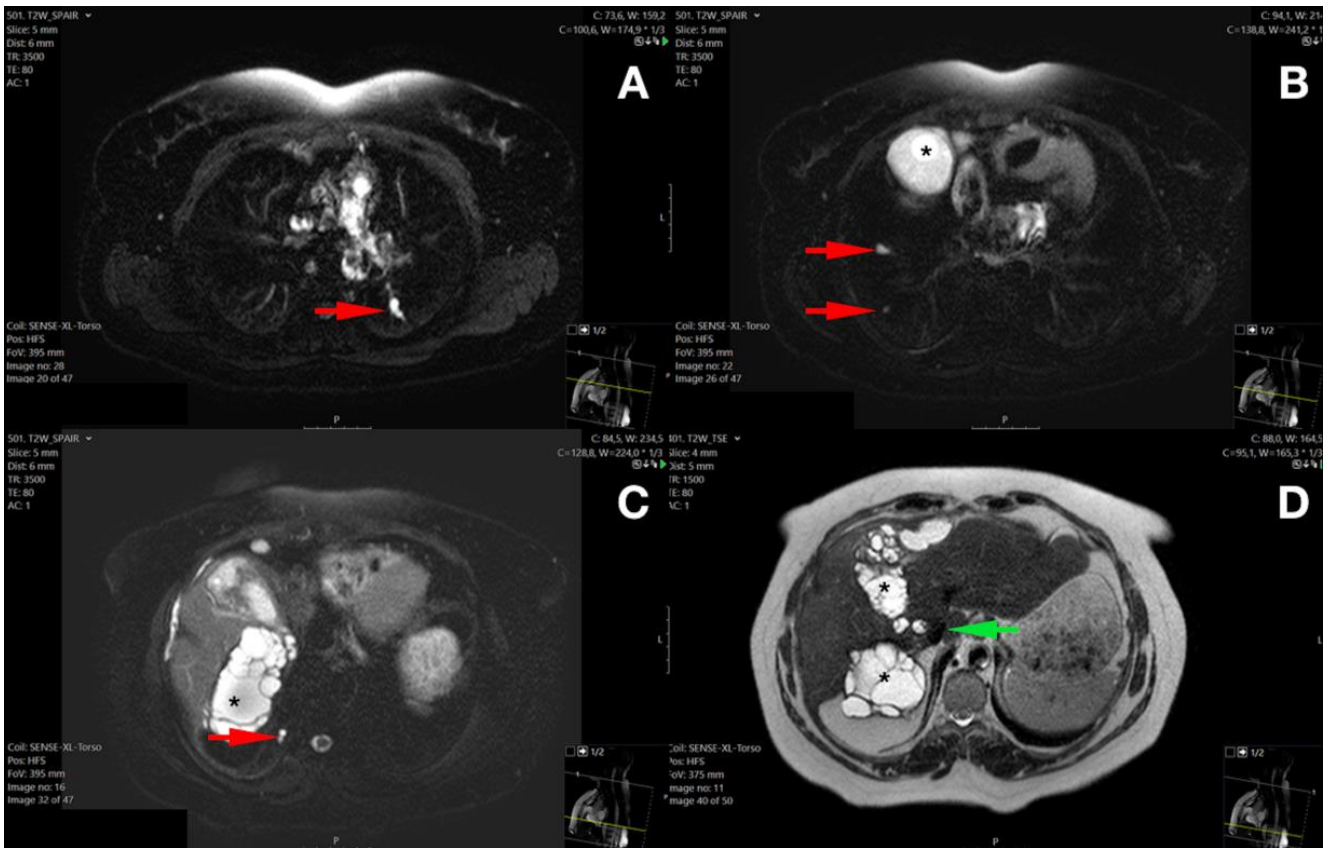
**Figure 1.** Axial, non-contrast enhanced CT images of the patient (before treatment). Red arrows: Cystic embolus mimicking peripheral nodules, Asterisk: Cystic lesion at the liver

The non-enhanced MRI revealed multiple T2-weighted bright branching cystic lesions in the arterial tree (Figure 2). There was luminal widening of subsegmental branches of the pulmonary arteries. The cystic nature of the embolism material revealed hydatid daughter cyst embolism as a complication. The patient was discharged with oral albendazole therapy because she refused any surgical intervention. After four months, a follow-up chest CT without contrast revealed a significant regression in pulmonary lesions (Figure 3).

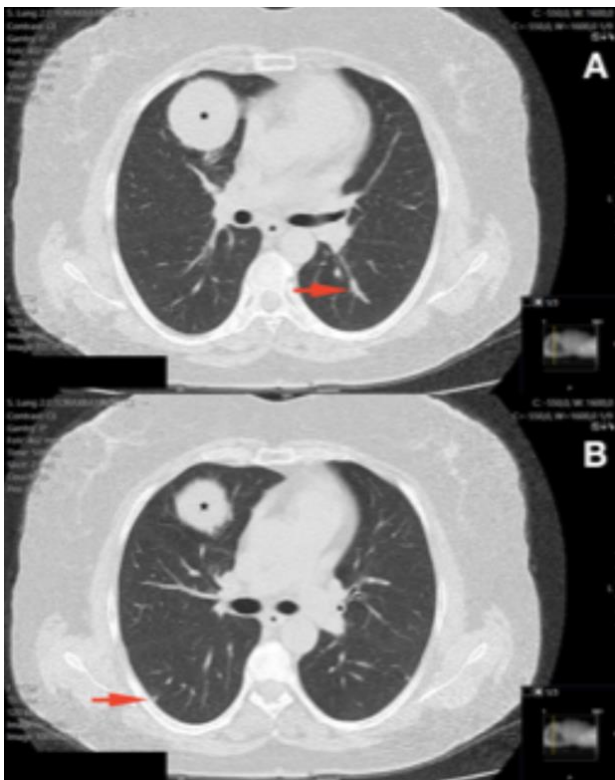
## Discussion

Hydatid cystic disease is an important infection that is still a common health problem in developing countries. It is mostly endemic in agricultural areas in the Middle East, South America, Oceania, and along the Mediterranean coast where dogs are frequently used to care for large herds.<sup>9</sup> Pulmonary embolism secondary to hydatid cystic disease is quite rare and difficult to diagnose in many clinical settings.

The clinical signs and symptoms of hydatid cyst embolism significantly vary, however there are three different clinical courses after embolism: Acute cor pulmonale and sudden death, subacute pulmonary hypertension with death in less than a year; and chronic pulmonary hypertension.<sup>2</sup> Some patients suffer from pulmonary hypertension and the clinical course deteriorates by acute embolic episodes.<sup>10</sup>



**Figure 2.** Axial, T2-weighted MR images show bright branching cystic lesions at the lungs (red arrows). Vena cava inferior (green arrow; hypointense) is very close to cystic lesion at the liver. Asterisk: Multiloculated cystic lesion at the liver.



**Figure 3.** Axial, non-contrast enhanced CT images of the patient (after treatment). Red arrows: Decreased size of oval & round shaped lesions at the lung, Asterisk: Cystic lesion at the liver

In our case, pulmonary hypertension was not developed due to acute treatment after the onset of her symptoms. She was appropriately managed after her presentation and surgical intervention was not required in the follow-up period.

An important clinical challenge in our case was the use of imaging modalities without contrast material. This was a mandatory diagnostic way for our patient due to contrast allergy. Initially, the chest CT was evaluated and it revealed the cystic lesions in the liver and some peripheral nodules in her lungs. However, the T2-weighted images in MRI study of chest demonstrated that they were actually cystic lesions in arterial tree.

Both chest CT and MRI angiography can clearly disclose vascular occlusion of the pulmonary artery and its branches in hydatid cyst embolism.<sup>1</sup> On chest CT, hydatid cysts in pulmonary vascular territories appear as fluid attenuation and round intravascular mass lesions like our patient.<sup>9</sup> This may cause enlargement of the affected vessels and mimic pulmonary nodules in the present case. Some authors argue that, MRI can give more detailed information comparing chest CT imaging.<sup>7</sup> MRI imaging of the involved arteries shows hypointense signals on the T1-weighted images and hyperintense signals on the T2-weighted images.<sup>9</sup> In our case, a non-contrast CT scan caused to suspect hydatid cysts and T2-weighted MRI facilitated the definitive diagnosis.

In patients with pulmonary hydatid embolism, surgical removal of the intraarterial hydatidosis and embolization surgery are preferred methods. Medical treatment with

albendazole or mebendazole in addition to surgery should be considered.<sup>8,9</sup> Our patient refused any surgical intervention and only albendazole was given to her. Although surgical removal was considered generally safe, it may be complicated by rupture of the cysts and anaphylactic shock.<sup>2</sup>

Hydatid embolism is a rare complication of hydatid cystic disease. This diagnosis should be kept in mind in hepatic hydatidosis patients with suspicious pulmonary complaints. Chest CT with or without contrast material gives important information about this condition and MRI may confirm the diagnosis.

### Compliance with Ethical Standards

Consent was obtained from the patient.

### Conflict of Interest

The authors declare no conflicts of interest.

### Author Contribution

The authors contributed equally to this work.

### Financial Disclosure

None

### References

1. Mnari W, Zrig A, Maatouk M, Golli M. Acute pulmonary embolism due to hydatid cysts. *Int J Infect Dis.* 2014;25:142-144. doi:10.1016/j.ijid.2014.03.1385
2. Jorens PG, Van Marck E, Snoeckx A, Parizel PM. Nonthrombotic pulmonary embolism. *Eur Respir J.* 2009;34:452-474. doi:10.1183/09031936.00141708
3. Odev K, Acikgözoglu S, Gormüs N, Aribas OK, Kiresi DA, Solak H. Pulmonary embolism due to cardiac hydatid disease: imaging findings of unusual complication of hydatid cyst. *Eur Radiol.* 2002;12:627-633. doi:10.1007/s003300100988
4. Yagüe D, Lozano MP, Lample C, Nuñez ME, Sánchez F. Bilateral hydatid cyst of pulmonary arteries: MR and CT findings. *Eur Radiol.* 1998;8:1170-1172. doi:10.1007/s003300050528.
5. Yuan Z, Maihesuti M, Wenya L, Cheng Z, Biyemu N, Haitao W. Rare reason for pulmonary embolism: one case of pulmonary hydatid cyst and review of the literature. *J Thromb Thrombolysis.* 2015;40:126-129. doi:10.1007/s11239-014-1147-5
6. Salem R, Zrig A, Joober S, Jellali MA, et al. Pulmonary embolism in echinococcosis: two case reports and literature review. *Ann Trop Med Parasitol.* 2011;105:85-89. doi:10.1179/136485911X12899838413466
7. Savaş G, Coşgun MS, Karabıyık U, Oğuzhan A. A Rare Cause of Pulmonary Embolism: Hydatid Cyst. *Am J Respir Crit Care Med* 2017;196:386-387. doi:10.1164/rccm.201612-2459IM
8. Şahpaz A, İrez A, Gülbeyaz H, Şener MT, Kök AN. Non-thrombotic Pulmonary Embolism Due to Liver Hydatid Cyst: A Case Report. *Balkan Med J.* 2017;34:275-277. doi:10.4274/balkanmedj.2016.0391
9. Namn Y, Maldjian PD. Hydatid cyst embolization to the pulmonary artery: CT and MR features. *Emerg Radiol.* 2013;20:565-568. doi:10.1007/s10140-013-1130-z
10. Buz S, Knosalla C, Mulahasanovic S, Meyer R, Hetzer R. Severe chronic pulmonary hypertension caused by pulmonary embolism of hydatid cysts. *Ann Thorac Surg.* 2007;84:2108-2110. doi:10.1016/j.athoracsur.2007.04.081