



ORJİNAL MAKALE / ORIGINAL ARTICLE

Balıkesir Sağlık Bilimleri Dergisi / BAUN Sağ Bil Derg
Balıkesir Health Sciences Journal / BAUN Health Sci J
ISSN: 2146-9601- e ISSN: 2147-2238
Doi: <https://doi.org/10.53424/balikesirsbd.989313>



Histopathological Examination of the Effects of Tocilizumab and Dexamethasone on the Liver in Rats of Oleic Acid induced Acute Lung Injury

Funda TERZİ ¹, Hüseyin Serkan EROL ²

¹ Kastamonu University, Faculty of Veterinary Medicine, Department of Pathology

² Kastamonu University, Faculty of Veterinary Medicine, Department of Biochemistry

Geliş Tarihi / Received: 31.08.2021, Kabul Tarihi / Accepted: 04.01.2022

ABSTRACT

Objective: This study, it was aimed to examine the effects of Tocilizumab and Dexamethasone on the liver in rats in which the acute lung injury model was created with Oleic acid. **Materials and Methods:** Thirty-six male rats were used as study material and were divided into six groups as Control, OA, TCZ and DEX. All groups except the control group received OA intravenously and after OA injections other compounds were administered intravenously (DEX 0.1 mg/kg and DEX 10 mg/kg, TCZ 2 mg/kg and TCZ 4 mg/kg). **Results:** It was determined that hydropic degeneration increased in hepatocytes in OA+DEX 10 group rats compared to other groups ($p<0.05$). Vacuole formation in hepatocytes in OA+TCZ 2 and 4 groups was found to be similar to the control group ($p<0.05$). In addition, necrosis in hepatocytes and narrowing of sinusoids were detected more severely in OA+DEX (0.1 and 10 mg/kg) groups. **Conclusion:** As a result, it was determined that high dose Dexamethasone had hepatotoxic effect. It is thought that liver function tests should be performed and evaluated to determine the hepatotoxic effects of drugs to be used in the treatment of patients with COVID/19 ARDS.

Keywords: ARDS, Tocilizumab, Dexamethasone, Liver, Rat.

Oleik Aside Bağlı Akut Akciğer Hasarı Modeli Oluşturulan Ratlarda Tocilizumab ve Dekametazon'un Karaciğer Üzerine Etkilerinin Histopatolojik Olarak İncelenmesi

ÖZ

Amaç: Bu çalışmada, oleik asit ile akut akciğer hasarı modeli oluşturulan ratlarda Tocilizumab ve Dekametazon'un karaciğer üzerindeki etkilerinin incelenmesi hedeflenmiştir. **Gereç ve Yöntem:** Çalışma materyalini otuz altı erkek rat oluşturdu ve CN, OA, TCZ ve DEX olmak üzere altı gruba ayrıldı. Kontrol grubu dışındaki tüm gruplar intravenöz olarak OA verildi. OA enjeksiyonlarından sonra diğer bileşikler intravenöz olarak uygulandı (DEX 0.1 mg/kg ve DEX 10 mg/kg, TCZ 2 mg/kg ve TCZ 4 mg/kg). **Bulgular:** OA+DEX 10 grubu sıçanlarda hepatositlerde hidropik dejenerasyonun diğer gruplara göre arttığı belirlendi ($p<0.05$). OA+TCZ 2 ve 4 gruplarında hepatositlerde vakuol oluşumu kontrol grubuna benzer bulundu ($p<0.05$). Ayrıca OA+DEX (0,1 ve 10 mg/kg) gruplarında hepatositlerde nekroz ve sinüzoidlerde daralma daha şiddetli olduğu görüldü. **Sonuç:** Yüksek doz deksametazonun hepatotoksik etki gösterdiği belirlendi. COVID-19/ARDS hastalarının tedavisinde kullanılacak ilaçların hepatotoksik etkilerinin belirlenmesi için karaciğer fonksiyon testlerinin yapılması ve değerlendirilmesi gerektiği düşünülmektedir.

Anahtar Kelimeler: ARDS, Tocilizumab, Dekametazon, Karaciğer, Rat.

Sorumlu Yazar / Corresponding Author: Funda TERZİ, Kastamonu University, Faculty of Veterinary Medicine, Department of Pathology, Kastamonu, Türkiye.

E-mail: fundaterzi@kastamonu.edu.tr

Bu makaleye atf yapmak için / Cite this article: Terzi, F., & Erol, H.S. (2022). Histopathological examination of the effects of tocilizumab and dexamethasone on the liver in rats of oleic acid induced acute lung injury. *Balıkesir Health Science Journal*, 11(2):167-172. <https://doi.org/10.53424/balikesirsbd.989313>

©Copyright 2022 by the Balıkesir Sağlık Bilimleri Dergisi.



BAUN Sağ Bil Derg 2022 OPEN ACCESS <https://dergipark.org.tr/tr/pub/balikesirsbd>

This work is licensed under a Creative Commons Attribution-NonCommercial 4.0 International License

INTRODUCTION

Acute respiratory distress syndrome (ARDS) is a serious clinical disorder that causes pulmonary edema and oxygenation disorder as a result of increased permeability of alveolar epithelium and pulmonary capillary endothelial cells due to various causes such as sepsis, shock, trauma, pneumonia, endotoxemia, burns, and organ transplantation (Koh, 2014). Liver function is increasingly recognized as an important determinant in the pathogenesis of ARDS and also significantly influences the prognosis of these patients (Herrero et al., 2020). It is also thought to exacerbate liver diseases in ARDS patients, with mechanisms including hypoxemia, activation of systemic inflammatory responses, and cardiovascular changes (Patterson et al., 2013; Yang et al., 2019). In these patients, deficiencies occur in many organs and may lead to death (Akella et al., 2014; Schwartz et al., 1989).

ARDS animal model is created with oleic acid (OA) (Schuster, 1994), lipopolysaccharide-induced injury (LPS-intratracheal or intravenous) (Wiener-Kronish et al., 1991), bleomycin (Moore & Hogaboam, 2008), ventilator-induced lung injury (VILI) (Slutsky & Ranieri, 2013). Among these models, OA is preferred as the most similar to ARDS in humans. (Matute-Bello et al., 2008). OA is directly toxic to endothelial cells in the lung. (Beilman, 1995). It also triggers intracellular pathways resulting in lung cell death, causing necrosis and inducing capillary congestion and interstitial/interalveolar edema (Matute-Bello et al., 2008). In addition, oleic acid 18:1(n-9), a monounsaturated fatty acid (MUFA), induces steatosis in hepatocytes with decreased insulin sensitivity by stimulating the accumulation of metabolites derived from increased ROS in hepatocytes, fatty acid synthesis, and fat-derived metabolites that inhibit insulin signaling and action (Browning & Horton, 2004; Canbay et al., 2005).

Corticosteroids are considered to represent an effective treatment for patients with ARDS (Sun et al., 2019). Glucocorticoids are widely used as therapeutic agents against many diseases, including inflammation, asthma exacerbations, autoimmune diseases, allergic reactions, inflammatory bowel disease, autoimmune diseases and cancers (Wan et al., 2012). Due to its strong anti-inflammatory effect, dexamethasone is widely prescribed and this drug has significant side effects such as hyperglycemia, insulin resistance, fatty liver, and type II diabetes (Patel et al., 2011).

Today, antibody therapy is promising in the treatment of many diseases, with the development of technology. TCZ (Actemra®; Hoffman-La Roche, Basel, Switzerland) is a neutralizing humanized monoclonal antibody against the human interleukin-6 (IL-6) receptor capable of blocking soluble and membrane-bound receptors (Drucker et al., 2010; Oldfield et al., 2009). TCZ is widely used in the treatment of diseases such as rheumatoid arthritis

(Tanaka et al., 2010), juvenile rheumatoid arthritis (Sukharomana et al., 2019), inflammatory bowel disease, adult-onset Still's disease (AOSD). Also, in recent years, TCZ Tocilizumab (TCZ), has been preferred in the treatment of ARDS caused by Covid-19 (Luo et al., 2020). TCZ has been found to cause some important side effects such as elevation of liver enzymes and low-density lipoprotein, infections, and gastrointestinal perforations (Muhović et al., 2020). This study, it was aimed to histopathological examine the effects of TCZ and Dexamethasone on the liver in rats with Acute Lung Injury Model created with oleic acid.

MATERIAL AND METHODS

Experimental methods

The animals were purchased from Bolu Abant İzzet Baysal University Medical Experimental Research and The Experimental Study was carried out at Kastamonu University in 2021.

ARDS model in rats was with oleic acid (OA). The experimental study material was formed thirty-six male Wistar albino rats, 12 weeks old, and weighing from 200 to 220 g. Rats were kept in at temperatures ranging between 19 °C and 22 °C (21±2 °C), with a standard 12-h light-dark cycle. Animals were separated into 6 groups as follows:

Grup 1: Control (CN)

Grup 2: Oleic Acid (OA)

Grup 3: OA+TCZ 2 mg/kg (OA + TCZ 2)

Grup 4: OA+TCZ 4 mg/kg (OA + TCZ 4)

Grup 5: OA+DEX 0.1mg/kg (OA+DEX 0.1)

Grup 6: OA+DEX 10 mg/kg (OA+DEX 10)

50 µL of OA was dissolved in 250 µL of 1% BSA and administered intravenously to all groups except the control group. Six hours after intravenous administration of oleic acid, 2 doses of dexamethasone and TCZ were given 6 hours apart. Rats were euthanized by cervical dislocation 24 hours after oleic acid administration. Systemic necropsy of rats was performed and liver was fixed in 10% formaldehyde solution.

Histopathological methods

The tissues were cut and moved to the cassettes. Routine pathology follow-up was done after the cassettes were cleaned under running water, and paraffin was blocked. Hematoxylin-eosin staining was conducted on 5 µm thick pieces of paraffin blocks cut in a microtome and mounted on adhesive slides filled with a coverslip. Sections were examined under a light microscope. Histopathological changes, degree and extent of change: -(0): none, +(1): mild occurrence, ++(2): moderate occurrence, +++(3): according to severe occurrence as stated by Erol et al. (2019).

Statistical analysis

IBM SPSS Statistics 25.0 software was used for comparing the histopathology results. All values are presented as the mean±standard deviation. Histopathological data were analyzed using non-

parametric statistics using the Kruskal-Wallis H test followed by the Mann-Whitney U test as post-hoc. The value of $p < 0.05$ is considered statistically significant.

Ethical considerations

This study was approved by Local Ethics Committee of Animal Experiments of Kastamonu University (Approval no: E.50144-6/31).

RESULTS

Histopathological results

Hydropic degeneration, which is defined as the swelling of hepatocytes with water, was observed in other groups except for the control and OA+TCZ 2 groups (Fig 1A, D, E and Fig 2A, B). It was determined that hydropic degeneration in hepatocytes was statistically significantly higher in rats using dexamethasone 10 mg/kg (Fig 1D) together with oleic

acid ($p < 0.05$). In the OA+TCZ 4 groups (Figure 1C), mild swelling was detected in hepatocytes, while vacuole formation was found to be the same as in the control group. Vacuole formation in hepatocytes of OA and OA+DEX 0.1 group rats was more severe than other groups (Fig 1D) ($p < 0.05$). Necrosis in hepatocytes and narrowing of sinusoids were found to be statistically significantly increased in OA+DEX 0.1 and OA+DEX 10 groups compared to OA+TCZ 2 and OA+TCZ 4 groups (Fig 2C and Fig 3A). Among the experimental groups, congestion (Fig 3C) with Kupffer cells, which are the defense cells of the liver, was not statistically significant. While cell infiltration in the portal area was determined in all groups, it was more severe in the liver of rats given only OA+DEX 10 group (Fig 3B) ($p < 0.05$).

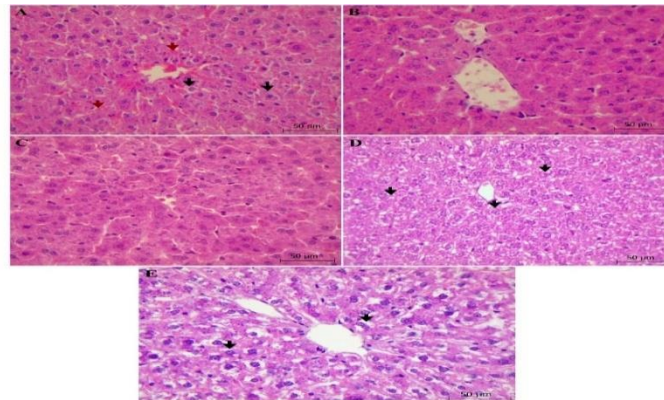


Figure 1. Hematoxylin-eosin staining. Liver. A) Mild hydropic degeneration (black arrow) in hepatocytes and congestion (red arrows) in sinusoids, (OA Group). B) Mild swelling of hepatocytes and narrowing of sinusoids. Bar: 50µm, (OA+TCZ 2 Group). C) Mild swelling in hepatocytes and increase in Kupffer cells. Bar: 50µm (OA+TCZ 4 Group). D) Moderate hydropic degeneration (black arrows) and vacuole formation in hepatocytes (OA+DEX 0.1 Group). Bar: 50µm. E) Severe hydropic degeneration of hepatocytes (black arrows) and narrowing of sinusoids (OA+DEX 10 Group). Bar: 50µm

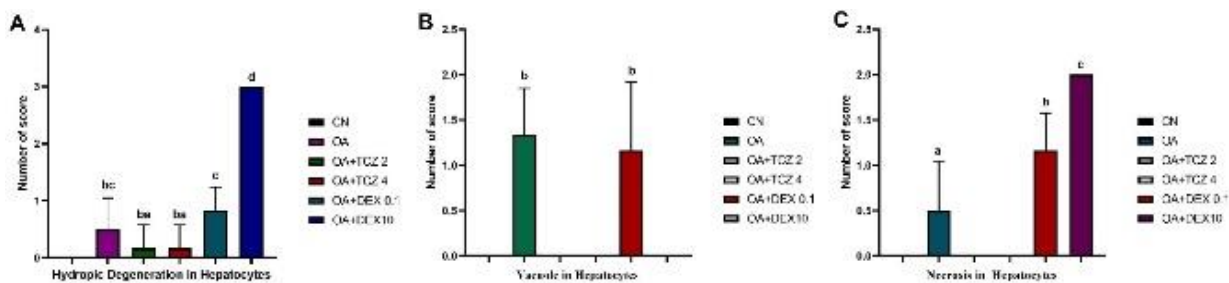


Figure 2. Effects of Tocilizumab (TCZ) and Dexamethasone (DEX) on the liver hydropic degeneration in hepatocytes (A), vacuole in hepatocytes (B), and necrosis in hepatocytes (C) in ARDS rats. Data presented mean value ± standard deviation, significant differences ($p < 0.05$) are marked with a, b, c and d superscripts.

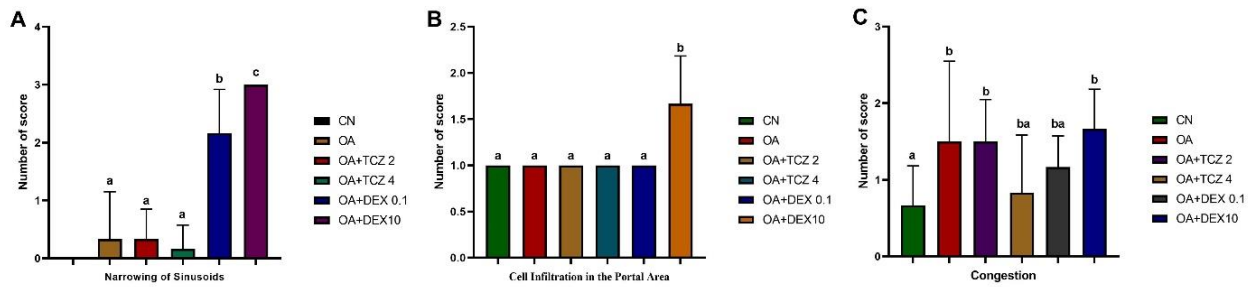


Figure 3. Effects of Tocilizumab (TCZ) and Dexamethasone (DEX) on the liver sinusoids narrowing (A), cell infiltration in the portal area (B), and congestion (C) in ARDS rats. Data presented mean value \pm standard deviation, significant differences ($p < 0.05$) are marked with a, b and c superscripts.

DISCUSSION

Oleic acid (OA; cis-9-octadecenoic acid), a monounsaturated fatty acid, is preferred in ARDS models because it causes pulmonary vascular endothelial cell damage, increased capillary membrane permeability, polymorph nuclear leukocyte infiltration, activation of oxidation enzymes, and cytokine release (Beilman, 1995; Koxsel et al., 2005) and it is used in the evaluation of potential therapeutic agents against disease (Bulmuş et al., 2013; Lee et al., 2011). OA also causes fat accumulation in hepatocytes and hepatic steatosis (Kang et al., 2013; Ziamajidi et al., 2013). In the study, vacuole formation was detected in hepatocytes of rats treated with oleic acid, and these histopathological findings were similar to previous studies (Ducheix et al., 2017; Ziamajidi et al., 2013) on the effect of oleic acid on hepatocytes.

The liver is the main organ in the metabolism and excretion of toxins and drugs, modulation of immune and host defense (Herrero et al., 2020), making it a higher risk of toxic damage by drugs and/or their metabolites compared to other organs (Bleibel et al., 2007). Many drugs are known to cause degeneration of hepatocytes, steatosis and steatohepatitis and cirrhosis (Kleiner, 2009). High-dose therapeutic use of glucocorticoids may lead to hepatic enlargement, steatosis, or glycogenosis with extensive glycogen deposition in hepatocytes (Mikiewicz et al., 2017). Dexamethasone, a synthetic glucocorticoid, can affect some important functions of liver hepatocytes, such as the induction of cytochrome P4503A (CYP3A4) and the oxidative metabolism of xenobiotics, glucose metabolism, and the urea cycle (Okun et al., 2015; Pascussi et al., 2001). In addition, Dexamethasone is thought to affect the Sodium-Potassium (Na-K) pump by reducing the number of mitochondria, oxidative phosphorylation, and active respiration in hepatocytes (Roussel et al., 2004). This may cause electrolyte imbalance, increase osmotic pressure, swelling of cells, leakage of hydrolytic enzymes, and macromolecular crowding (Abdelhalim & Jarrar, 2011). In the study, it was determined that hydropic degeneration in hepatocytes was higher in rats using oleic acid and dexamethasone 10 mg/kg compared to other groups ($p < 0.005$). It shows that the use of high-dose dexamethasone causes hydropic degeneration by

disrupting the Sodium-Potassium (Na-K) balance in the hepatocyte.

TCZ, an IL-6 receptor blocking agent recommended for the treatment of COVID-19, is widely used in the treatment of autoimmune disorders such as refractory rheumatoid arthritis and systemic juvenile idiopathic arthritis (sJIA) (De Benedetti et al., 2012). TCZ is a recombinant humanized, anti-human monoclonal antibody against soluble and membrane-bound interleukin 6 receptors (IL-6R). Headache and hypertension are the most common side effects of tocilizumab, and hepatotoxicity, ranging from rare to serious drug-induced liver injury (DILI), occurs (Muhović et al., 2020). Data on hepatotoxicity in patients using tocilizumab in the treatment of COVID-19 are reported to be limited (Serviddio et al., 2020). However, mild to moderate elevations of transaminases and drug-induced liver injury have been reported in patients treated with tocilizumab (Serviddio et al., 2020). Mahamid et al. (2011) detected histopathological findings such as focal haemorrhagic necrosis, steatosis, and perisinusoidal fibrosis without cellular infiltrates in the liver biopsy of a patient treated with tocilizumab. In this study, unlike other studies, a histopathologic examination of the liver of rats, administered tocilizumab (2 and 4 mg/kg) together with oleic acid, no vacuole formation and necrosis were observed, but only mild swelling was detected in cells.

CONCLUSION

In the study, it was determined that high doses of dexamethasone had a hepatotoxic effect. It is thought that liver function tests should be performed and evaluated in order to determine the hepatotoxic effects of drugs to be used in the treatment of patients with COVID/19 ARDS.

Acknowledgement

The authors would like to thank everyone who contributed to this work.

Conflict of Interest

The authors declared that there is no conflict of interest.

Author Contributions

Plan, design: FT, HSE; **Material, methods and data collection:** FT, HSE; **Data analysis and comments:** FT, HSE; **Writing and corrections:** FT, HSE.

Funding

This study was supported by the Kastamonu Scientific Research project (Project No: KÜ-BAP01/2019-12).

REFERENCES

- Abdelhalim, M. A. K., & Jarrar, B. M. (2011). Gold nanoparticles induced cloudy swelling to hydropic degeneration, cytoplasmic hyaline vacuolation, polymorphism, binucleation, karyopyknosis, karyolysis, karyorrhexis and necrosis in the liver. *Lipids in Health and Disease*, *10*(1), 1-6. <https://doi.org/10.1186/1476-511x-10-166>
- Akella, A., Sharma, P., Pandey, R., & Deshpande, S. B. (2014). Characterization of oleic acid-induced acute respiratory distress syndrome model in rat. *Indian Journal of Experimental Biology*, *52*(7):712-9. <https://doi.org/10.1016/j.toxicon.2015.02.004>
- Beilman, G. (1995). Pathogenesis of oleic acid-induced lung injury in the rat: distribution of oleic acid during injury and early endothelial cell changes. *Lipids*, *30*(9), 817-823. <https://doi.org/10.1007/bf02533957>
- Bleibel, W., Kim, S., D'Silva, K., & Lemmer, E. R. (2007). Drug-induced liver injury. *Digestive Diseases and Sciences*, *52*(10), 2463-2471. <https://doi.org/10.1007/s10620-006-9472-y>
- Browning, J. D., & Horton, J. D. (2004). Molecular mediators of hepatic steatosis and liver injury. *The Journal of clinical investigation*, *114*(2), 147-152. <https://doi.org/10.1172/jci200422422>
- Bulmuş, F. G., Gürsu, M. F., Muz, M. H., Yaman, İ., Bulmuş, Ö., & Sakin, F. (2013). Protective effects of alpha-lipoic acid on oleic acid-induced acute lung injury in rats. *Balkan medical journal*, *30*(3), 309. <https://doi.org/10.5152/balkanmedj.2013.8426>
- Canbay, A., Gieseler, R., Gores, G., & Gerken, G. (2005). The relationship between apoptosis and non-alcoholic fatty liver disease: an evolutionary cornerstone turned pathogenic. *Zeitschrift für Gastroenterologie*, *43*(02), 211-217. <https://doi.org/10.1055/s-2004-813744>
- De Benedetti, F., Brunner, H. I., Ruperto, N., Kenwright, A., Wright, S., Calvo, I., Cuttica, R., Ravelli, A., Schneider, R., & Woo, P. (2012). Randomized trial of tocilizumab in systemic juvenile idiopathic arthritis. *New England Journal of Medicine*, *367*(25), 2385-2395. <https://doi.org/10.1056/nejmoa1112802>
- Drucker, C., Gewiese, J., Malchow, S., Scheller, J., & Rose-John, S. (2010). Impact of interleukin-6 classic and trans-signaling on liver damage and regeneration. *Journal of Autoimmunity*, *34*(1), 29-37. <https://doi.org/10.1016/j.jaut.2009.08.003>
- Ducheix, S., Montagner, A., Polizzi, A., Lasserre, F., Regnier, M., Marmugi, A., Benhamed, F., Bertrand-Michel, J., Mselli-Lakhal, L., & Loiseau, N. (2017). Dietary oleic acid regulates hepatic lipogenesis through a liver X receptor-dependent signaling. *PLoS One*, *12*(7), e0181393. <https://doi.org/10.1371/journal.pone.0181393>
- Erol, N., Saglam, L., Saglam, Y. S., Erol, H. S., Altun, S., Aktas, M. S., & Halici, M. B. (2019). The protection potential of antioxidant vitamins against acute respiratory distress syndrome: a rat trial. *Inflammation*, *42*(5), 1585-1594. <https://doi.org/10.1007/s10753-019-01020-2>
- Herrero, R., Sánchez, G., Asensio, I., López, E., Ferruelo, A., Vaquero, J., Moreno, L., de Lorenzo, A., Bañares, R., & Lorente, J. A. (2020). Liver-lung interactions in acute respiratory distress syndrome. *Intensive Care Medicine Experimental*, *8*(1), 1-13. <https://doi.org/10.1186/s40635-020-00337-9>
- Kang, O., Kim, S., Seo, Y., Joung, D., Mun, S., Choi, J., Lee, Y., Kang, D., Lee, H., & Kwon, D. (2013). Curcumin decreases oleic acid-induced lipid accumulation via AMPK phosphorylation in hepatocarcinoma cells. *European Review for Medical and Pharmacological Sciences*, *17*(19), 2578-2586. <https://doi.org/10.1039/d0fo00594k>
- Kleiner, D. E. (2009). The pathology of drug-induced liver injury. (Ed.), (Eds.). *Seminars in liver disease*. <https://doi.org/10.1055/s-0029-1240005>
- Koh, Y. (2014). Update in acute respiratory distress syndrome. *Journal of Intensive Care*, *2*(1), 1-6. <https://doi.org/10.1186/2052-0492-2-2>
- Koksel, O., Kaplan, M. B., Ozdulger, A., Tamer, L., Degirmenci, U., Cinel, L., Bastürk, M., & Kanik, A. (2005). Oleic acid-induced lung injury in rats and effects of caffeic acid phenethyl ester. *Experimental Lung Research*, *31*(5), 483-496. <https://doi.org/10.1080/01902140590918876>
- Lee, J. Y., Moon, J. H., Park, J. S., Lee, B.-W., Kang, E. S., Ahn, C. W., Lee, H. C., & Cha, B. S. (2011). Dietary oleate has beneficial effects on every step of non-alcoholic fatty liver disease progression in a methionine and choline-deficient diet-fed animal model. *Diabetes & Metabolism Journal*, *35*(5), 489. <https://doi.org/10.4093/dmj.2011.35.5.489>
- Luo, P., Liu, Y., Qiu, L., Liu, X., Liu, D., & Li, J. (2020). Tocilizumab treatment in COVID-19: a single center experience. *Journal of Medical Virology*, *92*(7), 814-818. <https://doi.org/10.1002/jmv.25801>
- Mahamid, M., Paz, K., Reuven, M., & Safadi, R. (2011). Hepatotoxicity due to tocilizumab and anakinra in rheumatoid arthritis: two case reports. *International Journal of General Medicine*, *4*, 657. <https://doi.org/10.2147/ijgm.s23920>
- Matute-Bello, G., Frevert, C. W., & Martin, T. R. (2008). Animal models of acute lung injury. *American Journal of Physiology-Lung Cellular and Molecular Physiology*, *295*(3), L379-L399. <https://doi.org/10.1152/ajplung.00010.2008>
- Mikiewicz, M., Otrocka-Domagala, I., Paździor-Czapula, K., & Rotkiewicz, T. (2017). Influence of long-term, high-dose dexamethasone administration on proliferation and apoptosis in porcine hepatocytes. *Research in Veterinary Science*, *112*, 141-148. <https://doi.org/10.1016/j.rvsc.2017.03.018>
- Moore, B. B., & Hogaboam, C. M. (2008). Murine models of pulmonary fibrosis. *American Journal of Physiology-Lung Cellular and Molecular Physiology*, *294*(2), L152-L160. <https://doi.org/10.1152/ajplung.00313.2007>

- Muhović, D., Bojović, J., Bulatović, A., Vukčević, B., Ratković, M., Lazović, R., & Smolović, B. (2020). First case of drug-induced liver injury associated with the use of tocilizumab in a patient with COVID-19. *Liver International*, 40(8), 1901-1905. <https://doi.org/10.1111/iv.14516>
- Okun, J. G., Conway, S., Schmidt, K. V., Schumacher, J., Wang, X., de Guia, R., Zota, A., Klement, J., Seibert, O., & Peters, A. (2015). Molecular regulation of urea cycle function by the liver glucocorticoid receptor. *Molecular Metabolism*, 4(10), 732-740. <https://doi.org/10.1016/j.molmet.2015.07.006>
- Oldfield, V., Dhillon, S., & Plosker, G. L. (2009). Tocilizumab. *Drugs*, 69(5), 609-632. <https://doi.org/10.2165/00003495-200969050-00007>
- Pascussi, J. M., Drocourt, L., Gerbal-Chaloin, S., Fabre, J. M., Maurel, P., & Vilarem, M. J. (2001). Dual effect of dexamethasone on CYP3A4 gene expression in human hepatocytes: sequential role of glucocorticoid receptor and pregnane X receptor. *European Journal of Biochemistry*, 268(24), 6346-6358. <https://doi.org/10.1046/j.0014-2956.2001.02540.x>
- Patel, R., Patel, M., Tsai, R., Lin, V., Bookout, A. L., Zhang, Y., Magomedova, L., Li, T., Chan, J. F., & Budd, C. (2011). LXR β is required for glucocorticoid-induced hyperglycemia and hepatosteatosis in mice. *The Journal of Clinical Investigation*, 121(1), 431-441. <https://doi.org/10.1172/jci41681>
- Patterson, E., Yao, L., Ramic, N., Lewis, J., Cepinskas, G., McCaig, L., Veldhuizen, R., & Yamashita, C. (2013). Lung-derived mediators induce cytokine production in downstream organs via an NF- κ B-dependent mechanism. *Mediators of Inflammation*, 2013. <https://doi.org/10.1155/2013/586895>
- Roussel, D., Dumas, J.-F., Simard, G., Malthiery, Y., & Ritz, P. (2004). Kinetics and control of oxidative phosphorylation in rat liver mitochondria after dexamethasone treatment. *Biochemical Journal*, 382(2), 491-499. <https://doi.org/10.1042/bj20040696>
- Schuster, D. P. (1994). ARDS: clinical lessons from the oleic acid model of acute lung injury. *American Journal of Respiratory and Critical Care Medicine*, 149(1), 245-260. <https://doi.org/10.1164/ajrccm.149.1.8111590>
- Schwartz, D. B., Bone, R. C., Balk, R. A., & Szidon, J. R. (1989). Hepatic dysfunction in the adult respiratory distress syndrome. *Chest*, 95(4), 871-875. <https://doi.org/10.1378/chest.95.4.871>
- Serviddio, G., Villani, R., Stallone, G., Scioscia, G., Foschino-Barbaro, M. P., & Lacedonia, D. (2020). Tocilizumab and liver injury in patients with COVID-19. *Therapeutic Advances in Gastroenterology*, 13, 1756284820959183. <https://doi.org/10.1177/1756284820959183>
- Slutsky, A. S., & Ranieri, V. M. (2013). Ventilator-induced lung injury. *New England Journal of Medicine*, 369(22), 2126-2136. <https://doi.org/10.1056/nejmra1208707>
- Sukharomana, M., Udomittipong, K., Ruangchira-Urai, R., & Charuvanij, S. (2019). Nonspecific interstitial pneumonia in refractory systemic juvenile idiopathic arthritis responded to tocilizumab treatment. *Asian Pacific Journal of Allergy and Immunology*. <https://doi.org/10.12932/ap-050819-0616>
- Sun, S., Liu, D., Zhang, H., Zhang, X., & Wan, B. (2019). Effect of different doses and time-courses of corticosteroid treatment in patients with acute respiratory distress syndrome: A meta-analysis. *Experimental and Therapeutic Medicine*, 18(6), 4637-4644.
- Tanaka, T., Ogata, A., & Narazaki, M. (2010). Tocilizumab for the treatment of rheumatoid arthritis. *Expert Review of Clinical Immunology*, 6(6), 843-854.
- Wan, E. S., Qiu, W., Baccarelli, A., Carey, V. J., Bacherman, H., Rennard, S. I., Agustí, A., Anderson, W. H., Lomas, D. A., & DeMeo, D. L. (2012). Systemic steroid exposure is associated with differential methylation in chronic obstructive pulmonary disease. *American Journal of Respiratory and Critical Care Medicine*, 186(12), 1248-1255.
- Wiener-Kronish, J., Albertine, K., & Matthay, M. (1991). Differential responses of the endothelial and epithelial barriers of the lung in sheep to Escherichia coli endotoxin. *The Journal of Clinical Investigation*, 88(3), 864-875.
- Yang, P., Formanek, P., Scaglione, S., & Afshar, M. (2019). Risk factors and outcomes of acute respiratory distress syndrome in critically ill patients with cirrhosis. *Hepatology Research*, 49(3), 335-343.
- Ziamajidi, N., Khaghani, S., Hassanzadeh, G., Vardasbi, S., Ahmadian, S., Nowrouzi, A., Ghaffari, S. M., & Abdirad, A. (2013). Amelioration by chicory seed extract of diabetes-and oleic acid-induced non-alcoholic fatty liver disease (NAFLD)/non-alcoholic steatohepatitis (NASH) via modulation of PPAR α and SREBP-1. *Food and Chemical Toxicology*, 58, 198-209.