

Mucocele On Lower Lip: Case Report

Alt Dudakta Mukosel: Olgu Sunumu

Orhan Kazan¹ , Buse Erdil² , İhsan Levent Aral³ 

ÖZET

Mukoseller genel popülasyonda %0.4-%0.9 insidansı olan iyi huylu lezyonlardır. Mukusla dolu bir kist içerir. Ağız boşluğu, paranazal sinüsler, safra kesesi ve apendiks gibi birçok bölgede yerleşebilirler. Sıklıkla alt dudakta lokalize olurlar. Mukosel her iki cinsiyette de eşit oranda görülür ve her yaşta ortaya çıkabilir. Klinik olarak mukosel; palpasyonda asemptomatik, iyi sınırlı, pembemsi-mavi renkli, fluktuan nodül olarak saptanır. Oral mukosel tedavisinde; cerrahi eksizyon, kriyocerrahi, intralezyonel kortikosteroid, elektrokoter, CO₂ lazer gibi birçok yöntem kullanılmaktadır. Seçilecek tedavi yönteminde lezyonun boyutu ve tekrarlama olasılığı gibi faktörler göz önünde bulundurulmalıdır. Bu olgu sunumunda alt dudakta şişlik şikâyeti ile kliniğimize başvuran hastanın oral mukosel tanısı ve tedavi süreci anlatılacaktır.

Anahtar kelimeler: Alt dudak; Mukosel; Tükürük bezleri

ABSTRACT

Mucoceles are benign lesions with an incidence of 0.4%-0.9% in the general population. It contains a mucus-filled cyst. They may localize in many regions such as the oral cavity, paranasal sinuses, gall bladder, and appendix. Frequently, they localize at the lower lip. Mucocele is seen equally in both gender and it can occur at any age. Clinically, mucoceles are detected as an asymptomatic, well-defined, pinkish-blue colored, fluctuant nodule on palpation. In oral mucocele, the treatment; Many methods such as surgical excision, cryosurgery, intralesional corticosteroid, electrocautery, CO₂ laser are used. Factors such as the size of the lesion and the possibility of recurrence should be considered in the treatment method to be chosen. In this case report, the diagnosis of oral mucocele and the treatment process of the patient who applied to our clinic with the complaint of swelling in the lower lip will be explained.

Keywords: Lower lip; Mucocele; Salivary glands

Makale gönderiliş tarihi: 06.09.2021 ; Yayına kabul tarihi: 20.12.2021

İletişim: Dr. Orhan Kazan

Kırıkkale Oral and Dental Health Center, Turkey

E-posta: kzn.orhan@gmail.com

¹ Doctor, Kırıkkale Oral and Dental Health Center, Kırıkkale-Turkey

² PhD Student, Gazi University Faculty of Dentistry, Department of Oral and Maxillofacial Surgery, Ankara-Turkey

³ Professor Doctor, Gazi University Faculty of Dentistry, Department of Oral and Maxillofacial Surgery, Ankara-Turkey

INTRODUCTION

A mucocele describes a mucus-filled cyst. It may occur in the oral cavity, paranasal sinuses, gall bladder, and appendix.^{1,2} It is the second most common benign soft tissue lesion in the oral cavity after irritation fibroma.³

Etiologic factors are lip biting, trauma, and changes in the salivary glands. Trauma-induced mucoceles are called mucus extravasation cysts, and those that occur as a result of an obstruction in the salivary gland ducts are called mucus retention cysts.⁴ Generally, they arise as a result of a defect in the minor salivary glands.^{1,5} The most frequently localized area is the lower lip. Mucocele is seen equally in both gender and it can also occur at any age.⁴ Clinically, mucocele is detected as an asymptomatic, well-defined, pinkish-blue, fluctuant nodule on palpation. The lesion usually occurs as a result of minor trauma and reaches a certain size. It may stay unchanged for months if left untreated.^{1,4,6}

Many methods can be used in the treatment of oral mucocele such as surgical excision, cryosurgery, intralesional corticosteroid, electrocautery, CO₂ lasers.⁷ Surgical approach is the most common treatment method. There are three different surgical options for the treatment of oral mucoceles; complete excision, marsupialization, and dissection. The location and size of the lesion determine which treatment method should be used. The marsupialization method is preferred in cases where the lesion is close to anatomical structures or in cases where surgical access is limited.^{1,8} This case report aimed to present the mucocele detected in the lower lip and excisional surgical treatment.

CASE REPORT

A 22-year-old male patient applied to Gazi University Faculty of Dentistry Oral and Maxillofacial Surgery Clinic due to swelling in his lower lip. The patient was systematically healthy and he has no complaints other than swelling in the lower lip. He stated that he did not experience any difficulties during speaking and chewing. During clinical examination, a soft, painless, mobile nodule was found on the lower lip (Figure 1). When the history was deepened, it was learned that the patient had a lip-biting habit. Written informed consent was obtained from the patient

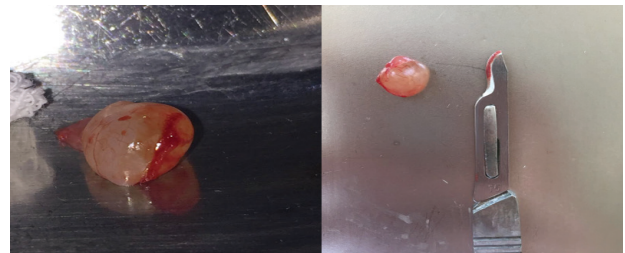
before the surgical procedure. The lesion was surgically excised completely under local anesthesia (Figure 2,3,4,5). For the definitive diagnosis and histopathological evaluation of the lesion, 7 x 8 x 9 mm excised piece of tissue was sent to the Department of Pathology. As a result of histological and immunohistochemical examinations, the lesion was diagnosed with mucocele. The patient was informed and followed up.

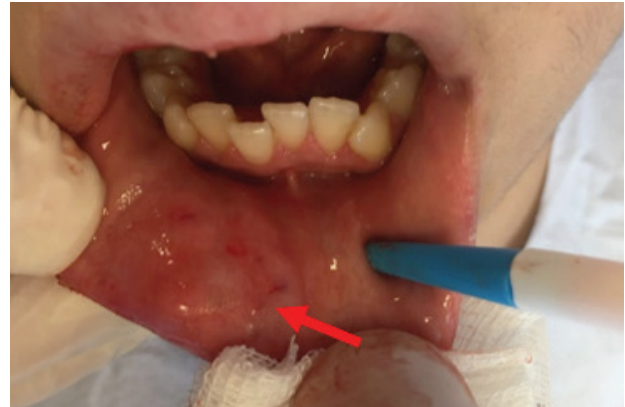
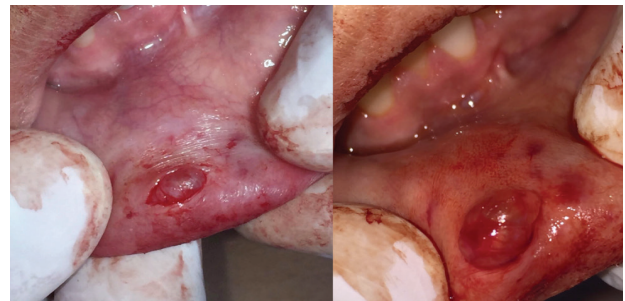
Figure 1. The appearance of the nodular mass detected on the right side of the lower lip mucosa during intraoral examination of the patient.



Figures 2 and 3. Intraoperative photographs of the oral mucocele.



Figures 4 and 5. The appearance of the oral mucocele after surgical excision.

DISCUSSION

Mucoceles are benign lesions with an incidence of 0.4%-0.9% in the general population.⁹ Etiology includes trauma and obstruction in the salivary gland ducts.⁴ Other etiological factors include irritation due

to tooth brushing, sialoliths in the salivary gland, and parafunctional habits such as friction or sucking.¹⁰ In this case presented in the study, it was learned from a patient that he had a lip-biting habit.

Mucoceles can be seen in all ages and genders, however, it was reported that they peaked in the age range of 10-29 years.¹ In the case, we presented 22 years old patient, which corresponds with the literature information.

Mucoceles are often localized in the lower lip (60% to 70%), followed by the floor of the mouth with a rate of 6% to 15 %.¹¹ It may also be seen in the areas which contain minor salivary glands, including the soft palate, retromolar region, and buccal mucosa.^{12,13} Mucocele in the presented case was detected in the lower lip in accordance with the literature.

Mucoceles usually appear to be bluish, soft, transparent cystic lesions. These soft tissue masses are detected as asymptomatic, single or multiple, fluctuant nodules on palpation.^{1,14} In this presented case, the nodule presented with clear borders, mobile and painless on palpation.

Mucoceles are mainly diagnosed clinically, but histopathological examination should also be performed. Lesions that need to be eliminated before clinical diagnose; lymphangioma, hemangioma, lipoma, mucoepidermoid carcinoma, lymphoepithelial cysts.¹ In this presented case, the localization and clinical findings of the lesion supported the diagnosis of mucocele and it was confirmed with the result of the histopathological evaluation.

Mucoceles may rupture spontaneously. Moreover, swelling may recur at certain intervals. Treatment is required in cases where there is no spontaneous recovery¹⁵ In the treatment of mucocele, many techniques such as conventional surgery, electrosurgery, lineoic acid etching, CO₂ laser vaporization can be utilized.^{7,16,17} In this case report, the fibrous capsule and glandular tissue around the lesion were surgically excised and complete treatment was achieved.

CONCLUSION

There are many options for the treatment of oral mucoceles. Considering the possibility of recurrence due to chronic lip-biting habits in the patient in our case report, surgical approach was preferred.

Surgical treatment prevents possible recurrence. In this case report, a medium-sized oral mucocele with clear borders was surgically excised and complete treatment was achieved. The patient has been followed for two years, and no recurrence has been detected.

REFERENCES

1. Baumash HD. Mucoceles and ranulas. *J Oral Maxillofac Surg* 2003;61:369-78.
2. Chaitanya P, Praveen D, Reddy M. Mucocele on lower lip: a case series. *Indian Dermatol Online J* 2017;8:205.
3. Yagüe García J, España Tost AJ, Berini Aytés L and Gay Escoda, C. Treatment of oral mucocele-scalpel versus CO₂ laser. *Med Oral Patol Oral Cir Bucal* 2009;14:469-74.
4. Yamasoba T, Tayama N, Syoji M, Fukuta M. Clinicostatistical study of lower lip mucoceles. *Head & neck* 1990;12:316-20.
5. Baumash H. The etiology of superficial oral mucoceles. *J Oral Maxillofac Surg* 2002;60:237-8.
6. Bonet FB, Homs EV, Tornil AM, Lagunas JD. Mucocele de la glandula submaxilar: a propósito de un caso Submaxillary gland mucocele: presentation of a case. *Med Oral Patol Oral Cir Bucal* 2005;10:180-4.
7. Re Cecconi D, Achilli A, Tarozzi M, Lodi G, Demorasi F, Sardella A, et al. Mucoceles of the oral cavity: a large case series (1994-2008) and a literature review. *Med Oral Patol Oral Cir Bucal* 2010;4:551-556.
8. Baumash HD. A case against sublingual gland removal as primary treatment of ranulas. *J Oral Maxillofac Surg* 2007;65:117-21.
9. Laller S, Saini RS, Malik M, Jain R, Bahadurgarh H. Case report an appraisal of oral mucous extravasation cyst case with mini review. *J Adv Med Dent Scie Res* 2014;2.
10. Eversole LR, Sabes WR. Minor salivary gland duct changes due to obstruction. *Arch Otolaryngol* 1971;94:19-24.
11. Roediger W, Lloyd P, Lawson H. Mucous extravasation theory as a cause of plunging ranulas. *Br J Surg* 1973;60:720-2.
12. Seifert G, Miehke A, Haubrich J. Diseases of the salivary glands: Georg Thieme Verlag Stuttgart 1986.
13. Cataldo E, Mosadomi A. Mucoceles of the oral mucous membrane. *Arch Otolaryngol* 1970;91:360-5.
14. Hayashida AM, Zerbinatti DC, Balducci I, Cabral L, Almeida J. Mucus extravasation and retention phenomena: a 24-year study. *BMC Oral Health* 2010;10:1-4.
15. Zhi K, Wen Y, Ren W, Zhang Y. Management of infant ranula. *Int J Pediatr Otorhinolaryngol* 2008;72:823-6.
16. McCaul J, Lamey P-J. Multiple oral mucoceles treated with gamma-linolenic acid: report of a case. *Br J Oral Maxillofac Surg* 1994;32:392-3.
17. Nuntanaranont T, Thuaksuban N. The use of CO₂ laser for treatment of salivary gland disease in seven cases. *Int Cong Ser* 2003;393-8