

A Comparison of Internal Jugular versus Subclavian Vein Approaches in Totally Implanted Venous Access Ports

Total İmplant Venöz Erişim Portlarında İnternal Juguler ve Subklavian Ven Yaklaşımlarının Karşılaştırılması

Murat DÖKDÖK¹, Kutlay KARAMAN¹, Ayşen YÜCEL²

¹Anadolu Sağlık Merkezi, Radyoloji, Gebze, Kocaeli

²Anadolu Sağlık Merkezi, Algoloji, Gebze, Kocaeli

Öz

Bu çalışmanın amacı, subklavyan ven (SCV) yaklaşımına karşı ultrason rehberliğinde düşük internal juguler ven (IJV) yaklaşımı ile yerleştirilen tamamen implante edilebilir venöz erişim portlarının (TIVAP'ler) sonuçlarını ve komplikasyonlarını geriye dönük olarak gözden geçirmektir. Kateter çıkarılmaya veya çalışma süresinin sonuna kadar izlenebilen 304 kanser hastası çalışmaya alındı. 200 hastaya IJV yoluyla TIVAP ve 104 hastaya SCV yoluyla TIVAP yerleştirildi. İstatistiksel analizler hasta özellikleri ve primer malignite bölgesi açısından iki grupta fark olmadığını gösterdi, TIVAP'lerin büyük çoğunluğu sağ tarafa yerleştirilmişti. Ortalama port kalma süresi SCV grubuna kıyasla IJV grubunda daha yüksekti, bu fark istatistiksel olarak anlamlıydı ($p<0.001$). SCV'de komplikasyonlar IJV yaklaşımına göre daha sıkı (12 hastaya karşı 3 hasta). Çalışmamız, TIVAP'in uzun süreli kemoterapi uygulaması için güvenli ve etkili bir yol olduğunu ve TIVAP'lerin doğru IJV yoluyla yerleştirilmesinin düşük uzun dönem komplikasyon oranı ile ilişkili olduğunu ortaya koydu.

Anahtar Kelimeler: Kanser, Venöz Erişim Portları, Venöz Kateterizasyon

Abstract

The purpose of this study was to retrospectively review the outcome and complications of totally implantable venous-access ports (TIVAPs) inserted via low internal jugular vein (IJV) approach under ultrasound guidance versus subclavian vein (SCV) approach. 304 cancer patients who could be followed up to the time of catheter removal or to the end of the study period were enrolled in the study. 200 patients had the placement of TIVAPs via IJV and 104 patients via SCV. Statistical analysis showed that there were no differences with regard to the patient characteristics and to the site of primary malignancy in two groups, while the large majority of the TIVAPs had been inserted in the right side. The average port dwelling time was higher in the IJV group compared to the SCV group, the difference was statistically significant ($p<0.001$). Complications were more frequent in the SCV than in the IJV approach (12 patients vs. 3 patients). Our analysis revealed that TIVAP is a safe and effective route for long-term administration of chemotherapy, and the placement of TIVAPs via the right IJV is associated with a low long-term complication rate.

Keywords: Cancer, Venous Access Ports, Venous Catheterization

Introduction

Totally implantable venous access ports (TIVAPs) are valuable instruments in the care of cancer patients receiving long-term intravenous treatment including chemotherapy (1-3). Subcutaneous venous ports are preferred to external catheters, particularly in patients who have received intermittent long-term infusion therapies, due to low infection rates and high patient comfort.

However, implantation and the use of these devices are associated with some complications. In addition to the perioperative problems, long-term complications may also occur such as catheter malfunction, venous thrombosis, catheter-related infection, obstruction, disconnection, and extravasation injury (4-7).

Subcutaneous venous ports have been increasingly placed under radiological guidance

since first described by Morris et al in 1992 (8). Use of ultrasonography (US) guidance during internal jugular catheterization has determined a reduction in the rates of unsuccessful cannulation. Over time, internal jugular vein (IJV) approach has been preferred over subclavian vein (SCV) one for a couple of reasons such as straight course of and better US visualization of IJV and, pinch-off syndrome leading catheter fracture in SCV approach (4). The purpose of this study was to retrospectively review the outcome and complications of TIVAPs inserted via low IJV approach under US guidance versus conventional SCV approach in a multidisciplinary interventional oncology service.

Material and Method

Among 376 adult patients who had the placement of TIVAPs from January 2007 to December 2013 in our hospital, 304 patients who could be followed up to the time of catheter removal or the end of the study period were enrolled in the study. 200 patients had the placement of TIVAPs via IJV and 104 patients via SCV. The patients' characteristics including type of malignancy and port dwell time are summarized in Table 1.

Prior to the procedure, platelet counts to 70,000 mL or greater, INR<1.5 were required. Prophylactic antibiotics were administered using

ORCID No
Murat DÖKDÖK 0000-0002-1313-8557
Kutlay KARAMAN 0000-0001-7654-8038
Ayşen YÜCEL 0000-0002-7386-3646

Başvuru Tarihi / Received: 27.10.2021
Kabul Tarihi / Accepted : 10.05.2023

Adres / Correspondence : Murat DÖKDÖK
Anadolu Sağlık Merkezi, Radyoloji, Gebze, Kocaeli

e-posta / e-mail : murat.dokdok@anadolusaglik.org

ceftriaxone 1g., and sedoanalgesia was obtained using midazolam and fentanyl.

Institutional board approval-and routine informed consent forms including permission for anonymously using the material pertaining to the patient are obtained in this study accordingly to the World Medical Association Declaration of Helsinki.

Technique of the procedure

All jugular TIVAPs were placed in the angiography room under US and fluoroscopy guidance by interventional radiologists (M.D or

K.K) and an interventional algologist (A.Y). Initially, the patient was placed in a supine position with the head turned away to the contralateral side, and US examination of the IJVs was performed following skin site preparation in a sterile fashion. Sterile US gel and sterile drapes were used to cover the US probe and cable. Right IJV approach was preferred in all patients unless there was a mass lesion, scar tissue, right mastectomy, or right IJV occlusion. Otherwise left IJV approach was utilized.

Table 1. Patients characteristics and port dwell time

	IJV group	SCV group	p value
Number of patients	200(66%)	104(34%)	
Gender			0.086
Male	87(44%)	56(54%)	
Female	113(66%)	48(46%)	
Age (years)			0.056
Mean \pm SD	51.8 \pm 13.09	52.64 \pm 12.04	
Range (min-max)	18 - 78	20 - 79	
Cancer location			0.963
Breast / Gynecological	34(17%)	18(17%)	
GIS	113(56.5%)	58(56%)	
Respiratory tract	24(12%)	11(11%)	
Others	29(14.5%)	17(16%)	
Port dwell time (months)			<0.001
Mean \pm SD	30.32 \pm 20.57	21.54 \pm 20.16	
Median (range)	34 (1-68)	28(1-67)	

IJV: internal jugular vein, SCV: subclavian vein, ratios in (%)

The targeted skin area, 1–2cm above the clavicle, was infiltrated with local anesthetic. In all patients, the venous puncture was performed with a 21G needle and a 0.018-inch wire (Micro access set, Angiodynamics®, NY, USA) under US guidance, and a micropuncture sheath was placed. A 0.035-inch J tip guidewire was advanced into superior vena cava through the micropuncture sheath. After the withdrawal of it, a peel-away sheath was placed over the wire holding the tip of the guidewire at the level of the atrio-caval junction or high atrium. After removing dilatator and guidewire, port catheter was inserted through the peel-away sheath. The 2 cm length horizontal incision was made 2-3 cm caudal to the middle of the clavicle and a subcutaneous pocket was formed by blunt dissection under local anesthesia. The free tip of the catheter was drawn from the venous access site into the subcutaneous pocket using a blunt metallic tunneling tool and attached to the port hub. The port was not fixed to the underlying fascia, but the skin was sutured using the absorbable sutures. Using the Huber needle, the port was checked; the final position of the catheter was confirmed by fluoroscopy (Figure 1). At the last step, the system was flushed with 10 ml 1000U heparinized saline.

All SCV TIVAPs were placed in the angiography room by interventional algologist (A.Y), using fluoroscopic guidance. The subclavian vein was punctured in the mid or lateral third of the clavicle to avoid pinch-off. In all patients, venous entry was

performed with an 18 G Seldinger needle and the tip of the guide-wire was advanced into the vena cava. US guidance and micro access sets are not utilized in subclavian procedures. After the puncture, the subcutaneous pocket was dissected. The pocket site was the same for the IJV and SCV access; the rest of the procedure was similar.

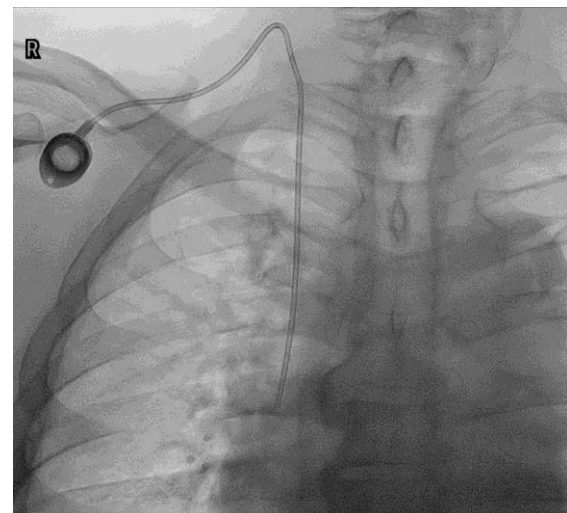


Figure 1. Chest fluoroscopy showing port catheter placed via internal jugular vein approach

Most of the TIVAPs used (258 in 84.9%) consisted of a titanium port with a silicone membrane connected to a silicone catheter (Braun

Celcite®). We have used Vortex mini (Smart Port® CT Power-Injectable Port) in 46 patients and Bard® port system in 21 patients.

After the procedure, all patients were kept under observation for 2-4 hours and checked for hematoma and other immediate complications every 30 minutes. Chemotherapy was commenced on the day 0-3 post procedure. The catheter care and dressing change were performed by a pain nurse or nurses in the outpatient chemotherapy unit or hospital ward. The port catheter was flushed with 10 ml 1000U heparinized saline after each use or monthly even if it was not used.

Statistical Analysis

Medical records including laboratory data related to infection were reviewed for the presence of complications of infusion port and documented. All data were obtained from our files and the electronic database of the hospital information system. Normality analysis applied on the variables using IBM SPSS 21.0v statistics revealed abnormal distribution with Kolmogorov Smirnov test ($p=0.002$) coefficient of variation and Q-Q plot graphics.

To summarize the basic features, descriptive statistics concerning the central tendency (mean, median) and variability (minimum, maximum and,

standard deviation) were used. After the statistical level was defined as 0.05, statistical significance of the patient age, patient gender, cancer locations were calculated using Chi-square test and Mann-Whitney U test was used to examine if differences existed between the port dwell time of IJV and SCV groups.

Results

The two groups (IJV vs. SCV) were comparable as to patient characteristics and to the site of primary malignancy (Table 1). A chi-square test of independence showed that there was no relationship between the variables in two groups. The two groups (IJV vs. SCV) were comparable as to general patient characteristics; also, there were no differences with regard to patients age, gender and the site of primary malignancy ($p=0.056$, 0.086 and 0.963 respectively). In both groups, the majority of the TIVAPs was inserted on the right side (165 patients / 82.5% in the IJV group vs. 35 patients / 33.6% in the SCV group). We have used the cephalic vein approach in 14 patients who have access problems such as radiation fibrosis, and scar tissue in both areas. The results of this group are not included, as the number of patients is not enough to make any comparison (Figure 2).

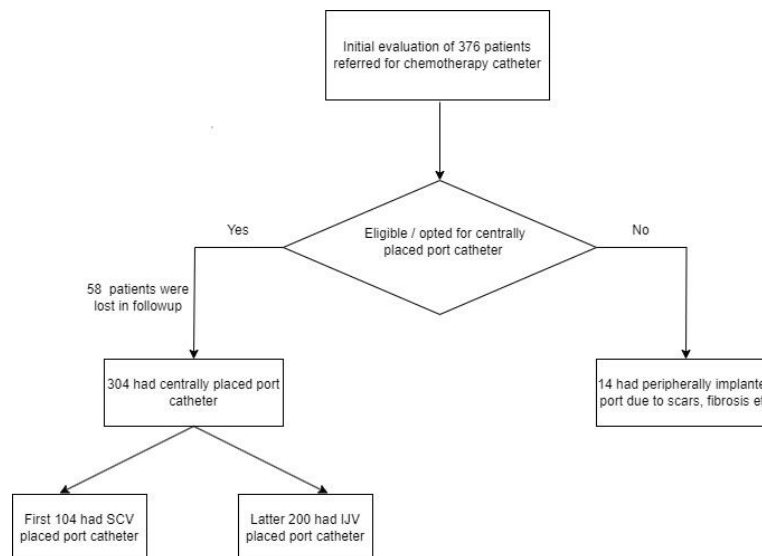


Figure 2. Flow-chart of patient selection

The port dwelling time was higher in the IJV group compared to the SCV group. Mann-Whitney U test yielded score of 4.197 and p-value of <0.001 which is statistically significant. In both groups the patients had longer median port dwelling time than mean with moderately left sided skewed distribution of patients in both groups (IJV= 0.142 vs SCV= 0.0664).

Complications were more frequent in the SCV than in the IJV approach (respectively, 12 patients/11.53% vs. 3 patients/1.5%). Catheter malposition occurred in 2 patients (1.92%, right

side) when using the SCV and in 1 patient (0.5%, right side) for the IJV (Figure 3). 3 patients had pneumothorax in the SCV group (2.88%, two right sides, one left side) but only 1 required chest tube drainage. 1 patient (0.96%) had arterial puncture (left side), and 1 patient (0.96%) had infection (left side) in SCV group. We have not seen any pneumothorax and arterial puncture in the IJV group. 2 patients (1%, one right side, one left side) had an infection in the IJV group. We had to remove TIVAPs in 4 patients (3.84%, one right, three left side) because of the thrombosis in the SCV group.

We have not seen any thrombosis in the IJV group (Table 2). The total number of complications were too low to make any statistical comparison.

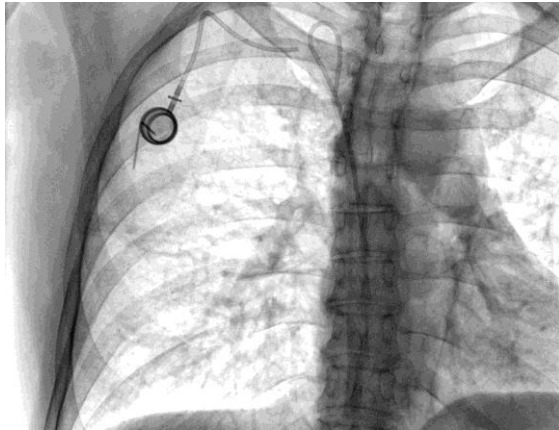


Figure 3. Chest fluoroscopy showing malpositioned and fractured port catheter placed via subclavian vein approach

Discussion

In this retrospective study, we reviewed and analyzed our single institutional experience with TIVAPs via low jugular vein approaches under US guidance versus subclavian vein approaches. TIVAPs are of utmost importance in the care of oncology patients as they have a longer life and lower infection rates compared to other types of

vascular access catheters. The procedure is typically performed in an operating room in many institutes; however, image-guided minimally invasive techniques have gained popularity over the last decade.

The use of US guidance has been shown to increase the safety and efficacy in numerous studies including meta-analysis for internal jugular catheterization, which leads to a reduction in arterial puncture, and hematoma formation when compared with the blind landmark technique (9-11). Likewise, with US-guided subclavian insertion of TIVAPs, statistically, lower failure was found compared to with landmark access to the IJV and with surgical access of cephalic vein (12). However, in a meta-analysis of SCV catheterization no statistically significant difference was found between the use of US and the conventional landmark technique with regard to the total complication rate, the overall success rate, the number of attempts until success, the time to successful cannulation, and the success rate with the first attempt (13). We believe that this is probably due to the massive experience of the authors with blind puncture technique and relatively short lifespan of simple central venous catheters. It is generally considered that image-guided puncture and catheter placement decrease the early procedure-related complications such as hemorrhagic vascular complications, pneumothorax, and catheter malpositioning (14).

Table 2. TIVAP complications

TIVAP complications	IJV group	SCV group
Early complications	Number of patients	Number of patients
Pneumothorax	-	3
Late complications	Number of patients	Number of patients
Infection	1	1
Thrombosis	-	4
Dislocation	1	2
Decubitus	1	2
Total	3	12

TIVAP: totally implantable venous-access ports, IJV: internal jugular vein, SCV: subclavian vein

IJV puncture may be high or low depending on the patient's anatomy and operator's choice. In our institution, we prefer very low puncture to avoid from steep angulation of the port catheter (20) The near perpendicular puncture should be guided by the real-time US imaging of the needle. However, high jugular puncture might be feasible in selected cases (21). On the other hand, a very low puncture may cause the risk of extravasation when multiple lumen catheters are used (22). We also tend to puncture through the thinner cross-sectional segment of sternocleidomastoid muscle while coursing anteriorly in the distal part. Although not analyzed in our study, it may be related to reduced pain perception and better catheter position and function (17).

As inserted in the supine position, the catheter can be retracted when the patient stands up,

especially, the port catheters inserted from the left side and the catheters in obese female patients. (14, 23) Displacement of the catheter tip position up is more prominent in the jugular vein approach. In our cases, we tended to trim catheter three to four centimeters longer which is defined by the patient's body status and approach site without a predetermined length. High catheter tip position in the upper half of the superior vena cava may increase the risk of thrombosis, migration, and malfunction of the catheter (24). Ignatov et al. have stated that catheter tip location and vein access are independent predicting factors not only for thrombosis but also for TIVAPs-complications in general (3). TIVAPs placed on the right side of the chest are associated with fewer complications and longer durability than the left-sided. The left brachiocephalic vein and superior vena cava form a steep angle, which

predisposes endothelium to injuries while pushing the catheter during the left-sided approach. Besides, the chronic microtrauma caused by catheters and administered chemotherapeutic agents may lead to further injury of the endothelium that causes thrombosis and infection.

The risk of venous stenosis and thrombosis for long-term catheters were found to be higher in SCV accesses compared to IJV accesses (15,25). The thrombotic complications might be as high as 4.3% in cancer patients, even in central venous catheters (CVC) (26). The use of Alteplase (tissue plasminogen activator) might be effective to deal with thrombosis related complications in TIVAPs (27). We had to remove TIVAPs in 4 patients (3.84%) because of the thrombosis in SCV group, whereas no thrombosis detected in the IJV group.

In the present study, risk factors for thrombosis were more than one insertion attempt (OR=5.5; 95% CI 1.2-24.6), ovarian cancer (OR=3.8; 95% CI 1.4-10.4), and previous CVC insertion (OR=4.8; 95% CI 1.5-15.1). In patients with solid tumors, the incidence of catheter-related thrombosis was 4.6% (8/171) in patients with chest ports and 29.8% (25/84) in arm ports respectively. We preferred the cephalic vein approach in patients who have a problem in both jugular and subclavian areas such as radiation fibrosis, scar tissue. The findings at our institution are consistent with those of previous studies, with lower complication rates. Overall, complications were more frequent in the SCV than in the IJV approach (respectively, 12 patients/11.53% vs. 3 patients/1.5%). The number of complications, however, was low to make any statistical comparison.

The frequency of infection in patients with TIVAPs varies from 2.6% to 9.3% in the literature (4, 6, 18), and the 5-year cumulative probability to be free of infectious complication is only 62.8% (28). The incidence of infections is typically lower in patients with TIVAPs when compared to short term catheters (6,29). No infection was observed in both study groups.

As a serious complication that has clinical and economical consequences, pneumothorax is more common in the SCV approach (30). In cases of a pinch-off, the risk of pneumothorax is reported to be around 0.1% to 3.2%, due to collapsed SCV (19). Although Chang et al. have suggested cephalic vein cut-down to avoid pneumothorax (31), it can be readily avoided by image-guided IJV puncture. In a study by Araújo et al., the IJV approach compared favorably to SV for the insertion of TIVAP (32). Our clinical experience supports their results as we did not encounter any pneumothorax in the IJV group.

Since the average procedure times were not measured, they are not comparable in terms of duration. As the subcutaneous route tend to be longer in the IJV approach, the time of procedure may also be longer. However, we feel that shorter

puncture time in the IJV approach with the help of US guidance equalizes both procedures.

We observed that most of the TIVAPs specific complications were common in the first 2 years of procedures. Along with evolving multidisciplinary interventional oncology teams, nursing staff gained experience through years; while the rate of complications decreased substantially. Most TIVAPs complications could be attributed to inexperienced handling of ports and be avoided with well-trained staff and with properly educated patients.

We had limitations in the study. First of all, this retrospective study was a single-center study based on relatively small numbers. Second, the technique might have been purified in later stages, as most SCV TIVAPs were included in the early stages of the study. Third, teamwork in IJV TIVAPs could have reflected better optimal outcomes compared to single-disciplinary approaches. TIVAPs as a safe and effective route for long-term administration of chemotherapy, are a requirement in patients with cancer. Our analysis revealed that the placement of TIVAPs via the right internal jugular vein in a multidisciplinary approach is associated with a low long-term complication rate. Because of the increasing popularity of TIVAPs, best policy could be developed in a high-volume center for the benefit of the patients. Likewise, all healthcare personnel should be familiar with their use and routine maintenance procedures.

Ethics Committee Approval: Ethics committee approval was obtained from ASM Hospital Ethics Committee (ASM-EK-21/160) for the study.

References

1. Bow EJ, Kilpatrick MG, Clinch JJ. Totally implantable venous access ports systems for patients receiving chemotherapy for solid tissue malignancies: a randomized controlled clinical trial examining the safety, efficacy, costs, and impact on quality of life. *J Clin Oncol.* 1999;17:1267.
2. Minassian VA, Sood AK, Lowe P, et al. Longterm central venous access in gynecologic cancer patients. *J Am Coll Surg.* 2000;191:403-9.
3. Ignatov A, Hoffman O, Smith B, et al. An 11-year retrospective study of totally implanted central venous access ports: Complications and patient satisfaction. *Eur J Surg Oncol.* 2009;35:241-6.
4. Cil BE, Canyığıt M, Peynircioğlu B, et al. Subcutaneous venous port implantation in adult patients: a single center experience. *Diagn Interv Radiol.* 2006;12:93-8.
5. Lebeaux D, Fernández-Hidalgo N, Chauhan A, et al. Management of infections related to totally implantable venous-access ports: challenges and perspectives. *Lancet Infect Dis.* 2014;14:146-59.
6. Beckers MM, Ruven HJ, Seldenrijk CA, et al. Risk of thrombosis and infections of central venous catheters and totally implanted access ports in patients treated for cancer. *Thromb Res.* 2010;125:318-21.
7. Biffi R, Pozzi S, Agazzi A, et al. Use of totally implantable central venous access ports for high-dose chemotherapy and peripheral blood stem cell transplantation: results of a monocentre series of 376 patients. *Ann Oncol.* 2004;15:296-300.

8. Morris SL, Jacques PF, Mauro MA. Radiology assisted placement of implantable subcutaneous infusion ports for longterm venous access. *Radiology*.1992;184:149-51
9. Randolph AG, Cook DJ, Gonzales CA, et al. Ultrasound guidance for placement of central venous catheters: a meta-analysis of the literature. *Crit Care Med*. 1996;24:2053-8.
10. Saugel B, Scheeren TWL, Teboul JL. Ultrasound-guided central venous catheter placement: a structured review and recommendations for clinical practice. *Crit Care*. 2017;21:225.
11. Brass P, Hellmich M, Kolodziej L, et al. Ultrasound guidance versus anatomical landmarks for internal jugular vein catheterization. *Cochrane Database Syst Rev*. 2015;1(1):CD006962.
12. Biffi R, Orsi F, Pozzi S, et al. Best choice of central venous insertion site for the prevention of catheter-related complications in adult patients who need cancer therapy: a randomized trial. *Ann Oncol*. 2009;20(5):935-40.
13. Brass P, Hellmich M, Kolodziej L, et al. Ultrasound guidance versus anatomical landmarks for subclavian or femoral vein catheterization. *Cochrane Database Syst Rev*. 2015;1(1):CD011447.
14. Biffi R, Corrado F, Braud F, et al. Longterm, totally implantable central venous access ports connected to a groshong catheter for chemotherapy of solid tumours: experience from 178 cases using a single type of device. *Eur J Cancer*. 1997;33:1190-4.
15. Macdonald S, Watt AJ, McNally D, et al. Comparison of technical success and outcome of tunneled catheters inserted via the jugular and subclavian approaches. *J Vasc Interv Radiol*. 2000;11:225-31.
16. Yip D and Funaki B: Subcutaneous chest ports via the internal jugular vein. A retrospective study of 117 oncology patients. *Acta Radiol*. 2002;43:371-5.
17. Plumhans C, Mahnken AH, Ocklenburg C, et al: Jugular versus subclavian totally implantable access ports: catheter position, complications and intrainterventional pain perception. *Eur J Radiol*. 2011;79:338-42.
18. Cimochoowski CE, Worley E, Rytherford WE, et al. Superiority of internal jugular over subclavian access for temporary dialysis. *Nephron*. 1990;54:154-61.
19. Lorch H, Zwaan M, Kagel C, et al. Central venous access ports placed by interventional radiologists: experience with 125 consecutive patients. *Cardiovasc Intervent Radiol*. 2001;24:180-4.
20. Silberzweig J, Mitty HA. Central venous access: Low internal jugular vein approach using imaging guidance *American Journal of Roentgenology*. 1998;170(6):1617-20.
21. Park HS, Kim YI, Lee SH, et al. Central venous infusion port inserted via high versus low jugular venous approaches: Retrospective comparison of outcome and complications. *Eur J Radiol*. 2009;72(3): 494-8.
22. McGrath BA. Low internal jugular puncture sites when using ultrasound guidance. *British Journal of Anaesthesia*. 2008;(101).
23. Kowalski CM, Kaufman JA, Rivitz SM, et al. Migration of central venous catheters: Implications for initial catheter tip positioning. *J Vasc Interv Radiol*. 1997;8:443-7.
24. Puel V, Cuadry M, LeMetayer P, et al. Superior vena cava thrombosis related to catheter malposition in cancer chemotherapy given through implanted ports. *Cancer*. 1993;72:2248-52.
25. Schillinger F, Schillinger D, Montagrac R, et al. Central venous stenosis in hemodialysis: comparative angiographic study of subclavian and internal jugular access. *Nephrologie*. 1994;15:129-31.
26. Lee AY, Levine MN, Butler G, et al. Incidence, risk factors, and outcomes of catheter-related thrombosis in adult patients with cancer. *J Clin Oncol*. 2006;24:1404-9.
27. Semba CP, Weck S, Razavi MK, et al. Characterization of alteplase (tPA) following delivery through the AngioJet rheolytic catheter. *J Endovasc Ther*. 2005;12:123-8.
28. Crisinel M, Mahy S, Ortega-Debalon P, et al. Incidence, prevalence and risk factors for a first infectious complication on a totally implantable venous-access port. *Med Mal Infect*. 2009;39:252-8.
29. Estes JM, Rocconi R, Straughn M, et al. Complications of indwelling venous access devices in patients with gynecologic malignancies. *Gynecol. Oncol*. 2003;91:591-5.
30. Machat S, Eisenhuber E, Pfarl G, et al. Complications of central venous port systems: a pictorial review. *Insights Imaging*. 2019;10(1):86.
31. Chang HM, Hsieh CB, Hsieh HF, et al. An alternative technique for totally implantable central venous access devices. A retrospective study of 1311 cases. *Eur J Surg Oncol*. 2006;32:90-3.
32. Araújo C1, Silva JP, Antunes P, et al. A comparative study between two central veins for the introduction of totally implantable venous access devices in 1201 cancer patients. *Eur J Surg Oncol*. 2008;34:222-6.