

Case Report

J Exp Clin Med  
2022; 39(2): 569-570  
doi: 10.52142/omujecm.39.2.53

## A rare cause of post-ESD pain: Submucosal hematoma at the lesion margin

Azar ABİYEY\*<sup>1</sup>, Serkan DUMANLI<sup>1</sup>, Mustafa ERGİN<sup>1</sup>, Mehmet İBİŞ<sup>1</sup>

Department of Gastroenterology, Faculty of Medicine, Gazi University, Ankara, Turkey

Received: 25.11.2021

Accepted/Published Online: 25.01.2021

Final Version: 18.03.2022

### Abstract

Submucosal hematoma at the margin of the excised lesion after endoscopic submucosal dissection is extremely rare. These patients may experience persistent epigastric pain after the procedure. In this case, report we will discuss about a rare condition.

**Keywords:** endoscopic submucosal dissection, gastrointestinal bleeding, submucosal hematoma, post-ESD pain

### 1. Introduction

Endoscopic submucosal dissection (ESD) is an established effective treatment modality for premalignant and early-stage malignant lesions of the esophagus, stomach and colon (1). ESD is curatively advantageous over endoscopic mucosal resection (EMR) as it allows en bloc resection regardless of tumor size, shape, ulceration or location, which contributes to the reduction in local recurrence rate (2). It is known that bleeding or intramural hematoma may develop after ESD procedure in gastric polyps and subepithelial lesions (3). However, submucosal hematoma is very rare at the margin of the submucosal resected lesion. Here, we present a case of submucosal hematoma at the lesion border in a patient with persistent pain after ESD to a gastric lesion.

### 2. Case report

A 55 years old female patient, who had a previous history of ESD due to gastric polyp, admitted to our clinic for recurrent lesion. The patient had no chronic disease. In laboratory tests, platelet count, bleeding time and coagulation parameters were normal. ESD was planned for the patient. During the procedure, a recurrent hyperplastic lesion of approximately 4 cm in size was observed in the prepyloric antrum at the site of the previously performed ESD. After submucosal saline injection, circumferential incision was made. However, sufficient elevation could not be achieved, and the lesion was removed using hybrid EMR technique with snare (Fig. 1). After hemostasis control was achieved, the procedure was terminated. The patient developed mild epigastric pain after the procedure, did not have hemoglobin (Hb) decrease, melena/hematemesis and vital disturbances. Control endoscopy was performed 1 day later and a submucosal hematoma of 5 cm in size was observed at the border of the excised lesion (Fig. 2). Oral intake of the patient was stopped, pantoprazole 40 mg BID 0.9% NACL infusion, ciprofloxacin

400 mg bid, metronidazole 500 mg TID and tramadol TID were started. Control endoscopy was performed on the 5th day of the patient whose pain regressed in the follow-ups. It was observed that the epithelial integrity of the mucosa covering the hematoma was impaired, the hematoma was resorbed, and an ulcer with a dirty floor was formed in this area (Fig. 3).

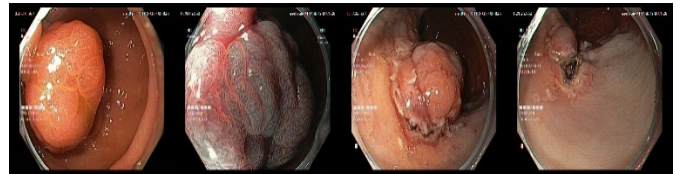


Fig. 1. Hyperplastic lesion and ESD procedure

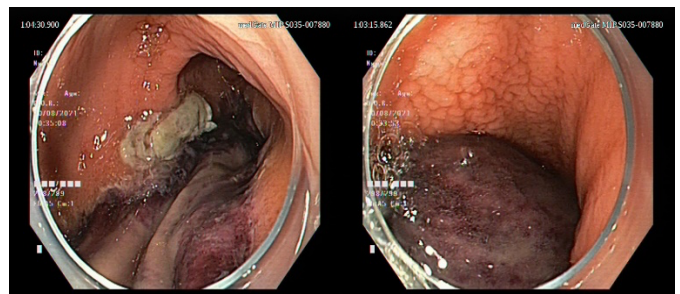


Fig. 2. Submucosal hematoma at the lesion margin

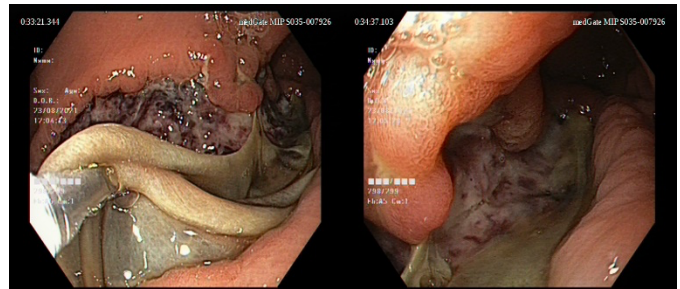


Fig. 3. Resolution of submucosal hematoma

\*Correspondence: drazerabiyevev@gmail.com

### 3. Discussion

The incidence of bleeding after gastric ESD has been reported to range from 1.8% to 15.6% (3). Post-ESD bleeding is defined as melena, hematemesis, and > 2g/dl Hb decrease, requiring endoscopic hemostasis (4, 5). Here, we discussed about a submucosal hematoma at the lesion border after ESD to a gastric lesion. In this case, we followed our patient with conservative treatment and observed that the hematoma regressed in a short time. we did not find any published similar case in the literature. We think that a second look is important in patients who do not have bleeding findings after ESD and who have persistent epigastric pain.

### Conflict of interest

None to declare.

### Acknowledgments

None to declare.

### References

1. Park YM, Cho E, Kang HY, Kim JM. The effectiveness and safety of endoscopic submucosal dissection compared with endoscopic mucosal resection for early gastric cancer: a systematic review and metaanalysis. *Surg Endosc.* 2011;25:2666–2677.
2. Lian J, Chen S, Zhang Y, Qiu F. A meta-analysis of endoscopic submucosal dissection and EMR for early gastric cancer. *Gastrointest Endosc.* 2012;76:763–770.
3. Kataoka Y, Tsuji Y, Sakaguchi Y, Minatsuki C, Asada-Hirayama I, Niimi K, et al. Bleeding after endoscopic submucosal dissection: Risk factors and preventive methods. *World J Gastroenterol.* 2016;22(26):5927-5935.
4. Takizawa K, Oda I, Gotoda T, Yokoi C, Matsuda T, Saito Y, et al. Routine coagulation of visible vessels may prevent delayed bleeding after endoscopic submucosal dissection--an analysis of risk factors. *Endoscopy.* 2008;40:179–183.
5. Ichiro O, Takuji G, Hisanao H, Takeo E, Yutaka S, Takahisa M, et al. Endoscopic submucosal dissection for early gastric cancer: technical feasibility, operation time and complications from a large consecutive series. *Digest Endosc.* 2005;17:54–58.