

## A Rare Case; Focal Acral Hyperkeratosis

### *Nadir Bir Olgu; Fokal Akral Hiperkeratoz*

Nese GOCER GUROK<sup>1</sup>, Savas OZTURK<sup>1</sup>, Ahmet KILICARSLAN<sup>2</sup>

<sup>1</sup> Fethi Sekin City Hospital, Department of Dermatology, Elazig, Turkey

<sup>2</sup> Fethi Sekin City Hospital, Department of Pathology, Elazig, Turkey

#### Özet

Fokal akral hiperkeratoz (FAH) nadir görülen bir genodermatozdur. FAH genellikle yaşamın ikinci veya üçüncü dekatlarında ortaya çıkan; avuç içi ve ayak tabanlarının anormal kalınlaşması ile karakterize, heterojen bir hastalık grubu olan palmoplantar keratodermanın bir türüdür (1). Otozomal dominant kalıtımla birlikte sporadik de olabilir. Costa'nın Akrokeratoelastoidozisi'nin (AKE) nadir bir varyantı olarak da bilinir (2). Etiyolojisi tam olarak bilinmez ve etkin bir tedavi seçeneği yoktur. Burada oldukça nadir görülmesi ve AKE ile sık karıştırılması nedeniyle yeni tanı almış 43 yaşındaki FAH olgusu güncel literatür bilgileriyle sunulmuştur.

**Anahtar kelimeler:** Fokal akral hiperkeratoz, Keratoderma, Otozomal dominant kalıtım, Palmoplantar

#### Abstract

Focal acral hyperkeratosis (FAH) is a rare genodermatosis. FAH is usually observed in the second or third decades of life, and it is a type of palmoplantar keratoderma, a heterogeneous group of diseases characterized by abnormal incrustation of the palms and soles. Although it is an autosomal dominant inheritance, it could also be sporadic. It is also known as a rare variant of Costa's Acrokeratoelastoidosis (AKE). Its etiology is not known clearly and there is no effective treatment. In the present study, a 43-year-old recently diagnosed FAH case is presented due to its rarity and frequent confusion with AKE based on current literature.

**Keywords:** Autosomal dominant inheritance, Focal acral hyperkeratosis, Keratoderma, Palmoplantar

**Yazışma Adresi:** Nese GÖÇER GÜROK, Fethi Sekin Şehir Hastanesi, 23119, Elazığ, Türkiye

**Telefon:** 05304431214 **e-mail:** dr.n\_g@hotmail.com

**ORCID No (Sırasıyla):** 0000-0001-7069-0447, 0000-0001-7973-6712, 0000-0001-8193-8778

**Geliş tarihi:** 05.04.2021

**Kabul tarihi:** 08.03.2022

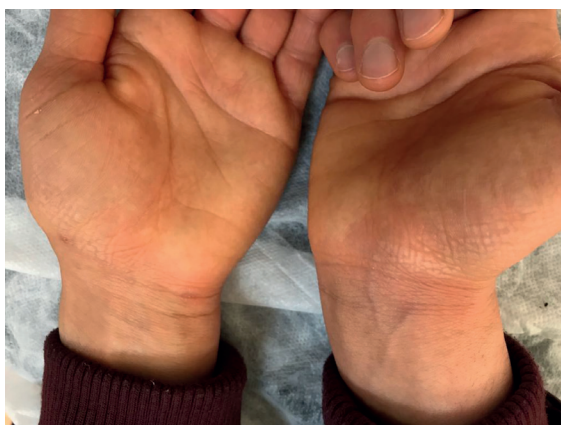**DOI:** 10.17517/ksutfd.1063964

## INTRODUCTION

Focal acral hyperkeratosis (FAH) is a genodermatosis of unknown etiology, which was first described in 1983 and characterized by asymptomatic papules and plaques, mostly due to autosomal dominant inheritance (1-2). It progresses with small, hard, shiny, yellowish-white, flat, sometimes navel hyperkeratotic papules, especially on the thenar and hypothenar sections of the palms and soles (3). Lesions usually occur in the second or third decade of life (4). Its etiology is not fully known. In differential diagnosis, it is clinically and histopathologically differentiated based on AKE, verruca vulgaris, degenerative collagen plaques and keratoelastoidosis marginalis on the hands, punctate palmoplantar keratoderma, digital papular calcinosis, acral mucinosis, and acrokeratosis verruciformis (1,5). FAH is characterized by smooth-surfaced papules, while verruca vulgaris is characterized by a verrucous surface. FAH exhibit clinical features similar to AKE. Histopathologically, orthokeratosis, clavus-like depression of the epidermis, hypergranulosis and mild acanthosis are observed in both. However, FAH differs from AKE by the absence of elastorexia in histopathology. Collagen, elastic fibers and fibroblasts are normal in FAH (4,6). Although the lesions are usually asymptomatic, it was also shown to be associated with hyperhidrosis (7). Although the disease prognosis is benign, it leads to psychological and cosmetic concerns. In the present study, a case of focal acral hyperkeratosis, a rare dermatosis, is presented.

## CASE REPORT

A 43-year-old female patient presented with white asymptomatic papules on her hands that became evident due to long-term water contact. In dermatological examination, hard, bright yellowish-white, keratotic, merging

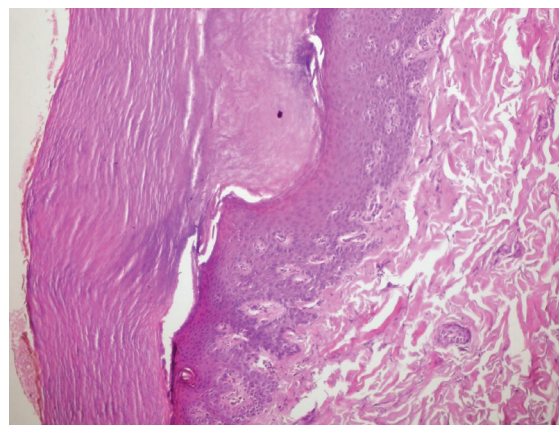


**Picture 1.** In dermatological examination, hard, bright yellowish-white, keratotic, merging papules were observed on the hypothenar, thenar, inner surfaces of the bilateral hands

ing papules were observed on the hypothenar, thenar, inner surfaces of the bilateral hands (**Picture 1**). There was no history of hyperhidrosis, excessive sun exposure, or trauma. There was no one in her family with similar complaints. Biopsy was conducted. Histopathology was insignificant except for hyperkeratosis and epidermal depression. Collagen and elastic fibers were normal, and there was no elastorexia. Based on the clinical and histopathological findings, the patient was diagnosed with FAH (**Picture 2**). Topical retinoid and urea treatment alleviated the complaints of the patient. Required consent was obtained from the patient for the case report.

## DISCUSSION

Dowd *et al.* (6) described focal acral hyperkeratosis (FAH) as a rare condition characterized by numerous yellowish to white papules and plaques on the palms and soles, located at the palmar and plantar limits. Irregular distribution between the dorsal, palmar or plantar skin, the area between the thumb and forefinger, and the palmodorsal junction line on the thenar eminence are the most common forms. Frequently, the papules coalesce to form plaques (7). In differential diagnosis, AKE, verruca vulgaris, degenerative collagen plaques of the hands, keratoelastoidosis marginalis of the hands, punctate palmoplantar keratoderma, digital papular calcinosis, acral mucinosis, acrokeratosis verruciformis should be kept in mind. Although all these diseases exhibit similar clinical presentations, it is possible to differentiate them histopathologically. Histopathologically, orthokeratosis, clavus-like depression of the epidermis, hypergranulosis and mild acanthosis are observed. Elastorexia is not present, and collagen, elastic fibers and fibroblasts are normal. Although the pathogenesis is still unclear, increased expression of proliferation markers such as Ki-67 and PCNA was



**Picture 2.** Based on the clinical and histopathological findings, the patient was diagnosed with FAH

recently reported by Lee and Kim in a FAH patient, suggesting that the epidermal variations were due to increased proliferation and differentiation of keratinocytes in the lesion in FAH (8). Although topical retinoids, topical keratolytics, cryotherapy, and prednisone have been tried in treatment, most were unsuccessful. In focal acral hyperkeratosis, 25 to 50 mg etretinate was used for 6 months; however, relapses were observed when the treatment was discontinued or the dose was reduced (9). Although the disease is asymptomatic and has a benign course, it should be kept in mind that FAH may be present in patients who present to outpatient clinics with palmoplantar keratoderma and are resistant to classical treatments, since the disease may lead to psychological and cosmetic concerns. In conclusion, we presented this case to emphasize that FAH should not be considered in the differential diagnosis of palmoplantar keratotic papules, since it is a rare form of dermatosis, and to emphasize its distinction from AKE. Although the pathogenesis of FAH is not fully understood, future reported cases and molecular studies would contribute to the elucidation of the pathogenesis of the disease.

**Conflict of Interest and Financial Status:** The authors declare that they have no competing interest.

**Author Contribution Rate Statement Summary:** The authors declare that, they have contributed equally to the manuscript.

**Informed consent:** Informed consent form was taken from the participant.

9. Handfield-Jones S, Kennedy CT. Acrokeratoelastoidosis treated with etretinate. *JAm Acad Dermatol.* 1987;17:881-882.

## REFERENCES

1. Kelsell DP, Leigh IM. Inherited keratodermas of palms and soles. In: Wolff K, Goldsmith LA, Katz SI, Gilchrest BA, Paller AS, Leffell DJ, Editors. *Fitzpatrick's dermatology in general medicine.* 7th ed. New York: McGraw-Hill; 2008:424-431.
2. Erkek E, Kocak M, Bozdogan O, Atasoy P, Birol A. Focal acral hyperkeratosis: A rare cutaneous disorder within the spectrum of Costa acrokeratoelastoidosis. *Pediatr Dermatol.* 2004;21:128-130.
3. Rongioletti F, Betti R, Crosti C, Rebora A. Marginal papular acrokeratodermas: A unified nosography for focal acral hyperkeratosis, acrokeratoelastoidosis and related disorders. *Dermatology.* 1994;188:28-31.
4. Lee EA, Kim HS, Kim HO, Park YM. A Case of Focal Acral Hyperkeratosis. *Ann Dermatol.* 2009;21:426-428.
5. Sardana K, Chugh S, Garg VK. Focal Acral Hyperkeratosis. *Indian Pediatr.* 2013;50:256.
6. Dowd PM, Harman RR, Black MM. Focal acral hyperkeratosis. *Br J Dermatol.* 1983;109:97-103.
7. Natow S. Focal Acral Hyperkeratosis. *Dermatol Online J* 2001;7(1).
8. Lee SE, Kim SC. Focal acral hyperkeratosis. *Clin Exp Dermatol.* 2007;32:608-610.