

# A Fatal Case of Culture-Negative Late Prosthetic Mitral Valve Endocarditis

Uğur Küçük<sup>1</sup>, Sevil Alkan<sup>2</sup>, Ahmet Barutçu<sup>1</sup>

<sup>1</sup>Department of Cardiology, Faculty of Medicine, Canakkale Onsekiz Mart University, Canakkale, Turkey.

<sup>2</sup>Department of Infectious Diseases and Clinical Microbiology, Canakkale Onsekiz Mart University, Canakkale, Turkey.

## Abstract

Prosthesis valve dehiscence is one of the most serious complications of prosthetic valves. Despite the improvements in medical and surgical treatments, prosthesis valve dehiscence has high mortality. Due to fatality rates, the early diagnosis and treatment of these patients is required. In this case report, we presented a patient with severe mitral deficiency and acute heart failure following mechanical mitral prosthesis valve dehiscence secondary to culture-negative endocarditis.

**Keywords:** Culture-negative endocarditis, prosthetic valve endocarditis, dehiscence

## Introduction

Prosthetic valve endocarditis (PVE) is an uncommon and dangerous consequence of valve replacement that is linked with a high rate of significant morbidity and fatality, as compared to native valve endocarditis (NVE). There are two major problems: determining the diagnosis and curing PVE. PVE diagnosis is difficult, and it frequently necessitates the use of many imaging techniques in addition to routine microbiological tests<sup>1</sup>.

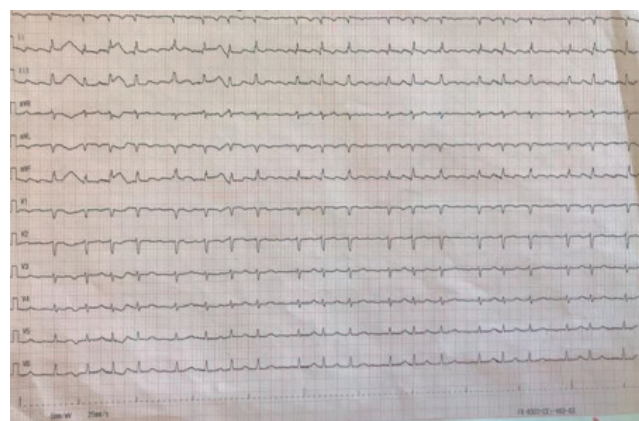
Prosthetic valve endocarditis is responsible for 10-30% of infective endocarditis (IE) and is estimated to occur with an annual incidence of 0.3-1.2% and is infrequently compounded by prosthetic valve (PV) dehiscence<sup>2,3</sup>. Additionally, culture-negative endocarditis is thought to account for 2-30% of all IE cases<sup>4</sup>.

Here, we describe a patient with severe mitral deficiency and acute heart failure following mechanical mitral prosthesis valve dehiscence secondary to culture-negative endocarditis.

## Case Report

A 50-year-old female immunocompetent patient admitted to the emergency department with complaints of palpitation, fever and weakness for one month.

Initial vital signs on admission day were heart rate was 120 beats/min (Figure-1), respiratory rate was 26 breaths/



**Figure 1.**

min, oxygen saturation at 85% on room air. Although the patient stated that she had a fever, she did not have a fever on admission day. In her cardiac auscultation, a metallic heart sound and systolic murmur were heard at the cardiac apex. Physical examination revealed no other signs of other endocarditis stigmas (Splinter hemorrhage, Osler nodule, Janeway lesions, etc.). The laboratory examinations at the admission revealed a white blood cell count (WBC): 10700/mm<sup>3</sup> (54.6% neutrophils), a hemoglobin: 12.1 g/dL, and a platelet count: 136,000/mm<sup>3</sup>. The inflammatory markers showed a erythrocyte sedimentation rate: 68 mm/h, C-reactive protein: 2.55 mg/dL. Liver function tests, renal function tests and other biochemical test results showed no abnormality. The serum coagulation were in normal

**Corresponding Author:** Uğur Küçük

**e-mail:** drugurkucuk@hotmail.com

**Received:** 26.02.2022 • **Revision:** 19.04.2022 • **Accepted:** 25.04.2022

**DOI:** 10.33706/jemcr.1079578

©Copyright 2020 by Emergency Physicians Association of Turkey - Available online at www.jemcr.com

**Cite this article as:** Kucuk U, Alkan S, Barutcu A. A fatal case of culture-negative late prosthetic mitral valve endocarditis. Journal of Emergency Medicine Case Reports. 2022;13(3): 79-81

ranges, respectively. Posterior-anterior (PA) chest X-ray and urinalysis were normal. Atrial flutter was observed in the patient on admission electrocardiogram. She was hospitalized for further examination and treatment. In the detailed history of the patient, she had a history of mechanical prosthetic valve implantation 25 years ago due to rheumatic mitral valve stenosis. She had no other known comorbidities and chronic drug use. She applied to a medical center and antiarrhythmic therapy was prescribed, and an appointment was made for a control examination. About 10 days later, she was referred to our hospital when there was no improvement in her symptoms.

Firstly, transthoracic echocardiography (TTE) was performed to rule out IE; this examination revealed no suspicious mass-like lesion at the prosthetic mitral valve. But the image of dehiscence was observed in the prosthetic mitral valve. Then advanced imaging methods were planned. Transesophageal echocardiography (TEE) shows severe mitral regurgitation (Figure-2). Three-dimensional echocardiography shows dehiscence of the prosthetic valve (Figure-3). Consultation with an infectious disease's specialist was requested to investigate other etiological causes of the patient's high fever and manage antibiotic treatment, and these recommendations were followed. Three sets blood cultures and serological tests were requested. The treatment was started according to recommendations of 'The Diagnosis, Treatment and Prevention of Infective Endocarditis: Turkish Consensus Report'<sup>5</sup>. Empirically

intravenous (i.v) vancomycin IV (30-60 mg/kg, 3 doses/day), gentamicin (3 mg/kg, single dose/day), cefepime (6 gr, 3 doses/day) and orally rifampicin (900 mg, 3 doses/day) treatments were started. No pathological findings were detected in abdominal ultrasonography.

The results of all blood culture results, and the antibody titers to *Coxiella burnetii*, *Chlamydia spp.*, *Mycoplasma spp.* or *Legionella*, *Brucella* tube agglutination test were negative. *Tropheryma whipplei* and *Bartonella henselae* were found to be negative in blood polymerase chain reactions. Galactomannan antigen test in serum was negative for *Aspergillus spp.*

Emergency cardiac surgery was planned due to the mobile vegetation and severe mitral valve regurgitation.

Cardiovascular surgery consultation was made for emergency surgery. However, in the 5<sup>th</sup> day of the follow-up cardiogenic shock developed in the patient. The patient was intubated due to the decrease in O<sub>2</sub> saturation. The patient was started on inotropic therapy, but despite all interventions, the patient died.

## Discussion

Prosthetic valve endocarditis (PVE) is defined as endovascular infection that affects sections of a prosthetic valve or the heart's repaired native valve. It's the most serious kind of IEs, as higher fatality/complication rates and difficulties in the management<sup>6</sup>. The presented case died of sudden onset of heart failure due to mechanical mitral prosthesis valve dehiscence secondary to culture-negative endocarditis.

This illness is divided into two categories based on the time it takes to develop the condition: early PVE and late PVE. The early type of PVE develops within a year following surgery, while the late type of PVE develops beyond a year. The distinction in microbiological profiles between the former and the latter is of clinical consequence<sup>6</sup>. The presented case had a history of mechanical prosthetic valve implantation 25 years ago.

Late PVE is caused by infection acquired in the community, and the pathogens are identical to those seen in native valve endocarditis. Gram positive microorganisms (*Streptococci* and *Staphylococcus aureus*, followed by coagulase-negative *staphylococci* and *enterococci*) are the most common pathogens. The patients with various comorbidities who are hospitalized to hospitals for other reasons and develop endocarditis have a significant mortality rate in late PVE<sup>6,7</sup>. In our report, the microbiological and serological test results were negative.

Vegetation may not always be seen on prosthetic valve imaging, as in our case. An important part of the etiology of dehiscence valve are endocarditis, degeneration and calcification in the valve suture regions. Both small vegetation and prosthetics with artifacts are the most important reasons for this. Duke criteria used for the diagnosis of native valve endocarditis have low sensitivity for the diagnosis of prosthetic

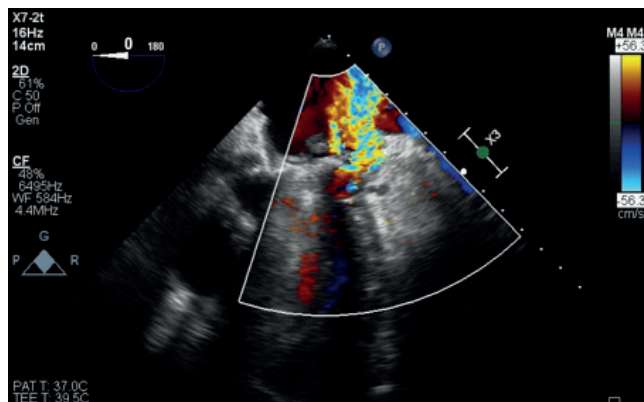


Figure 2.

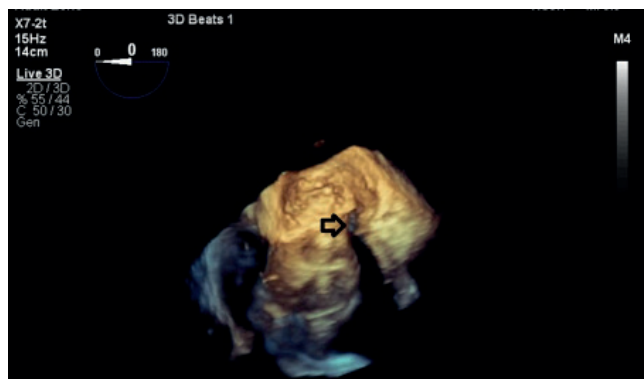

Figure 3.

valve endocarditis. The infection is usually localized at the junction of the prosthetic valve and tissue in the suture ring. It causes severe paravalvular leakage secondary to destruction of tissue<sup>3,8</sup>. If TEE fails to diagnose PVE, cardiac computed tomography angiography (CTA) can be used as a further diagnostic method. As cardiac CT is better than TEE at detecting perivalvular abscess, CTA can be utilized as advanced method in diagnosis for patients who have a negative TTE or could not perform TEE due to contraindications<sup>9,10</sup>. Although TTE and TEE are useful in imaging, three-dimensional echocardiographic imaging should be used in cases with suspected prosthetic valve endocarditis, too<sup>11</sup>. We performed three-dimensional echocardiographic imaging.

Late prosthetic valve dehiscence is rare and mortality rates are high. Good long-term results can be achieved with early diagnosis and timely surgical treatment<sup>2,3,6,8</sup>. The presented did not operated as case sudden cardiogenic shock developed and she died.

## Conclusion

As a result, the complications of PVE must be diagnosed early and treated surgically as soon as possible. In this case, three-dimensional TEE is helpful in determining the cause of the severity of PVE. Even if no other symptoms of IE (fever, positive blood cultures, or vegetations) are present, acute valve insufficiency (particularly an eccentric jet) and heart failure should raise suspicion of culture negative endocarditis.

## References

1. Ivanovic B, Trifunovic D, Matic S, Petrovic J, Sacic D, Tadic M. Prosthetic valve endocarditis - A trouble or a challenge? *J Cardiol*. 2019;73(2):126-33. doi: 10.1016/j.jcc.2018.08.007.

2. Habib G, Thuny F, Avierinos JF. Prosthetic valve endocarditis: current approach and therapeutic options. *Prog Cardiovasc Dis*. 2008;50(4):274-81.
3. Klimis H, Altman M, Chard R, Skinner M, Thomas L. Dehiscence of a Mechanical Aortic Valve Secondary to Culture-Negative Endocarditis Complicated by Acute Heart Failure. *CASE (Phila)*. 2019;3(5):215-9. doi: 10.1016/j.case.2019.04.008.
4. Young JS, Farber BF, Pupovac SS, Graver LM. Prosthetic Valve Legionella Endocarditis. *Ann Thorac Surg*. 2019;108(4):e271-e272.
5. Şimşek-Yavuz S, Akar AR, Aydoğdu S, Berzeg-Deniz D, Demir H, Hazirolan T et al. [Diagnosis, treatment and prevention of infective endocarditis: Turkish consensus report]. *Klimik Derg*. 2019; 32(Suppl. 1): 2-116.
6. Khalil H, Soufi S. Prosthetic Valve Endocarditis. 2022 Jan 19. In: StatPearls [Internet]. Treasure Island (FL): StatPearls Publishing; 2022 Jan-. PMID: 33620808.
7. Rivas P, Alonso J, Moya J, de Górgolas M, Martinell J, Fernández Guerrero ML. The impact of hospital-acquired infections on the microbial etiology and prognosis of late-onset prosthetic valve endocarditis. *Chest*. 2005;128(2):764-71.
8. Vardas, Panos E. Prosthetic aortic valve endocarditis complicated with annular abscess, sub-aortic obstruction and valve dehiscence. *Hellenic J Cardiol*, 2009; 50: 319-23.
9. lung B, Rouzet F, Brochet E, Duval X. Cardiac Imaging of Infective Endocarditis, Echo and Beyond. *Curr Infect Dis Rep*. 2017;19(2):8.
10. Koneru S, Huang SS, Oldan J, Betancor J, Popovic ZB, Rodriguez LL, Shrestha NK, Gordon S, Pettersson G, Bolen MA. Role of preoperative cardiac CT in the evaluation of infective endocarditis: comparison with transesophageal echocardiography and surgical findings. *Cardiovasc Diagn Ther*. 2018 Aug;8(4):439-49.
11. Galzerano D, Kinsara AJ, Di Michele S, Vriz O, Fadel BM, Musci RL, Galderisi M, Al Sergani H, Colonna P. Three dimensional transesophageal echocardiography: a missing link in infective endocarditis imaging? *Int J Cardiovasc Imaging*. 2020 Mar;36(3):403-13.