



Choledochoduodenostomy for failed endoscopic treatment of common bile duct stones: Both traditional and current method

Ana safra kanalı taşlarının başarısız endoskopik tedavisi için koledokoduodenostomi: Hem geleneksel hem de güncel olan bir yöntem

Mehmet Can Aydın¹, Oğuzhan Özşay¹, Kağan Karabulut²

Abstract

Background: The gold standard current treatment for common bile duct (CBD) stones is stone extraction via endoscopic retrograde cholangiopancreatography (ERCP). In ERCP failed cases, alternative surgical treatment methods come to the fore. Choledochoduodenostomy (CDD), which is a traditional method, is one of them. We aimed to present our conventional CDD results in ERCP failed patients.

Methods: Between March 2015 and February 2022, clinicodemographics, perioperative findings, and postoperative results of 23 ERCP failed patients with underwent CDD for CBD stones were analyzed retrospectively.

Results: The median age was 71 (41-85), and 13 (56%) were female. Of the patients, 5 (21%) had cholecystectomy and 7 (30%) had gastrectomy + gastroenterostomy, previously. The most common presenting symptom was abdominal pain (39%). The median number of failed ERCPs was 1 (1-6), and the reasons for failure were gastroenterostomy in seven patients, impacted stones in nine, multiple and/or large stones in six, and papillary opening anomaly in one. The median CBD diameter was 15 (10-40) mm. The median operation time was 120 (60-240) minutes, and no perioperative complication developed. The median length of hospital stay was seven (4-14) days. In the early postoperative period, wound infection was observed in two (8%) patients, and evisceration was observed in one (4%). There was no mortality. The mean follow-up period was 27 (2-77) months, and incisional hernia was encountered in 2 (8%) patients in the late postoperative period. There was no evidence of Sump syndrome within the follow-up period.

Conclusion: In treatment of ERCP failed CBD stones, CDD is an effective and safe surgical treatment method in selected patients.

Keywords: choledochus, common bile duct exploration, obstructive jaundice.

Öz

Amaç: Koledok taşlarının altın standart güncel tedavi yöntemi endoskopik retrograd kolanjiopankreatografi (ERCP) ile taş çıkarılmasıdır. Bunun başarısız olduğu durumlarda alternatif cerrahi tedavi yöntemleri ön plana çıkmaktadır. Geleneksel bir yöntem olan koledokoduodenostomi (CDD) de bunlardan biridir. Biz de ERCP'nin başarısız olduğu hastalardaki konvansiyonel CDD sonuçlarımızı sunmayı amaçladık.

Yöntemler: Mart 2015 ve Şubat 2022 tarihleri arasında ERCP ile tedavi edilemeyen koledok taşı olan ve konvansiyonel koledok eksplorasyonu, taş çıkarılması ve CDD uygulanan 23 hastanın klinikodemografik verileri, perioperatif bulguları ve postoperatif sonuçları retrospektif olarak analiz edildi.

Bulgular: Hastaların ortalama yaşı 71 (41-85) olup, 13'ü (%56) kadındı. Hastaların 5'inde (21%) geçirilmiş kolesistektomi, 7'sinde (30%) gastrektomi + gastroenterostomi ameliyatı öyküsü vardı. En sık başvuru semptomu karın ağrısıydı (39 %). Başarısız ERCP sayısı ortalama bir (1-6) olup, başarısızlık nedenleri yedi hastada gastroenterostomi olması, dokuz hastada impakte taş olması, altı hastada taş boyutu ve sayısının fazla olması, bir hastada papilla açılım anomalisiydi. Hastaların ortalama koledok çapı 15 (10-40) mm'di. Operasyon süresi ortalama 120 (60-240) dk olup, perioperatif komplikasyon gelişmedi. Yatış süresi ortalama yedi (4-14) gündü. Postoperatif erken dönemde iki (8%) hastada yara yeri enfeksiyonu, bir (4%) hastada eviserasyon görüldü. Mortalite izlenmedi. Hastaların ortalama takip süresi ortalama 27 (2-77) aydı ve geç dönemde iki (8%) hastada insizyonel herni ile karşılaşıldı. Sump sendromuna ait bulgular hiçbir hastamızda gözlenmedi.

Sonuç: ERCP ile çıkarılamayan koledok taşlarının tedavisinde CDD seçilmiş hastalarda efektif ve güvenli bir cerrahi tedavi yöntemidir.

Anahtar Kelimeler: ana hepatik kanal eksplorasyonu, koledok, obstrüktif sarılık.

¹ Department of Gastrointestinal Surgery, Ondokuz Mayıs University School of Medicine, Samsun, Turkey
² Department of General Surgery, Ondokuz Mayıs University School of Medicine, Samsun, Turkey



MCA: 0000-0002-2379-1293

OÖ: 0000-0001-6291-2652

KK: 0000-0003-4723-5360

Ethics Committee Approval: The present study was approved by Local Ethical Committee of Ondokuz Mayıs University School of Medicine (2022/186).

Etik Kurul Onayı: Bu çalışma 19 Mayıs Üniversitesi Tıp Fakültesi Etik Kurulu tarafından onaylanmıştır (2022/186).

Conflict of Interest: No conflict of interest was declared by the author.

Çıkar Çatışması: Yazar çıkar çatışması bildirmemiştir.

Financial Disclosure: The author declared that this case has received no financial support.

Finansal Destek: Yazar bu çalışma için finansal destek almadığını beyan etmiştir.

Geliş Tarihi / Received: 11.04.2022

Kabul Tarihi / Accepted: 16.07.2022

Yayın Tarihi / Published: 01.08.2022

Sorumlu yazar / Corresponding author:
Mehmet Can Aydın

Adres/Address: Ondokuz Mayıs University School of Medicine, 55270, Samsun, Turkey

E-mail: dr.mca@hotmail.com

Tel/Phone: +90 5446727216

Copyright © ACEM

Introduction

Common bile duct (CBD) stones are mostly secondary to the falling of gallbladder stones into the bile duct, and their frequency is increasing, especially in elderly patients [1,2]. This may cause complications with high morbidity such as jaundice, cholangitis and pancreatitis, and requires treatment. Currently, the standard treatment for CBD stones is the laparoscopic cholecystectomy following extracting the stones via endoscopic retrograde cholangiopancreatography (ERCP) [3,4]. However, in ERCP failed cases, other treatment methods should be performed [5]. Choledochoduodenostomy (CDD) is one of these, and despite increasing surgical experience, it has been maintaining its safety area for many years.

CCD was first performed by Riedel in 1888 [6]. Over time, with the increasing experience in endoscopic and laparoscopic treatments, this method has rarely been used. These rare conditions include previous gastroenterostomy, impacted stones, large and/or multiple stones, peripapillary diverticulum, or papillary opening anomaly, which causes ERCP failure [1]. In addition, Sump syndrome, an extremely rare complication that causes fear of surgeons, has further reduced the use of CDD [7]. In this study, we aimed to present the results of our patients underwent CDD, after failed ERCPs for CBD stones.

Material and methods

The present study was approved by the local ethics committee of Ondokuz Mayıs University (2022/186). Between March 2015 and February 2022, 23 patients with CBD stones who underwent CDD due to failed ERCPs were included in the study. The patients who had T-tube drainage, primary suture or hepaticojejunostomi were excluded. And patients with malignancy and with benign biliary stenosis were excluded. The indications were failure of ERCP, due to CBD stones, for all these patients. The diameter of the CBD was over 10 mm in all (Figure 1). The data of the patients including age, gender, body mass index, American Society of Anesthesiologists Score, previous cholecystectomy and upper abdominal surgery, main presenting symptom, number of failed ERCPs, CBD size (imaging with Magnetic Resonance Cholangiography), percutaneous treatment, operation time, count and diameter of extracted stones operatively, technical details of the anastomosis, early and late postoperative complications, and findings in the follow-up period, were examined.

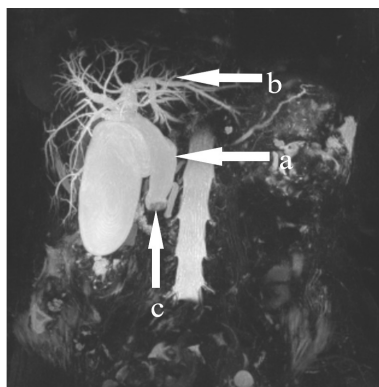


Figure 1. Magnetic resonance cholangiography imaging of a patient before choledochoduodenostomy. (a) Common bile duct diameter is larger than 10 mm, (b) intrahepatic bile ducts are markedly dilated, and (c) impacted stone in the distal part of common bile duct.

The operations were performed by 3 hepatopancreaticobiliary surgeons. Informed consent was obtained from all patients. After the right subcostal or Makuuchi incision, duodenal mobilization was fully achieved by performing the Kocher maneuver for a tension free anastomosis. Cholecystectomy was performed if previously not, routinely. After suspending sutures in the distal common bile duct, a longitudinal 2 cm choledochotomy and duodenotomy were performed from the most distal part of the CBD (supraduodenal region). CBD stones were extracted and, bile duct was irrigated with saline. Proximal and distal parts of the CBD were checked via stone forceps or cholangiography, for stone clearance. The passage was checked from the choledochus to the duodenum via a bougie. PDS or Prolen monofilament sutures (4.0-5.0) were used continuously or interrupted for the single-layer anastomosis (Figure 2). An abdominal drain was placed under the CDD, routinely.

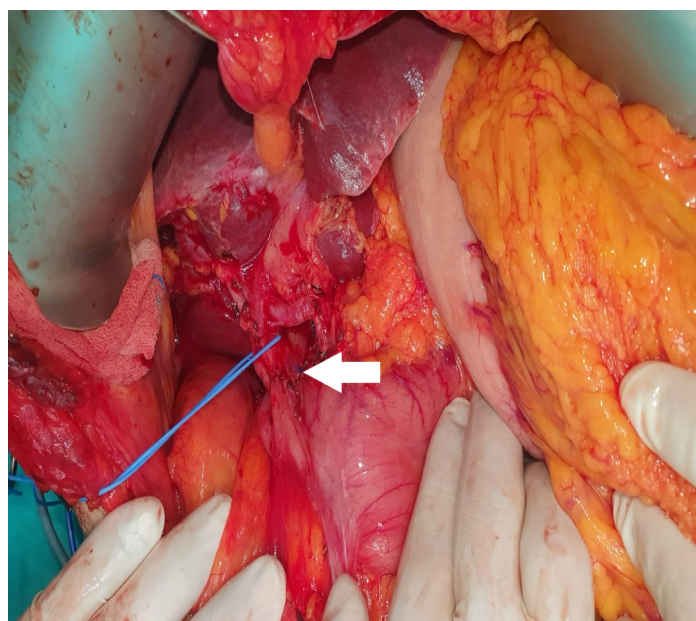


Figure 2. The image of tension free anastomosis of choledochoduodenostomy (marked with the arrow).

Antibiotic prophylaxis was used as 3rd generation of Cephalosporin before the operation. The nasogastric drain was removed and the oral diet was started on the postoperative 3rd day. The drain was removed when the amount was below 100 cc/day, and then patients were discharged. While the postoperative first 30 days were defined as the early period, the following days were long-term. Long-term outcomes were recorded through clinical reports at outpatient follow-up and hospital readmissions. Sump syndrome is defined as recurrent cholangitis and liver abscess due to stones, sludge, or debris accumulating in the CBD reservoir. Ultrasonography and magnetic resonance cholangiography were performed to evaluate stone recurrence.

All statistical analyses were performed with IBM SPSS Statistics 26 (IBM, Armonk, NY, USA). The normality of the distribution of continuous variables was tested by Shapiro–Wilk test. Normally distributed continuous variables were expressed as mean \pm standard deviation. Non-normally distributed continuous variables were expressed as median and range. Categorical data was described as frequencies with percentages.

Results

Clinicodemographic characteristics and previous medical histories of the patients are shown in Table 1.

Table 1. Preoperative findings of the patients

Age, median (range)	71 (41-85)
Gender, female, n (%)	13 (56.5%)
BMI <25 kg/m ² , n (%)	12 (52.5%)
ASA score 3, n (%)	11 (47.8%)
Previous upper abdominal surgery	
Laparoscopic cholecystectomy	5 (21.7%)
Conventional gastrectomy	7 (30.4%)
Laparoscopic hiatal hernia repair	1 (4.3%)
Main presenting symptom, n (%)	
Abdominal pain	9 (39%)
Nausea and vomiting	5 (21.7%)
Jaundice	6 (26%)
Cholangitis (fever with jaundice)	3 (13%)
CBD diameter, mm, median (range)	15 (10-40)
Failed ERCP, median (range)	1 (1-6)
Failed percutaneous treatment, n (%)	7 (30.4%)

BMI: Body mass index, ASA: American Society of Anesthesiologists, CBD: Common bile duct, ERCP: Endoscopic retrograde cholangiopancreatography.

The median number of failed ERCPs was 1 (1-6). The reasons for failure were impacted stones in nine patients, failure due to previous gastroenterostomy in seven, inability to clear the stones because of large size and/or multiple stones in six, and papillary opening anomaly in one. The main reason for trying ERCP in previous gastroenterostomy group was that the type of gastric surgery (Billroth 1 or 2) that had been performed a long time ago at another center was not clearly known. After failed ERCPs, treatment via percutaneous transhepatic catheter was tried in seven patients. In five of these, the stones could not be removed or pushed into the duodenum because of their large size (Figure 3), one could not be adequately positioned due to scoliosis, and in one, intrahepatic bile ducts were not dilated enough and the procedure was failed.

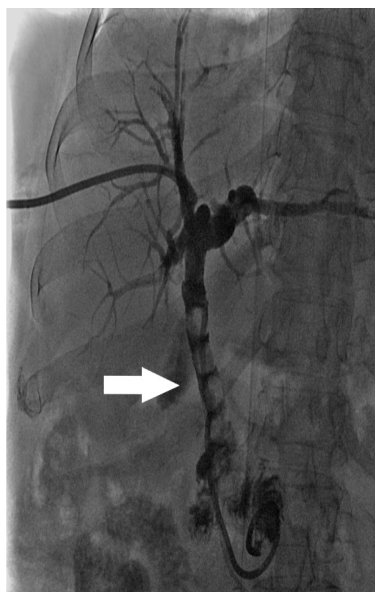

Figure 3. Failed percutaneous treatment due to large stones (marked with the arrow) in the common bile duct.

The perioperative findings and postoperative results of the patients are shown in Table 2.

Table 2. Perioperative findings and postoperative outcomes of the patients.

Operation time (min), median (range)	120 (60-240)
Anastomosis technique	
Continuous, n (%)	14 (60.9%)
Interrupted, n (%)	9 (39%)
Extracted stones, n (%)	
Multiple / Single	18 (78.3%) / 5 (22.7%)
Milimetric / Centimetric	9 (36.1%) / 14 (63.9%)
Length of hospital stay (day), median (range)	7 (4-14)
Postoperative complications, n (%)	
Early period, n (%)	3 (13%)
Wound infection	2
Evisceration	1
Long term period, n (%)	2 (8.6%)
Incisional hernia	2
Follow-up (months), median (range)	27 (2-77)

In the early postoperative period, complications developed in three patients (13%): two had wound infections and were treated conservatively; one was re-operated due to evisceration. No bile leakage or cholangitis was observed. The median follow-up period was 27 (2-77) months. Incisional hernia developed in two (8.6%) patients in the long-term follow-up. Sump syndrome and stone recurrence were not detected in any of them.

Discussion

CBD stones are often associated with cholelithiasis, and they are secondary to these stones falling into the CBD [1]. Rarely, they can also be seen as primary stones due to infection or stasis [8]. CBD stones are generally seen more in the elderly age and female gender, similar to our cohort, and occur in a broad clinical perspective ranging from asymptomatic to pancreatitis and recurrent cholangitis [9]. Therefore, accurate diagnosis and effective treatment are critical in these patients. The current treatment strategy is accepted as ERCP + laparoscopic cholecystectomy [3, 4]. However, in ERCP failed cases, surgical treatment alternatives may be required. These alternatives are choledochotomy + primary suture or T-tube drainage, choledochoduodenostomy and hepaticojejunostomy with stone extraction. We treated some of our ERCP failed patients with CBD stones, performing CDD which is one of these surgical methods, and we did not experience any major complications in the early and late postoperative periods.

In addition to being minimally invasive and highly successful in treatment of CBD stones, ERCP may sometimes fail for various factors. These factors include impacted stones, large and/or multiple stones that do not allow stone clearance, cannulation difficulty due to duodenal diverticulum or papillary opening anomaly, and gastroenterostomy history [10, 11]. Repeated ERCP attempts due to the failure may cause negative results such as re-administration of general anesthesia and an increased risk of complications. In our study group, there were 10 patients who had more than one repeated ERCPs. Considering all these risks and reviewing our results, we think it would be more

appropriate to treat this patient group surgically instead of repeated ERCPs.

While the postoperative morbidity of CDD is approximately 10-28% [12], the most feared complication is Sump syndrome. Sump syndrome is defined as recurrent cholangitis and liver abscess after CDD due to stones, sludge, or debris accumulating in the CBD reservoir distal to the anastomosis [13]. However, this rate is about 2,5% in the literature, which is quite rare [7, 11, 12]. Perhaps this exaggerated fear drives surgeons away from the idea of performing CCD. Recommendations of previous studies to prevent the development of Sump syndrome are that the anastomosis diameter should not be narrow, the papilla should be dilated, and the transition to the duodenum should be confirmed [9, 14]. We attribute that we have never encountered this complication in our long-term follow-up due to following all the recommendations. As a result, we think that this almost abandoned method can be a good alternative surgical technique when performed in selected patients and with the correct principles.

Technical details affecting the long-term success of CCD are based on a few points in the literature. These are performing the choledochotomy from the most distal part possible, mobilizing the duodenum by performing the Kocher maneuver for tension-free anastomosis, choledochotomy, and duodenotomy line being at least 2 cm long [15]. Additionally, side-to-side anastomosis is more preferred because it is more practical and less morbid than end-to-side anastomosis [3]. All anastomosis in our cohort was: at least 3 cm long; as near as duodenum possible and side-to-side.

Studies have shown that CDD can be performed minimally invasively with technological development and increasing laparoscopic surgical experience [9, 16]. The benefits of minimally invasive surgery are undoubted, but the current technique requires appropriate operating room personnel, surgical instruments, and advanced laparoscopy experience. Unfortunately, not all centers can provide these facilities. We also think that laparoscopic CCD can be a more beneficial method for patients in centers where appropriate conditions are provided.

The limitations of our study were the small number of patients and its retrospective nature.

In conclusion, CDD is a safe and effective treatment for ERCP failed CBD stones in selected patients. The surgeons should keep ideal technical recommendations in mind for better postoperative results.

References

1. Asad S, Haj Z, Qureshi Z, Gul B, Ahmed S, Khattak IU. Role Of Choledochoduodenostomy Revisited In The Era Of Minimal Invasive Procedures. *J Ayub Med Coll Abbottabad*. 2019;31:86-9.
2. Hungness ES, Soper NJ. Management of common bile duct stones. *J Gastrointest Surg*. 2006;10:612-9.
3. Bektas H, Duzkoylu Y, Cakar E, Buyukasik K, Colak S. Giant choledochal calculosis: surgical treatment. *N Am J Med Sci*. 2014;6:536-9.
4. Berthou JC, Drouard F, Charbonneau P, Moussalier K. Evaluation of laparoscopic management of common bile duct stones in 220 patients. *Surg Endosc*. 1998;12:16-22.
5. Aydın MC, Karahan SR, Kose E. Comparison between laparoscopic and conventional technique in the surgical treatment of choledocholithiasis. *Laparosc Endosc Surg Sci*. 2020;27:122-9.
6. Riedel H. Über den zungenfoermigen fortatz des rechten leberlappens und seine pathognostische bedeutung für die, erkrankungen der gallenblase nrbst bemerkungen gallensteinoperationen. *Berl Klin Wschr*. 1888;25:577-602.
7. de Aretxabala X, Bahamondes JC. Choledochoduodenostomy for common bile duct stones. *World J Surg*. 1998;22:1171-4.
8. Konstantakis C, Triantos C, Theopistos V, Theocharis G, Maroulis I, Diamantopoulou G, et al. Recurrence of choledocholithiasis

following endoscopic bile duct clearance: Long term results and factors associated with recurrent bile duct stones. *World J Gastrointest Endosc*. 2017;9:26-33.

9. Senthilnathan P, Sharma D, Sabnis SC, Srivatsan Gurumurthy S, Senthil Anand E, Nalankilli VP, et al. Laparoscopic choledochoduodenostomy as a reliable rescue procedure for complicated bile duct stones. *Surg Endosc*. 2018;32:1828-33.
10. Demirel BT, Kekilli M, Onal IK, Parlak E, Disibeyaz S, Kacar S, et al. ERCP experience in patients with choledochoduodenostomy: diagnostic findings and therapeutic management. *Surg Endosc*. 2011;25:1043-7.
11. Okamoto H, Miura K, Itakura J, Fujii H. Current assessment of choledochoduodenostomy: 130 consecutive series. *Ann R Coll Surg Engl*. 2017;99:545-9.
12. Leppard WM, Shary TM, Adams DB, Morgan KA. Choledochoduodenostomy: is it really so bad? *J Gastrointest Surg*. 2011;15:754-7.
13. Srivengadesh G, Kate V, Ananthkrishnan N. Evaluation of long-term results of choledochoduodenostomy for benign biliary obstruction. *Trop Gastroenterol*. 2003;24:205-7.
14. Qadan M, Clarke S, Morrow E, Triadafilopoulos G, Visser B. Sump syndrome as a complication of choledochoduodenostomy. *Dig Dis Sci*. 2012;57:2011-5.
15. Chander J, Mangla V, Vindal A, Lal P, Ramteke VK. Laparoscopic choledochoduodenostomy for biliary stone disease: a single-center 10-year experience. *J Laparoendosc Adv Surg Tech A*. 2012;22:81-4.
16. Khajanchee YS, Cassera MA, Hammill CW, Swanström LL, Hansen PD. Outcomes following laparoscopic choledochoduodenostomy in the management of benign biliary obstruction. *J Gastrointest Surg*. 2012;16:801-5.