



ORJİNAL MAKALE / ORIGINAL ARTICLE

Balıkesir Sağlık Bilimleri Dergisi / BAUN Sağ Bil Derg
Balıkesir Health Sciences Journal / BAUN Health Sci J
ISSN: 2146-9601- e ISSN: 2147-2238
Doi: <https://doi.org/10.53424/balikesirsbd.1107580>



Is “Danger Zone” Really Dangerous? - An Endodontic Perspective

Deniz YANIK¹, Şelale ÖZEL²

¹ Antalya Bilim University, Faculty of Dentistry, Department of Endodontics

² Altınbaş University, Faculty of Dentistry, Department of Oral and Maxillofacial Radiology

Geliş Tarihi / Received: 25.04.2022, Kabul Tarihi / Accepted: 12.06.2022

ABSTRACT

Objective: To evaluate the accuracy of panoramic radiography in determining dentin thickness of danger zone (DZ) using cone-beam computed tomography (CBCT) imaging to examine the dentin thicknesses of the mandibular molars at different levels. **Materials and Methods:** For the study, 250 mandibular molars were selected. Dentine thicknesses were measured on panoramic radiography. On the CBCT view, dentine thicknesses of mesiobuccal (MB), mesiolingual (ML), and distal roots were measured. The reference point was determined as 3 mm, 4 mm, and 5 mm below the furcation of mandibular molars. Statistical analysis was performed. **Results:** The discrepancy between CBCT and panoramic was 0.5 mm for MB, 0.48 mm for ML, and 0.43 mm for distal. The difference in the dentin thickness between 3 mm and 5 mm is not statistically significant ($p>0.05$), whereas the 4 mm furcation level was significantly lower in either 3 mm or 5 mm for each root canal ($p<0.05$). This study showed that 0.5 mm distortion occurred in the danger zone on panoramic radiography. **Conclusion:** Our study showed that the dentin thickness of less than 1 mm in panoramic radiography is more prone to perforation because of distortion. The dentin thickness was lowest at 4 mm below the furcation. Our results can be a guide the clinicians in clinics or institutions where periapical radiography is not available.

Keywords: Cone-Beam Computed Tomography, Panoramic Radiography, Mandibular Molar, Endodontics, Root Canal Preparation.

“Tehlikeli Bölge” Gerçekten Tehlikeli mi?– Endodonik Bakış Açısı

ÖZ

Amaç: Çalışmanın amacı konik ışınli bilgisayarlı tomografi (KIBT) kullanarak tehlikeli bölgenin (TB) dentin kalınlığını belirlemede panoramik radyografinin doğruluğunu değerlendirmek ve mandibular azı dişlerinin dentin kalınlıklarını farklı seviyelerde incelemektir. **Gereç ve Yöntem:** Çalışma için 250 mandibular azı dişi seçildi. Panoramik radyografide dentin kalınlıkları ölçüldü. KIBT görüntüsünde mesiobukkal (MB), meziolingual (ML) ve distal köklerin dentin kalınlıkları ölçüldü. Referans noktası mandibular molarların furkasyonunun 3 mm, 4 mm ve 5 mm altı olarak belirlendi. İstatistiksel analiz yapıldı. **Bulgular:** CBCT ve panoramik arasındaki fark MB için 0.5 mm, ML için 0.48 mm ve distal için 0.43 mm idi. 3 mm ve 5 mm arasındaki dentin kalınlığındaki fark istatistiksel olarak anlamlı değildir ($p>0.05$), oysa 4 mm furkasyon seviyesi her bir kök kanalı için 3 mm ve 5 mm'de önemli ölçüde daha düşüktü ($p<0.05$). Bu çalışma, panoramik radyografide tehlike bölgesinde 0.5 mm distorsiyon oluştuğunu göstermiştir. **Sonuç:** Çalışmamız panoramik radyografide 1 mm'den az olan dentin kalınlığının distorsiyon nedeniyle perforasyona daha yatkın olduğunu göstermiştir. Dentin kalınlığı furkasyonun 4 mm altında en düşük seviyedeydi. Sonuçlarımız, periapikal radyografinin bulunmadığı kliniklerde veya kurumlarda klinisyenlere yol gösterici olacaktır.

Anahtar Kelimeler: Konik Işınli Bilgisayarlı Tomografi, Panoramik Radyografi, Mandibular Molar, Endodonti, Kök Kanal Şekillendirmesi.

Sorumlu Yazar / Corresponding Author: Deniz YANIK, Antalya Bilim University, Çıplaklı Mah, Faculty of Dentistry, 07040, Döşemealtı, Antalya, Turkey

E-mail: deniz.yanik@antalya.edu.tr

Bu makaleye atıf yapmak için / Cite this article: Yanık, D., & Özel, Ş. (2022). Is “danger zone” really dangerous? - An endodontic perspective. *BAUN Health Sci J*, 11(3), 411-419. <https://doi.org/10.53424/balikesirsbd.1107580>



BAUN Health Sci J, OPEN ACCESS <https://dergipark.org.tr/tr/pub/balikesirsbd>

This work is licensed under a Creative Commons Attribution-NonCommercial 4.0 International License

INTRODUCTION

Endodontic treatment of mandibular molars can be challenging for several reasons including irregular canal anatomy, severely curved roots, and inadequate dentin thickness. Curved roots and thin dentin may cause iatrogenic complications during canal preparation (De-Deus et al., 2019). The distal region of mesial roots in mandibular molars that have been termed the danger zone (DZ) can lead to strip perforations because of dentin thickness and over curved roots (Azimi et al., 2020). Excessive removal of dentin in the DZ during endodontic treatment can potentially result in strip perforation. Strip perforation (stripping) is a vertical, oblong perforation type that generally occurs in DZ of curved root canals and can be hard to diagnose. This type of perforation consequently causes complications difficult to treat such as vertical root fracture, lateral lesion, alveolar bone destruction, and extrusion of filling materials (Estrela et al., 2017).

The DZ is a risky area that needs to be examined correctly and adequately before root canal treatment to avoid impaired tooth integrity. As typically seen in the cross-sectional views, the canals are not located in the anatomical center of the root (De-Deus et al., 2019). They can be found close to furcal concavities. Overpreparation with nickel-titanium (Ni-Ti) instruments of canals increases the risk of strip perforation. Large Ni-Ti instruments are less flexible and have a worse centering ability. These files remove relatively more dentin on the thin side of the root and increase the incidence of strip perforation (Miguéns-Vila et al., 2021). On the other hand, regardless of instrumentation techniques and instruments, root dentin thickness in the DZ will be intrinsically thinner than the dentin thickness in the safe zone (mesial side of the mesial root) after instrumentation (De-Deus et al., 2021).

Panoramic radiography is the most commonly used radiographic technique for the examination of teeth in general dentistry. It is preferred due to its low exposure dose, low cost, and accessibility. Although panoramic radiography is an excellent diagnostic tool that can give the clinician an overall view of the dentoalveolar structures, significant linear image distortion that occurs in panoramic radiography, makes panoramic radiography inadequate because of the distortion that occurs in the measurement (Rahmel & Schulze, 2019). Furthermore, three-dimensional (3D) structures of dentoalveolar tissues make the two-dimensional (2D) imaging techniques inadequate. Cone-beam computed tomography (CBCT) allows 3D examination and thus has a superior ability to evaluate root anatomy than panoramic radiography in the diagnosis of endodontic pathologies. However, CBCT imaging is considered a second-level examination and does not replace panoramic radiography for every diagnostic procedure (Rahmel & Schulze, 2019).

Routinely, the most used radiographic modality to accompany endodontic therapy is the periapical

radiograph (Nardi et al., 2008). Even though most clinics and dental hospitals use periapical radiography to investigate dental structures before endodontic treatment, some institutions can only use panoramic radiography before endodontic treatment, for instance, in some military clinics or areas where the periapical modality is not available temporarily or permanently. Therefore, radiological data obtained from panoramic radiography has diagnostic importance for a successful endodontic treatment. No previous studies have demonstrated the accuracy of panoramic radiographs to evaluate DZ in mandibular molars. The present study aims to evaluate the clinical reliability of panoramic radiography with CBCT imaging as the reference standard for assessing the dentin thickness at the DZ as well as at different levels of each root of the mandibular molars. Our null hypothesis is that panoramic radiography has no diagnostic reliability for dentin thickness of the danger zone.

MATERIALS AND METHODS

Study type

The present study was designed as a retrospective study.

Study group

The study group consisted of 96 patients (49 females and 47 males) aged 30-35 years, who attended a dental clinic between June 2018 and July 2019 and were referred for panoramic radiography and CBCT examinations for various indications. Images of the patients were retrospectively evaluated. For the study, 250 mandibular molars were selected (120 mandibular first molars and 130 mandibular second molars). The inclusion criterion was the presence of at least one mandibular molar with completion of root formation. Extreme crown damage, furcation lesion, severe periodontal lesion, distal roots with two canals, mesial roots with one canal, C-canals, endodontic treated teeth, teeth with a post-core reconstructed, an undeveloped tooth with a wide-open apex, and internal and external root resorption were excluded from the study. Poor quality CBCT images with artifacts were also excluded from the study.

Procedures

All measurements were performed by the same oral maxillofacial radiologist (six-years' experience) and the endodontist (6 years' experience) blinded to patients' data. All images were evaluated twice by one specialist at two-week intervals.

Panoramic images were acquired with Orthophos (Sirona Dental Systems, Bensheim, Germany). The images were assessed in sagittal planes. Dentin thicknesses of the distal aspect of the mesial root and mesial aspect of the distal root were measured at 3 mm, 4 mm, and 5 mm below the furcation for mesial and distal canals respectively (Figure 1). Curvature in mesiobuccal (MB) and mesiolingual (ML) canals cannot be evaluated radiographically because of superimpositions and the thinnest area was recorded.

Dentin thickness was measured with Sidexis (Sirona Dental Systems, Inc, USA) at x12 magnification.

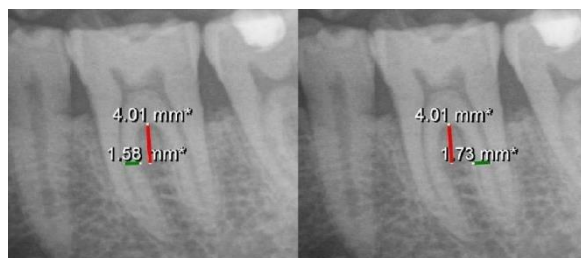

Figure 1. Measurement of mesial (left) and distal (right) dentin thicknesses on panoramic radiography 4 mm below furcation.

CBCT images were obtained using Orthophos (Sirona Dental Systems, Bensheim, Germany). Imaging parameters were set as 85 kV, 6 mA, 14.1 s exposure time, 0.2 mm voxel size, and 80x40 mm field of view. Images were examined at x12 magnification. Mandibular molars were evaluated in sagittal and axial planes. For each canal, the distance between the external surface of the root and the outer border of the canal was measured at 3 mm, 4 mm, and 5 mm below the furcation. The measurements were performed at the location, where dentin thickness was the smallest (Figure 2).

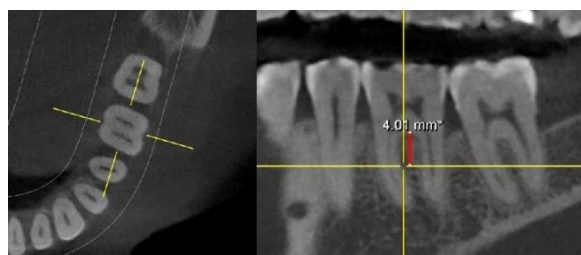

Figure 2. Measurement of dentin thicknesses on CBCT 4 mm below furcation in the axial plane (left) and the sagittal plane (right)

Statistical analysis

SPSS version 26.0 for Windows (IBM Corp., Armonk, NY, USA) was used for statistical analysis. The distribution of the data was analyzed by Bland-Altman analysis. The comparison of measurement methods, regression, and correlation analysis as a statistical method is not appropriate for the present study to not assess the relationship between CBCT and panoramic images Bland-Altman analysis was used to analyze the data as it was more suitable to compare the two methods (Bland & Altman, 1986).

One-Way-ANOVA and post hoc Bonferroni tests were utilized to compare measurements between 3 mm, 4 mm, and 5 mm below the furcation level. One-Way ANOVA was applied to compare dentin thicknesses between MB,

ML, and distal root canals. Differences were considered significant for $p < 0.05$.

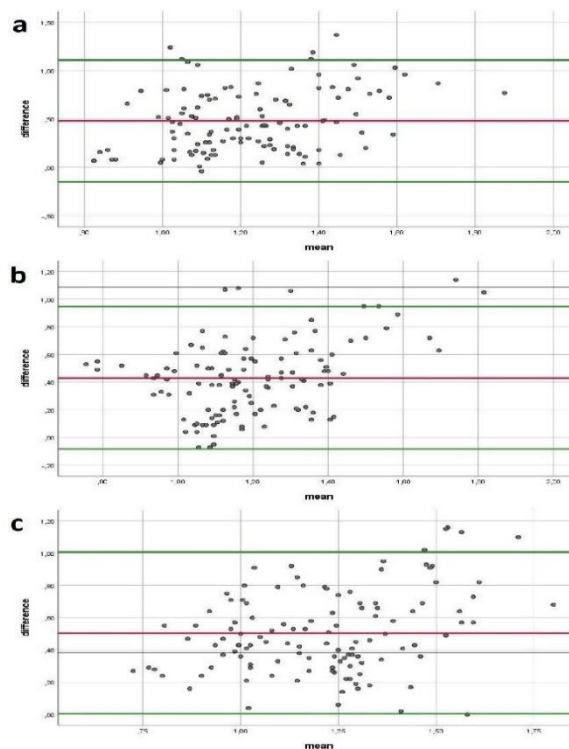
Interobserver and intraobserver agreements were evaluated using the intraclass correlation coefficient (ICC). Based on a 95% confidence interval (CI) the results were classified into 4 groups as poor (ICC values less than 0.5), moderate (ICC values between 0.5 and 0.75), good (ICC values between 0.75 and 0.9), and excellent (ICC values greater than 0.9) (Mattos et al., 2014).

Ethical considerations

The present study was accomplished in accordance with the guidelines outlined in the Declaration of Helsinki and was approved by the Akdeniz University Ethics committee (2019, #70904504/617).

RESULTS

Ninety-six (96) patients with mean ages of 33.64 ± 0.27 were included in the study. Table 1 and graphic 2 show the dentin thickness values at various levels of distal, MB, and ML root canals on CBCT images. At least half of root canals have dentin thicknesses less than 1mm at the DZ on CBCT images. The distribution of levels of thinnest dentin thickness is shown in graphic 3.



Graphic 1. Bland-Altman plots. (a) The mean difference is 0.43 mm between measurements in panoramic and CBCT for the distal canal, (b) the mean difference is 0.5 mm between measurements in panoramic and CBCT for the mesiolingual canal, (c) the mean difference is 0.48 mm between measurements in panoramic and CBCT for the mesiolingual canal.

The Bland-Altman plots show that the means of differences between panoramic and CBCT measurements for distal, MB, and ML were 0.43 mm, 0.5 mm, and 0.48 mm, respectively (Graphic 1).

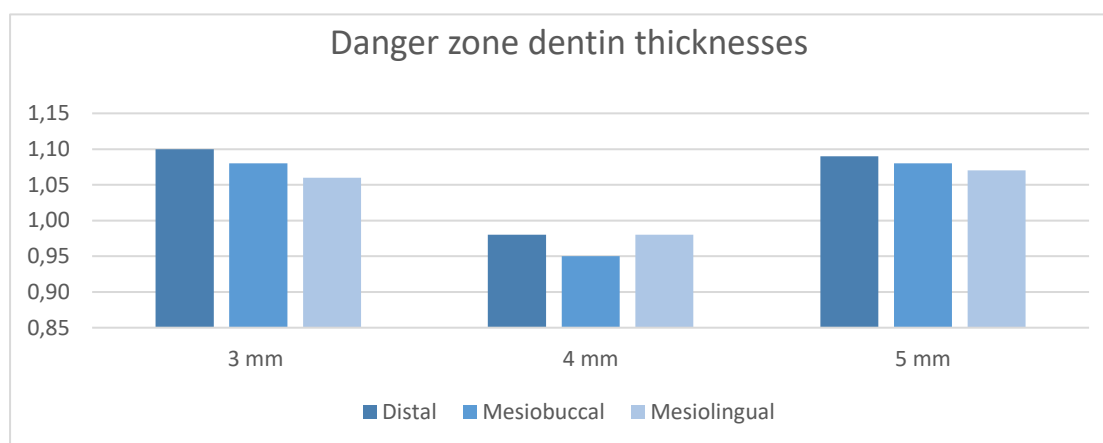
According to the Bland-Altman plots, 95% limits of agreement between the two methods ranged from 0.94

to -0.08; 1 to -0.03; and 1.1 to -0.14 for distal, MB, and ML canals, respectively. Interobserver and intraobserver agreement were excellent for both methods (ICC>0.9).

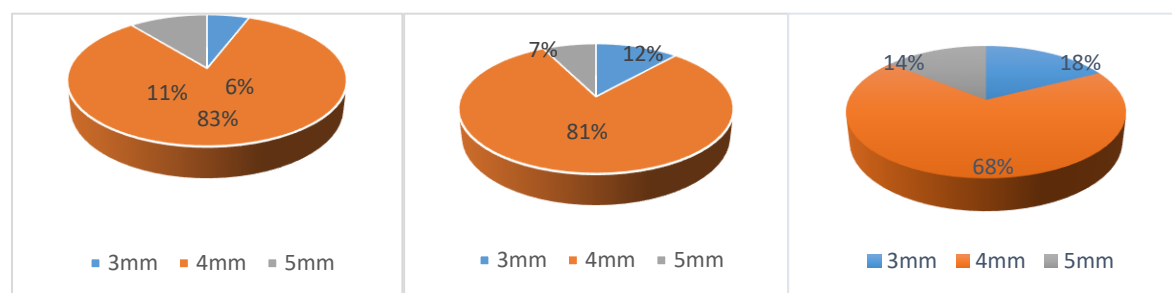
Table 1. Dentin thickness values (in millimeters) at various levels.

Root Canals	Furcation level	Mean±SD	Range	Number of canals with <1 mm of dentin
Distal canal	3mm	1.1±0.18	1.47-0.59	35 (29.1%)
	4mm	0.98±0.18	1.38-0.49	53 (44.1%)
	5mm	1.9±0.17	1.52-0.56	25 (20.8%)
Mesibuccal canal	3mm	1.08±0.2	1.6-0.67	45 (37.5%)
	4mm	0.95±0.21	1.58-0.53	64 (53.3%)
	5mm	1.08±0.21	1.57-0.59	43 (35.8%)
Mesiolingual canal	3mm	1.06±0.2	1.56-0.61	41 (34.1%)
	4mm	0.98±0.21	1.49-0.4	61 (50.8%)
	5mm	1.07±0.21	1.72-0.52	39 (32.5%)

SD: Standard deviation.



Graphic 2. Dentin thicknesses of the danger zone in the distal, mesibuccal, and mesiolingual canals at 3 mm, 4 mm, and 5 mm.



Graphic 3. Pie chart of thinnest dentine levels around the distal canal (left), the mesibuccal canal (middle), and the mesiolingual canal (right).

Based on One-Way ANOVA, there is no statistically significant difference in dentin thickness between MB, ML, and distal root canals. The difference in the dentin thickness between 3 mm and 5mm below the furcation is not statistically significant ($p>0.05$ Bonferroni test),

whereas, at 4mm below furcation level, the dentin thickness is significantly lower than that at both 3 mm and 5mm below the furcation for each of the root canals ($p<0.05$ Bonferroni test) (Table 2).

Table 2. Comparison of dentine thickness values for each level below the furcation area.

Root Canals	I(level)	J (level)	Mean Difference (I-J)
Distal canal	3mm	4mm	0.12308*
		5mm	0.00483
	4mm	3mm	-0.12308*
		5mm	-0.11825*
	5mm	3mm	-0.00483
		4mm	0.11825*
Mesiobuccal canal	3mm	4mm	0.12342*
		5mm	-0.00600
	4mm	3mm	-0.12342*
		5mm	-0.12942*
	5mm	3mm	0.00600
		4mm	0.12942*
Mesiolingual canal	3mm	4mm	0.08575*
		5mm	-0.00525
	4mm	3mm	-0.08575*
		5mm	-0.09100*
	5mm	3mm	0.00525
		4mm	0.09100*

*statistically significant differences between groups, according to ANOVA, $p<0.05$.

DISCUSSION

Our study showed a 0.5 mm distortion in the dentin thickness of the danger zone on panoramic radiography. Thus, our null hypothesis was rejected. In the literature, various methods are used to measure the DZ thickness such as periapical radiographs, CBCT, micro-computed tomography (micro-CT), and serial sections (Espir et al., 2018). Sectioning tooth is an invasive and destructive method used to determine dentin thickness. Lately, micro-CT has become a recommended technique for endodontic research (Cerqueira et al., 2021). Micro-CT has a high resolution due to the high radiation dose and allows non-destructive three-dimensional assessments. However, this technique is limited to laboratory use and is time-consuming (Junior et al., 2014). On the other hand, age is an important factor affecting dentin thickness. Results may change when the age factor is not considered in cross-sectional and micro-CT studies using stored teeth (De-Deus et al., 2019). The present study was performed in a specified age range (30-35 years) to prevent all variables and bias. Because the present study aimed to examine the accuracy of panoramic radiography of sound teeth,

micro-CT and cross-sectional methods used in extracted teeth are not suitable. CBCT provides detailed images of 3D anatomic structures without loss of information (Espir et al., 2018). In a previous study comparing micro-CT and CBCT measurements, it was shown that CBCT was sufficient to examine dentin thickness (Xu et al., 2017). For all these reasons, CBCT was preferred as the reference standard to compare the accuracy of the panoramic images.

The statistical analysis of the comparison between the two methods includes Bland-Altman, linear regression, and correlation analysis. Correlation and linear regression analysis evaluate the relationship between two quantitative measurement methods and are improper for our study. In the present study, the Bland-Altman analysis was applied to compare the two methods. The Bland-Altman analysis uses the mean difference and limits of agreement to compare the two methods. The goal of Bland-Altman analysis is to evaluate bias between mean differences in methods (Gerke, 2020).

One of the critical factors of treatment planning is diagnostic information gained from the clinical and

radiological examination. Three-dimensional imaging techniques such as CBCT present more information than 2D images because of reducing or eliminating superimpositions. Therefore, CBCT is also recommended before endodontic treatment for the high accuracy of measurements (Asgary et al., 2016). Although CBCT has a very high diagnostic accuracy, there are several disadvantages such as high radiation dose. According to “as low as reasonably achievable (ALARA)” principles some researchers do not recommend routine usage of CBCT before endodontic treatment (Hiebert et al., 2017).

Periapical radiographs are used frequently as a preoperative diagnostic tool in routine clinical examinations and an essential part of endodontic management (Asgary et al., 2016). Panoramic radiography gives insight into the morphology and anatomy of a tooth to the clinician. The results of our study provided diagnostic information for dental clinics or hospitals that only use panoramic radiography before endodontic treatment. We aimed to guide the results of our study to clinicians in institutions or military clinics where periapical radiography is not available.

This is the first study to examine the accuracy of dentin thickness in the DZ on panoramic radiography. The differences between the two methods were found to be 0.5 mm for MB, 0.48 mm for ML, and 0.43 mm for the distal canal. These results might be attributed to the image distortion and horizontal magnification properties of panoramic radiography.

The enlargement of the canal during endodontic instrumentation can cause a decrease in the dentin thickness. A previous study showed that the amount of substance loss in DZ was greater than in the safety zone (Sousa et al., 2015). This reduction is a critical factor for prognosis in areas where dentin thickness is already thin. The results of the present study were considered clinically important. Because it has been reported that 0.15-0.24 mm dentin is removed in endodontic treatment during instrumentation (Oliver et al., 2016). Besides, the minimum dentin thickness required to prevent root fracture against the compaction forces applied during filling was 0.2-0.3 mm (Lim & Stock, 1987). According to previous literature information and the results of our study, an approximate formula has been created. ‘The danger limit Formula’ was created as follows;

The danger limit (X) (mm, on panoramic radiography) = -0.5 mm (panoramic distortion effect) -[0.15~0.24](removed during endodontic instrumentation) +[0.2~0.3](required for compaction forces).

So, the danger limit (X) can be considered as 0.9~1 mm. The dentin thickness of less than 0.9-1 mm measured on the panoramic image may be considered hazardous for strip perforation. This approximate formula provides an idea of the minimum amount of dentin thickness required to maintain the integrity of the tooth after endodontic treatment without

perforation. However, this formula does not give a clear idea about the susceptibility to fracture against the masticatory forces and the survival rate of the tooth. A previous study concluded that dentin thickness of less than 1.3 mm was a risk factor for fracture (Silva et al., 2020). Another study reported that the minimum dentin thickness required for post-core treatment is 1 mm to prevent root fracture (Raiden et al., 2001). For the teeth that require post-treatment, the danger limit (Xp) can be considered as 1.9~2 mm. So the clinician should be careful when measuring 1.8-2 mm dentin thickness on panoramic radiography.

There are numerous studies to measure the dentin thickness of DZ which is between 0.78 and 1.25 (De-Deus et al., 2019; Junior et al., 2014; Kessler et al., 1983). In the present study, the DZ dentin thickness on CBCT was found to be 0.95, 0.98, and 0.98 for MB, ML, and D canals, respectively. In the current study, there is no statistically significant difference was observed in dentin thicknesses between MB, ML, and distal root canals. The results of our study were similar to those of previous studies found no differences in dentin thicknesses between MB and ML root canals (Harris et al., 2013; Garala et al., 2003).

On the other hand, there were differences in the average dentin thicknesses measured in the studies due to factors such as the method used, the method of measurement (if the measurement was repeated, how many examiners measured, etc.), the examiner's expertise, and differences in cross-sectional levels. In these studies, measurements were performed 2-5 mm below the furcation region (De-Deus et al., 2019; Junior et al., 2014; Kessler et al., 1983). Differences in cross-section levels may also result in different results. In the present study, measurements were performed at 3mm, 4 mm, and 5 mm below furcation, respectively. Some previous studies have concluded that the most sensitive levels were 3 to 4 mm below the furcation (Abou-Rass et al., 1980; Lazzaretti et al., 2006). Kessler et al. (1983) who measured 2-3 mm below furcation, found the danger zone thickness to be higher than the present study. The various results in the literature can be explained by the differences in anatomical parameters of methodologies and the root curvature changes at different levels of the root. The present study demonstrated that the measurement at 4 mm below the furcation presented significantly thinner dentin thickness compared to the other two levels (3 mm and 5 mm). In a previous study, using micro-CT, the DZ thickness was found to be 1.25 mm for the mesial root and 1.09 mm for the distal root (Junior et al., 2014). These results obtained from the middle third of the root are not similar to the results of the present study. However in that study; the measurement region, distance to furcation, how many examiners, and how many times were measured were not clearly defined. In the current study, these criteria were made clear.

The dentin thickness at 4 mm below the furcation has clinical importance because the curvature and concavity were quite prominent at this level. The average depth of concavity in DZ of the mesial roots ranges from 0.86 to 1.04 mm (Sauaia et al., 2010). Thus, this area is subject not only to strip perforation but also to the origin of the root fractures. Regions where the depth of the concavity is increased and the dentin thickness is reduced can be considered the focus of clinical failures including furcation lesions, perforation, and fractures.

Abou-Rass et al. (1980) recommended an anti-curvature technique to prevent strip perforation. The brushing motion technique to remove dentin equally from all canal walls has been recommended (Peters et al., 2008). 'Brushing' too much on the thin and concave walls can be likely to increase the risk of perforation. Numerous studies evaluated canal transportation and the centering ability of various systems and different kinematics (Liu et al. 2016; Silva et al., 2017). One of the main goals of these systems is to maintain the original form of the canal. Results of the present study have shown that without further imaging, the canal anatomy and dentin thickness cannot be accurately monitored on panoramic images. Therefore, there should not be any deviations in the shape of the canal during preparation. Our study showed that the thinnest dentin was observed 4 mm below the furcation. According to the data obtained from CBCT measurements, the MB root is the region with the thinnest dentin in DZ. Due to the superposition and distortion that occurred in the panoramic radiography, it is not possible to accurately examine the MB canal, which is the riskiest location with the thinnest dentin. Misidentification of the root canal is a predisposing factor for root perforations. Akhlaghi et al. (2010) reported the greatest ratio of dentin removal during instrumentation in the DZ on the distolingual aspect of the MB canal in the mid-root of mandibular molars compared to other walls. In the present study, CBCT measurements were performed from this distolingual wall (the thinnest part observed in the axial cross-section) and it was concluded that the panoramic film was misleading because the concave distolingual area was superposed. Consequently, clinicians should carefully examine to avoid instrumentation-related strip perforation in this concave area.

In this study, a specific age range was included for the evaluation of DZ to eliminate the effect of the deposition of the secondary dentin. DZ thickness is increased with age and pulp volume is decreased (Star et al., 2011). Due to the thin dentin thickness in young teeth, clinicians should be careful in root canal preparations in terms of strip perforation, especially in root curvature.

The limitations of this study are the small number of samples and to use of CBCT for investigating the dentin thickness of DZ. However, the strength of our study is that it is the first study to investigate the

accuracy of panoramic radiography for dentin thickness in DZ. Our results are concerning clinicians in institutions where periapical radiography does not exist and provide information about the danger zone before endodontic treatment. Further studies with a larger sample size would evaluate dentine thicknesses with different levels.

CONCLUSION

DZ on panoramic radiography. Within the limitations of this study, on panoramic radiography, 0.5 mm distortion occurred in the DZ. CBCT reveals root concavity that must be recognized before treatment to avoid strip perforation. The dentin thickness of less than 1 mm is the most prone to perforation. It is recommended to refer to CBCT data if the dentin thickness of the DZ measured less than 1 mm on panoramic radiography. The dentin thickness was lowest at 4 mm below the furcation. To reduce strip perforation during endodontic treatment, root canal morphology should be evaluated correctly by the clinician.

Conflict of Interest

The authors declare no potential conflicts of interest concerning the research, authorship, and/or publication of this article.

Author Contributions

Plan, design: DY, ŞÖ; **Material, methods, and data collection:** DY, ŞÖ; **Data analysis and comments:** DY, ŞÖ; **Writing and corrections:** DY, ŞÖ.

REFERENCES

- Abou-Rass M, Frank AL, Glick DH. (1980). The anticurvature filing method to prepare the curved root canal. *Journal of American Dental Association*, 101, 792-794.
<https://doi:10.14219/jada.archive.1980.0427>
- Akhlaghi NM, Kahali R, Abtahi A, et al. (2010). Comparison of dentine removal using V-taper and K-Flexofile instruments. *International Endodontic Journal*, 43, 1029-1036.
<https://doi:10.1111/j.1365-2591.2010.01769.x>
- Asgary S, Nikneshan S, Akbarzadeh-Bagheban A, et al. (2016). Evaluation of diagnostic accuracy and dimensional measurements by using CBCT in mandibular first molars. *Journal of Clinical and Experimental Dentistry*, 8:1-8.
<https://doi:10.4317/jced.52570>
- Azimi VF, Samadi I, Saffarzadeh A, et al. (2020). Comparison of dentinal wall thickness in the furcation area (danger zone) in the first and second mesiobuccal canals in the maxillary first and second molars using cone-beam computed tomography. *European Endodontic Journal*, 5(2), 81.
<https://doi:10.14744/eej.2020.18189>
- Bland J M, Altman D. (1986) Statistical methods for assessing agreement between two methods of clinical measurement. *Lancet*, 327:307-310.

- Cerqueira NM, Louzada VG, Silva-Sousa YTC. (2021). Effect of canal preparation with XP-endo Shaper and ProTaper Next on root canal geometry and dentin thickness of mandibular premolars with radicular grooves and two canals: a micro-CT study. *Clinical Oral Investigations*, 25, 5505–5512.
<https://doi:10.1007/s00784-021-03858-z>
- De-Deus G, Rodrigues EA, Belladonna FG, Simões-Carvalho M, et al. (2019). Anatomical danger zone reconsidered: a micro-CT study on dentine thickness in mandibular molars. *International Endodontic Journal*, 52,1501-1507.
<https://doi:10.1111/iej.13141>
- De-Deus G, Rodrigues EA, Lee JK, et al. (2021). Root groove depth and inter-orifice canal distance as anatomical predictive factors for danger zone in the mesial root of mandibular first molars. *Clinical Oral Investigations*, 25(6), 3641-3649.
<https://doi:10.1007/s00784-020-03686-7>
- Espir CG, Nascimento CA, Guerreiro-Tanomaru JM, et al. (2018). Radiographic and micro-computed tomography classification of root canal morphology and dentin thickness of mandibular incisors. *Journal of Conservative Dentistry*, 21:57-62.
https://doi:10.4103/JCD.JCD_230_16
- Estrela C, Pécora JD, Estrela CR, et al. (2017). Common operative procedural errors and clinical factors associated with root canal treatment. *Brazilian Dental Journal*;28:179-190.
<https://doi:10.1590/0103-6440201702451>
- Garala M, Kuttler S, Hardigan P, et al. (2003). A comparison of the minimum canal wall thickness remaining following preparation using two nickel-titanium rotary systems. *International Endodontic Journal*, 36, 636–642.
<https://doi:10.1046/j.1365-2591.2003.00704.x>
- Gerke O. (2020) Reporting standards for a Bland–Altman agreement analysis: A review of methodological reviews. *Diagnostics*, 10(5), 334.
<https://doi:10.3390/diagnostics10050334>
- Harris SP, Bowles WR, Fok A, et al. (2013). An anatomic investigation of the mandibular first molar using micro-computed tomography. *Journal of Endodontics*, 39,1374–1378.
<https://doi:10.1016/j.joen.2013.06.034>
- Hiebert BM, Abramovitch K, Rice D, et al. (2017). Prevalence of second mesiobuccal canals in maxillary first molars detected using cone-beam computed tomography, direct occlusal access, and coronal plane grinding. *Journal of Endodontics*, 43, 1711-1715.
<https://doi:10.1016/j.joen.2017.05.011>
- Júnior ASA, Cavenago BC, Ordinola-Zapata R, et al. (2014). The effect of larger apical preparations in the danger zone of lower molars prepared using the Mtwo and Reciproc systems *Journal of Endodontics*, 40, 1855-1859.
<https://doi:10.1016/j.joen.2014.06.020>
- Kessler JR, Peters DD, Lorton L. (1983). Comparison of the relative risk of molar root perforations using various endodontic instrumentation techniques. *Journal of Endodontics*, 9,439-447.
[https://doi:10.1016/S0099-2399\(83\)80260-X](https://doi:10.1016/S0099-2399(83)80260-X)
- Lazzaretti DN, Camargo BA, Della Bona A, et al. (2006) Influence of different methods of cervical flaring on establishment of working length. *Journal of Applied Oral Science*,14351,-354.
<https://doi:10.1590/s1678-77572006000500010>
- Lim SS, Stock CJ. (1987). The risk of perforation in the curved canal: anticurvature filling compared with step-back technique. *International Endodontic Journal*, 20,33-39.
<https://doi:10.1111/j.1365-2591.1987.tb00586.x>
- Liu W, Wu B. (2016) Root canal surface strain and canal center transportation induced by 3 different nickel-titanium rotary instrument systems. *Journal of Endodontics*, 42, 299-303.
<https://doi:10.1016/j.joen.2015.10.023>
- Mattos CT, Cruz CV, da Matta TCS, et al. (2014). Reliability of upper airway linear, area, and volumetric measurements in cone-beam computed tomography. *American Journal of Orthodontics and Dentofacial Orthopedics*, 145,188-197.
<https://doi:10.1016/j.jado.2013.10.013>
- Miguéns-Vila R, Martín-Biedma B, De-Deus G, et al. (2021). Micro-computed Tomographic Evaluation of Dentinal Microcracks after Preparation of Curved Root Canals with ProTaper Gold, WaveOne Gold, and ProTaper Next Instruments. *Journal of Endodontics*, 47(2), 309-314.
<https://doi:10.1016/j.joen.2020.10.014>
- Nardi C, Calistri L, Grazzini G, et al. (2008). Is Panoramic Radiography an Accurate Imaging Technique for the Detection of Endodontically Treated Asymptomatic Apical Periodontitis? *Journal of Endodontics*, 44, 1500-1508.
<https://doi:10.1016/j.joen.2018.07.003>
- Olivier JG, García-Font M, Gonzalez-Sanchez JA, et al. (2016). Danger zone analysis using cone-beam computed tomography after apical enlargement with K3 and K3XF in a manikin model. *Journal of Clinical and Experimental Dentistry*, 8, 361-367.
<https://doi:10.4317/jced.52523>
- Peters OA, Koka RS. (2008). *Preparation of coronal and radicular spaces*. In: Ingle JI, Bakland LK, Baumgartner JC, eds. *Endodontics*, 6th ed; pp.:887– 991. Ontario: BC Decker Inc.
- Rahmel S, Schulze RK. (2019). Accuracy in detecting artificial root resorption in panoramic radiography versus tomosynthetic panoramic radiographs. *Journal of Endodontics*, 45(5), 634-639.
<https://doi:10.1016/j.joen.2019.01.009>
- Raiden G, Koss S, Costa L, et al. (2001). Radiographic measurement of residual root thickness in premolars with post preparation. *Journal of Endodontics*, 27, 296-298.
<https://doi:10.1097/00004770-200104000-00017>
- Sauáia TS, Gomes BPF, Pinheiro ET, et al (2010). Thickness of dentine in mesial roots of mandibular molars with different lengths. *International Endodontic Journal*, 43, 555-559.
<https://doi:10.1111/j.1365-2591.2010.01694.x>

- Silva EJNL, Pacheco PT, Pires F, et al. (2017). Microcomputed tomographic evaluation of canal transportation and centering ability of ProTaper Next and Twisted File Adaptive systems. *International Endodontic Journal*, 50:694-699. <https://doi:10.1111/iej.12667>
- Silva LR, de Lima KL, et al. (2020). Dentin thickness as a risk factor for vertical root fracture in endodontically treated teeth: a case-control study. *Clinical Oral Investigation*, 1-7. <https://doi:10.1007/s00784-020-03406-1>
- Sousa K, Andrade-Junior CV, Silva JM, et al. (2015). Comparison of the effects of Triple Gates and Gates-Glidden burs on cervical dentin thickness and root canal area by using cone-beam computed tomography. *Journal of Applied Oral Science*, 23:164-168. <https://doi:10.1590/1678-775720130542>
- Xu J, He J, Yang Q, et al. (2017) Accuracy of cone-beam computed tomography in measuring dentin thickness and its potential of predicting the remaining dentin thickness after removing fractured instruments. *Journal of Endodontics*, 43,1522-1527. <https://doi:10.1016/j.joen.2017.03.041>
- Star H, Thevissen P, Jacobs R, et al. (2011). Human dental age estimation by calculation of pulp-tooth volume ratios yielded on clinically acquired cone beam computed tomography images of monoradicular teeth. *Journal of Forensic Sciences*, 56, 77-82. <https://doi.org/10.1111/j.1556-029.2010.01633.x>