

Taş, N., et al., A Current and Common Cause of Secondary Spontaneous Pneumothorax: Covid- 19 Pneumonia. International Journal of Life Sciences and Biotechnology, 2022. 5(3). p. 562-571.  
DOI: 10.38001/ijlsb.1116153

## A Current and Common Cause of Secondary Spontaneous Pneumothorax: Covid- 19 Pneumonia

Nurmuhammet Taş<sup>1\*</sup>, Muhammet Emin Naldan<sup>2</sup>, Fatih Öner<sup>3</sup>,  
Yener Aydın<sup>4</sup>, Hülya Naldan<sup>5</sup>

### ABSTRACT

This study evaluated cases of spontaneous pneumothorax developing secondary to SARS-CoV-2 pneumonia. Sixteen cases presenting to our hospital due to spontaneous pneumothorax developing secondary to SARS-CoV-2 pneumonia between March 2020 and February 2020 were evaluated retrospectively. Ten patients (62.5%) were men, and six (37.5%) were women, with a mean age of 68 ±20.3 years (range 18 - 90 years). Pneumothorax was in the right hemithorax in 11 cases (68.75%), in the left hemithorax in two (12.5%), and bilateral in three (17.75%). Pneumothorax developed during active SARS-CoV-2 pneumonia in all 16 cases (100%). No pneumothorax was detected following the healing of SARS-CoV-2 infection. Pneumothorax was observed while patients were not intubated in 15 cases (93.75%), but pneumothorax developed during mechanical ventilation in one case (6.25%). Tube thoracostomy was performed on all patients in treatment. Air leakage from the tube was observed in 14 cases (87.5%). The mean duration of tube thoracostomy was 18.3 ±20.1 days (range 1 - 81 days). Pneumothorax resolved after treatment in seven cases (43.75%), while mortality occurred in nine (56.25%). Pneumothorax recurred after treatment in one case (6.25%). Pneumothorax is widely seen in the active period or after healing in cases infected with COVID-19. Aggressive treatment is generally required for this clinical manifestation with high mortality.

### ARTICLE HISTORY

**Received**

13 May 2022

**Accepted**

22 October 2022

### KEYWORDS

SARS-CoV-2 pneumonia, pneumothorax, management

## Introduction

Pneumothorax occurring due to any underlying pulmonary disease without trauma or iatrogenic intervention is secondary spontaneous pneumothorax (SSP). The annual incidence of SSP is reported at 6.3 and 2 per 100,000 in men and women, respectively

<sup>1</sup> Department of Physical Medicine and Rehabilitation, Erzurum Regional Education and Research Hospital, Erzurum, Türkiye

<sup>2</sup> Department of Anesthesiology and Reanimation, Erzurum Regional Education and Research Hospital, Erzurum, Türkiye

<sup>3</sup> Department of Otorhinolaryngology, Erzurum Regional Education and Research Hospital, Erzurum, Türkiye

<sup>4</sup> Department of Thoracic Surgery, Medical Faculty, Ataturk University, Erzurum, Türkiye

<sup>5</sup> Medicinal and Aromatic Plants Specialist, Erzurum Regional Education and Research Hospital, Erzurum, Türkiye

\*Corresponding Author: Nurmuhammet Taş, e-mail :nu\_mu\_ta@hotmail.com

[1]. The most frequently detected causes of SSP are pulmonary emphysema, interstitial lung disease, lung cancer, and tuberculosis [1, 2].

The disease caused by Severe Acute Respiratory Syndrome-Coronavirus 2 (SARS-CoV-2) and first reported from the Chinese city of Wuhan in December 2019 was given the name Coronavirus Disease 2019 (COVID-19) by the World Health Organization (WHO) [3]. The infection that then spread rapidly across the world can exhibit a broad clinical spectrum, from an asymptomatic form to fatal complications. Pulmonary symptoms such as cough, dyspnea, and chest pain, and severe cases of pneumonia are frequently encountered symptoms and findings. Large numbers of cases of pneumothorax associated with SARS-CoV-2 have recently begun being reported worldwide [4-6]. This study evaluated cases of SSP developing in cases with previous or current SARS-CoV-2 pneumonia in the light of the current literature.

## **Material and Methods**

This retrospective and a single-center study was performed in Erzurum Training and Research Hospital, Turkey. The study protocol was approved by the Institutional Review Board of the Ministry of Health Human Subjects Research and Ethical Committee. The research was performed in compliance with the ethical principles of the Declaration of Helsinki. Sixteen consecutive cases treated in our hospital, a pandemic hospital in the city of Erzurum, due to SARS-CoV-2-related SSP, between March 2020 and February 2021 were evaluated retrospectively.

The SARS-CoV-2 diagnosis was made in the laboratory using real-time reverse transcription-polymerase chain reaction (RT-PCR) of nasopharyngeal swab samples. Cases with primary spontaneous pneumothorax or SSP for any reason other than COVID-19, a negative real-time reverse transcriptase polymerase chain reaction test result for COVID-19, and identified iatrogenic pneumothorax were not included in the study. Direct posteroanterior chest x-rays and thoracic computed tomography (CT) were used for preoperative diagnosis in all cases. Tube thoracostomy was decided by the clinical team responsible for the patient. Large diameter chest tubes were placed in patients for pneumothorax. Thoracic drains were connected to watertight chest drainage systems. Age, gender, comorbidity, pneumothorax location, radiological characteristics, the treatment applied, and morbidity, mortality, and recurrence rates were reviewed retrospectively.

## Results

Ten (62.5%) of the cases were male, and six (37.5%) were female, with a mean age of  $68 \pm 20.3$  years (range 18 - 90). A history of smoking was present in 10 (62.5%) cases. In terms of comorbidities, chronic obstructive pulmonary disease (COPD) was detected in six cases (37.5%), heart failure in four (25%), and diabetes mellitus in one (6.25%). Dyspnea was present in all 16 cases (100%) at the time of presentation, cough in 16 (100%), and chest pain in nine (56.25%).

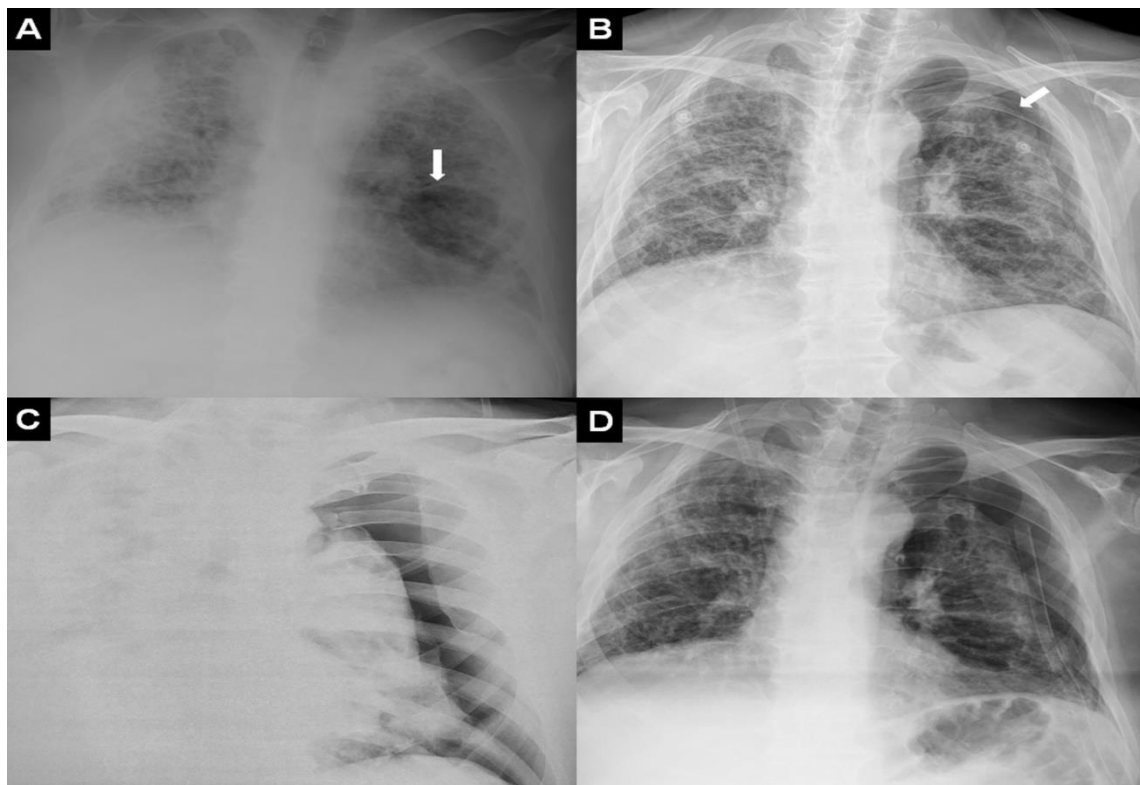
Pneumothorax was located in the right hemithorax in 11 cases (68.75%), in the left hemithorax in two (12.5%), and bilateral in three (18.75%) (Figure 1). Pneumothorax developed during active SARS-CoV-2 pneumonia in all 16 cases. No pneumothorax was detected following SARS-CoV-2 infection treatment. Pneumothorax was observed while the patient was not intubated in 15 cases (93.75%) and developed during mechanical ventilation in one (6.25%). Accompanying mediastinal emphysema was present in five cases (31.25%), subcutaneous emphysema in four (25%), and pleural effusion in 10 (62.5%) (Figure 1).

## Discussion

Covid-19 pneumonia-related pneumothorax was detected in 16 cases. The mean age of the patients was 68. Ten (62.5%) had a history of smoking, and comorbidities such as COPD, heart failure, hypertension, and diabetes mellitus were observed in all 16 (100%). Pneumothorax developed spontaneously rather than when the patient was intubated in 15 cases (93.75%) and developed in association with barotrauma during mechanical ventilation in one case (6.25%). Accompanying mediastinal emphysema was present in five cases (31.25%), subcutaneous emphysema in four (25%), and pleural effusion in 10 (62.5%). Tube thoracostomy was applied in all cases during treatment. The mortality rate was 56.25%.

The clinical course of COVID-19 is unpredictable and ranges from asymptomatic to subclinical symptoms to acute disease with acute respiratory distress syndrome (ARDS) and organ failure. The SARS-CoV-2 virus has been shown to enter the cell through angiotensin-converting enzyme 2 (ACE-2) receptors in humans. The virus, therefore, first causes interstitial damage in the lungs, followed by parenchymal damage. Due to its high

sensitivity and rapid availability, thoracic CT plays an essential role in diagnosing and treating COVID-19 infection, showing pulmonary involvement and its severity. It is also the most sensitive imaging technique for determining small amounts of pneumomediastinum and pneumothorax [7]. Due to the more widespread recognition of thoracic CT findings, various CT algorithms have been developed. Typical and atypical disease findings have been determined. Typical findings at thoracic CT include ground-glass opacity, consolidation, a reticular pattern, a crazy-paving appearance, air bronchograms, airway changes, and nodules (maybe with halo and reversed halo signs). Reported atypical findings include lymphadenopathy, pleural effusion, pericardial effusion, and cavitation [8, 9].



**Fig 1** (A) Widespread pulmonary involvement and an air cyst (arrow) on the left side associated with COVID-19 pneumonia in a 65-year-old male patient. (B) Pneumothorax (arrow) developed at x-ray three days later. (C) The pneumothorax became more pronounced at control x-ray. (D) Direct x-ray following tube thoracostomy

Tube thoracostomy was performed in the treatment of all patients. Air leakage from the chest tube was observed in 14 cases (87.5%). The mean duration of tube thoracostomy was  $18.3 \pm 20.1$  days (range 1 - 81 days). Pneumothorax resolved after treatment in seven

cases (43.75%), while mortality occurred in nine (56.25%). Pneumothorax recurred after treatment in one case (Table 1).

**Table 1** Patient characteristics

		Count	%
Gender	Male	10	62.5%
	Female	6	37.5%
Age (years)		68±20.3(18-90)	
Localization of pneumothorax	Right	11	68.75%
	Left	2	12.5%
	Bitateral	3	18.75%
Smoking status	Yes	10	62.5%
	No	6	37.5%
Comorbidities	COPD	6	37.5%
	Asthma	0	0%
	Systemic hypertension	6	37.5%
	Coronary artery disease	4	25%
	Type 2 diabetes mellitus	1	6.25%
	Hyperlipidemia	1	6.25%
	Chronic kidney disease	1	6.25%
Symptoms	Dyspnea	16	100%
	Chest pain	9	56.25%
	Cough	16	100%
	Backache	3	18.75%
	Sputum	10	62.5%
	Asymptomatic	0	0%
	Yes	1	6.25%

Unilateral or bilateral, peripheral, subpleural ground-glass opacities are the most common finding in COVID-19 infection, being seen in approximately 90% of patients. Ground glass opacity is also known to be the earliest radiological finding of the disease. This appearance is thought to be associated with edema in the lungs and the hyaline membrane. Ground glass can be seen alone or also together with findings such as interlobular septal thickening and consolidation. Consolidations are generally multifocal, segmental, or patchy in patients with COVID-19 infection and are generally subpleural or peribronchovascular in location. In terms of pathophysiology, consolidations are thought to be associated with fibromyxoid exudates in alveoli. In addition, the presence of consolidation is associated with disease prognosis and may be an indication of progressive disease [8-10]. A ground-glass appearance was observed in 100% of our case series, consolidation in 43.74%, and fibrosis in 81.25%.

The most frequent symptoms of SARS-CoV-2 infection are fever, cough, and respiratory difficulty. Pneumothorax development is reported in a very small proportion of these patients [4]. COVID-19 patients developing SSP more commonly present with dyspnea, tachypnea, and hypoxia. However, all these features are frequently seen in patients with severe COVID-19. Interestingly, chest pain has been observed significantly more frequently in association with pneumothorax development [6].

The proposed mechanism involved in spontaneous pneumothorax in patients with COVID-19 disease has been linked to structural changes in the lung parenchyma. These include cystic and fibrotic changes leading to tearing of the alveolar wall associated with an increasing pressure difference between the alveoli and the pulmonary interstitium. The possibility of pneumothorax development has been emphasized in the case of bronchiolar distortion and narrowing caused by SARS-CoV-2, leading to COVID-19 pneumonia and pulmonary blistering resulting from severe alveolar damage. Increased intrathoracic pressure deriving from prolonged cough and/or mechanical ventilation is another significant factor [4, 7, 10-12]. Both pneumothorax and pneumomediastinum are known mechanical ventilation complications associated with intubation. Additionally, pneumothorax or pneumomediastinum, or more rarely both, can be seen in COVID-19 even in the absence of barotrauma [4].

Among patients requiring prolonged respiratory support, such as in COVID-19 pneumonia, mechanical ventilation creates a persistent alveolar pressure trend capable of accelerating cyst rupture, causing air leakage from the pulmonary tissue. This air can pass through the visceral pleura and give rise to subpleural air cysts. Pneumothorax frequently occurs due to the tearing of these subpleural air cysts. Escaping air sometimes leads to pneumomediastinum, pneumoperitoneum, or subcutaneous emphysema, respectively, by dissection through the perivascular and peribronchial vascular sheath into the mediastinum, retroperitoneum, and subcutaneous tissue. Pneumothorax can also occur in the case of mediastinal pleura rupture following pneumomediastinum development.

Moreover, the probability of such destructive complications is particularly exacerbated by prolonged high-pressure mechanical ventilation. This is because it triggers the formation and progression of new alveolar cysts that eventually rupture, causing the air to spread to various interconnected body cavities [13]. Ozdemir et al. [14] reported a rate of pneumothorax development of 7.5% in patients undergoing mechanical ventilation following diagnosis of COVID-19 pneumonia in the intensive care unit. Talan et al. [15] reported admitting 161 patients to the intensive care unit due to COVID-19 pneumonia that 96 patients underwent mechanical ventilation, and that pneumothorax, pneumomediastinum, and/or subcutaneous emphysema developed in nine of these.

Pneumothorax is a potential complication in some pulmonary infections and is particularly frequently seen in *Pneumocystis jirovecii* pneumonia. The true incidence of SSP in patients with COVID-19 is currently unknown. Some sporadic cases of pneumothorax development in COVID-19 patients have been reported. Invasive or non-invasive mechanical ventilation was applied before pneumothorax developed in some cases, while in others, pneumothorax appeared after pulmonary involvement lasting several weeks with extensive inflammatory infiltration in the pulmonary parenchyma and cyst formation [6]. Pneumothorax seen after recovery from Covid-19 pneumonia is not yet fully understood but is thought to result from persistent chronic inflammatory changes and a delayed alveolar tear as part of the ongoing chronic disease process [16]. These cases suggest that pneumothorax is a complication of COVID-19.

One study from the UK evaluated six cases of pneumothorax from 16 centers. Two consecutive pneumothorax episodes were observed in two cases, and additional accompanying pneumomediastinum was present in six. The incidence of pneumothorax

was higher among male patients. Thirty-two percent of the patients developing pneumothorax consisted of cases in which pneumothorax developed spontaneously without any non-invasive ventilation or intubation. The estimated incidence of pneumothorax in COVID-19 cases is 0.91% [17]. Miró et al. [6] reported spontaneous pneumothorax development in 40 (0.056%) out of 71,904 cases diagnosed with COVID-19. This was higher than the rate of pneumothorax development in patients without COVID-19. Zantah et al. [11] reported that pneumothorax developed spontaneously in six (0.66%) out of 3368 cases of suspected COVID 19 pneumonia presenting to institutions. Consistent with the previous literature, pneumothorax was more common in males in the present study. This may be due to men in large series of patients with COVID-19 being more frequently affected by severe forms of the disease.

Pneumothorax can range from asymptomatic to a life-threatening condition. Small pneumothoraces in clinically stable patients can be managed with observation. However, larger pneumothoraces with hemodynamic imbalance require active intervention in order to avoid destructive sequelae. Delayed pneumothorax can be treated with tube thoracostomy alone in some cases. However, the treatment of pneumothorax in patients with ARDS undergoing mechanical ventilation may represent a clinical difficulty. If the air leak is permanent despite drainage, bleb resection and thoracoscopy with pleural scratch may be one therapeutic option [16-18]. Tube thoracostomy was performed in all cases in the present study.

There are various particular difficulties in the operative management of recurring pneumothoraces in patients recovering from COVID-19. Significant problems include health workers being exposed to aerosol-producing procedures, maintenance of single-lung ventilation, the risk of contralateral pneumothorax development, and the suitability for resection of the underlying lung tissue [16, 17].

Although the primary cause of death in COVID-19 infections is ARDS, the early diagnosis and treatment of severe complications such as pneumothorax, pneumomediastinum, or pulmonary embolism are also highly important [13]. The mortality rate in pneumothorax developing in association with SARS-CoV-2 infection is much higher than in previously reported SSP cases [1, 6]. Onuki et al. [1] reported a mortality rate of 4.59% in 327 cases of SSP. That rate was approximately 30 times higher compared to primary spontaneous pneumothoraces. Miró et al. [6] reported mortality



rates of 32.5%, 13.8%, and 1.6% in COVID-19 patients developing pneumothorax, COVID-19 patients without pneumothorax development, and non-COVID-19 pneumothorax cases, respectively. Rafiee et al. [7] reported a mortality rate of 30%. They identified male gender, advanced age, and pre-existing lung disease, particularly COPD, as risk factors. Martinelli et al. [17] reported a general survival rate of 63.1%. No difference was determined in 28-day survival between the genders, although 28-day survival was significantly higher in patients aged 70 or more than young individuals. The mortality rate due to spontaneous pneumothorax in the present study was 56.25%.

Some limitations need to be considered when interpreting the results of this study. First, due to the retrospective nature of the study, it is not easy to evaluate factors capable of affecting pneumothorax development. The second limitation is the relatively low case number. Another factor is that the effect of pneumothorax on mortality cannot be thoroughly evaluated since this was an observational study and due to multiorgan involvement.

## **Conclusion**

Pneumothorax is a potential complication of COVID-19 pneumonia. It can emerge during active COVID-19 infection or after the completion of treatment. It can worsen prognosis, particularly in patients with underlying lung disease, and the mortality rate is higher compared to other spontaneously developing pneumothoraces. The incidence of pneumothorax in COVID-19 cases is higher than that in the normal population, and diagnosis and treatment must not be delayed.

## **References**

1. Onuki, T., et al., Primary and secondary spontaneous pneumothorax: Prevalence, clinical features, and in-hospital mortality. *Canadian Respiratory Journal* 2017. 2017: 6014967
2. Türkyılmaz, A., et al., Treatment of secondary spontaneous pneumothorax: 100-patient experience. *Eurasian Journal of Medicine* 2007. 39: p. 97-102.
3. Elhakim, TS., et al., Spontaneous pneumomediastinum, pneumothorax and subcutaneous emphysema in covid-19 pneumonia: A rare case and literature review. *British Medical Journal Case Reports* 2020. 13: e239489.
4. Quincho-Lopez, A. , et al., Case report: pneumothorax and pneumomediastinum as uncommon complications of covid-19 pneumonia—literature review. *The American Journal of Tropical Medicine and Hygiene* 2020. 103: p. 1170–76.
5. Alhakeem, A., et al., Case report: Covid-19–associated bilateral spontaneous pneumothorax—a literature review. *The American Journal of Tropical Medicine and Hygiene* 2020. 103: p. 1162–65.

6. Miró, Ò. , et al., Frequency, risk factors, clinical characteristics, and outcomes of spontaneous pneumothorax in patients with coronavirus disease Chest 2021.159: p. 1241-1255.
7. Rafiee, MJ., et al., Spontaneous pneumothorax and pneumomediastinum as a rare complication of covid-19 pneumonia: Report of 6 cases. Radiology Case Reports 2021. 16: p. 687–92.
8. Akçay, Ş., T. Özlü, and A. Yılmaz., Radiological approaches to covid-19 pneumonia. Turkish Journal Of Medical Sciences 2020. 50: p. 604–10.
9. Salehi, S., et al., Coronavirus disease 2019 (COVID-19): A systematic review of imaging findings in 919 patients. American Journal of Roentgenology 2020. 215: p. 87–93.
10. Vahidirad, A. , et al., Tension pneumothorax in patient with covid-19 infection. Radiology Case Reports 2021. 16: p. 358–60.
11. Zantah, M., et al., Pneumothorax in Covid-19 disease- incidence and clinical characteristics. Respiratory Research 2020. 21: 236.
12. Al-Shokri, SD., et al., Case report: Covid-19–related pneumothorax—case series highlighting a significant complication. The American Journal of Tropical Medicine and Hygiene 2020.103: p. 1166–69.
13. Akdogan, RE., et al., Pneumothorax in mechanically ventilated patients with covid-19 infection. Case Reports in Critical Care 2021. 2021: 6657533.
14. Özdemir, S., et al., Pneumothorax in patients with coronavirus disease 2019 pneumonia with invasive mechanical ventilation. Interactive CardioVascular and Thoracic Surgery 2020. 19: p. 351–55.
15. Talan, L., et al., Covid-19 pneumonia and pneumothorax: Case series. Tuberk Toraks 2020. 68: p. 437–43.
16. Kasturi, S., et al., Delayed recurrent spontaneous pneumothorax post-recovery from covid-19 infection.” Indian Journal of Thoracic and Cardiovascular Surgery 2021. 37: p. 1–3.
17. Martinelli, AW., et al., COVID-19 and pneumothorax: a multicentre retrospective case series European Respiratory Journal 2020. 56: 2002697.
18. Aiolfi, A., et al., Management of persistent pneumothorax with thoracoscopy and bleb resection in covid-19 patients. The Annals of Thoracic Surgery 2020. 110: p.413-415.