

A different approach in primary spontaneous pneumothorax surgery: Lateral pleurectomy technique and results

Bariş Hekimoğlu¹  Muhammet Ali Beyoğlu² 

1 Ordu University Faculty of Medicine, Department of Thoracic Surgery, Ordu, Turkey

2 University of Health Sciences, Ankara City Hospital, Department Thoracic Surgery, Ankara, Turkey

Abstract

Background: Primary Spontaneous Pneumothorax is a disease with a frequent recurrence rate. The uniportal videothoracoscopic surgery approach is the standard treatment for air leak and recurrence prevention. In common practice, apical pleurectomy is used after apical wedge resection. Our study aims to examine the results, especially the recurrence rate, of the lateral pleurectomy and apical pleural abrasion combination technique applied as an alternative to this technique.

Methods: A total of 50 patients who underwent uniportal videothoracoscopic surgery for primary spontaneous pneumothorax between November 2018 and May 2021 were included in the study. The follow-up period for recurrence of the patients was 12-42 months. Age, gender, pneumothorax side, operation indication, Body Mass Index, smoking history, incision length and location, air leakage and tube thoracostomy duration, Verbal Numeric Pain Scores, post-operative length of hospital stay, complications, and recurrence data were recorded.

Results: Of the 50 patients, 44 (88%) were male, and 6 (12%) were female, with a mean age of 22.3±5.9 years. Surgery was performed from the existing drain site in 32 (64%) cases and the former drain scar in 11 (22%) cases. The mean duration of tube thoracostomy was 2.7±0.97 days, and the mean length of hospital stay was 3.6±0.89 days. Complications developed in 2 (4%) cases, and recurrence was observed in 2 (4%) cases.

Conclusions: Lateral pleurectomy with the apical pleural abrasion technique is easy to apply and reduces the possibility of undesired hemorrhagic drainage. We believe that the lateral pleurectomy technique is safe, easily applicable, and less risky in terms of hemorrhage.

Keywords: Lateral Pleurectomy, Primary Spontaneous Pneumothorax, Uniportal Surgery, VATS.

Cite this article as: Hekimoğlu B, Beyoğlu MA. A different approach in primary spontaneous pneumothorax surgery: Lateral pleurectomy technique and results. Arch Curr Med Res. 2022;3(3):174-180

Corresponding Author:

Bariş Hekimoğlu, Ordu University Faculty of Medicine, Department of Thoracic Surgery, Ordu, Turkey
E-Mail: drbarishekimglu@yahoo.com



Content of this journal is licensed under a Creative Commons Attribution-NonCommercial 4.0 International License.

INTRODUCTION

Primary Spontaneous Pneumothorax (PSP) is a disease primarily seen in young adults who are thin, tall, and without a history of underlying disease or trauma. It usually occurs due to spontaneous rupture of subpleural blebs or bullae located at the apex of the lung (1). While the incidence of PSP is 7.4-18/100.000 per year in young men, it has been reported as 1.2-6/100.000 in young women (2). Secondary Spontaneous Pneumothorax (SSP) differs from PSP in that it is caused by Chronic Obstructive Pulmonary Disease (COPD) or trauma (iatrogenic, injury, etc.). Being a smoker is a significant risk factor for PSP (3).

In the literature, the lowest recurrence rate after PSP surgery is still in the PSP operation performed with a thoracotomy incision (4). However, in recent years, uniportal Videothoroscopic Surgery (VATS) has become the standard treatment method in many clinics for PSP surgery, with less pain and surgical trauma, a shorter hospital stay, and a quicker return to routine life due to post-operative comfort (1, 5). Published uniportal VATS studies have described wedge resection and Apical Pleurectomy (AP) technique, primarily in the bullous area at the lung apex. It has become a widely accepted surgical procedure (3, 5, 6). Although similar recurrence rates were reported with total pleurectomy and apical pleural abrasion techniques, except for AP, in some studies, it was reported that apical pleurectomy is a more successful procedure in preventing recurrence (1, 5, 7). However, a substantial number of studies show that AP gives the same recurrence rates as apical pleural abrasion (7, 8). Moreover, advantages such as shorter operation time, less drainage, shorter hospital stay, and less pain were reported with the apical pleural abrasion technique than the AP technique in these studies (7-9).

Our study aims to analyze the results of Lateral Pleurectomy (LP) and apical pleural abrasion combination technique, which aims to investigate the advantages of AP and apical pleural abrasion techniques in uniportal VATS operation, on other parameters, especially on the recurrence rate.

MATERIALS AND METHODS

Study Design

This study was designed as a retrospective and observational study. The approval of the local ethics committee was obtained (Approval number: 2022/74). The authors confirmed compliance with the World Medical Association Declaration of Helsinki on the ethical conduct of research involving human subjects.

Fifty-five cases operated for PSP in a single center and by the same thoracic surgeon between November 2018 and May 2021 were included in the study retrospectively. Four of these cases were excluded from the study since relapse information for PSP could not be reached, and 1 case developed traumatic pneumothorax while doing sports on the operated side during the post-operative follow-up period. A total of 50 patients with a follow-up period of 12-42 months for pneumothorax recurrence were included in the study. Patients over 40 years of age and with SSP (COPD, emphysema, traumatic, etc.) were omitted.

Patient data were obtained from physical and digital archive files. Age, gender, pneumothorax side, operation indication, Body Mass Index (BMI), smoking history, incision length and location, air leakage and tube thoracostomy duration, pain scores, post-operative length of hospital stay (LOS), complications, and recurrence data were recorded. Recurrence information of the cases was obtained by physical and digital hospital files and telephone interviews.

Prolonged air leak (more than seven days), recurrence of PSP, and bilateral pneumothorax were the indication for PSP operation. The patients' pain was scored according to the Verbal Numeric Pain Scale (VNPS). VNPS is a verbal numerical scale in which patients are asked to verbally indicate a number between 0 and 10 corresponding to their current pain intensity. On this scale, zero corresponds to no pain, while ten corresponds to the greatest pain a person will ever experience. According to the VNPS score, 0 points were classified as no pain, 0-3 mild pain, 3-5 moderate pain, 5-7 severe, and 7-10 very severe.

Surgical Procedures

All patients were operated on with the same surgical procedure. After double-lumen intubation under general

anesthesia, operations were performed in the lateral decubitus position. Before performing the incision, a local anesthetic (2 mg/kg Bupivacaine) was used to block the area around the incision and lower and upper intercostal nerves. Although the incision sites differ in patients sent from external centers, a single incision line of approximately 2.5 cm in the anterolateral thorax, where the 7th-8th intercostal space intersects with the anterior axillary line, was preferred for tube thoracostomies and surgeries performed in our center. A 30-degree 10mm endoscopic camera, endoscopic grasper, endoscopic linear stapler, endoscopic nut, and energy device were used during the operation. When active air leakage was detected, wedge resection was performed with an endoscopic linear stapler (apex and the apical part of the lower lobe superior). Apical pleural abrasion and cauterization were performed with the help of endoscopic hazelnut and energy devices to the cupula and lateral pleural area in the upper part of the fourth intercostal space. The LP procedure was performed with blunt and sharp dissections with the help of endoscopic grasper, forceps, and dissectors in the 4th intercostal and below, extending to the 10th intercostal space, 3 cm from the descending aorta in the left hemithorax, and 3 cm from the esophageal bed in the right hemithorax. No pleurectomy was performed in the pleural area above the 4th intercostal space at the cupula or lower level (Figure 1). The removed lung wedge material and pleura were sent for pathological examination in separate containers. After a single 24-28 French (F) silicone drainage tube (underwater drainage system) was placed through the operation incision, the incision was closed by suturing the muscle layer with polyglactin suture material and by placing silk drain-retaining sutures on the skin. After all the cases were extubated in the operating room and followed up in the recovery room, the patients were taken to the inpatient service room in a stable and conscious-cooperative manner. The pain status of the patients was scored daily during hospitalization with VNPS, and an intercostal nerve block was performed with a local anesthetic drug and intravenous medical treatment for those with pain. Patients were mobilized, and balloon inflation exercises

were started in the 4th-6th hours post-operatively. Daily follow-up was done with a posteroanterior chest X-ray. The amount of tube thoracostomy drainage was noted daily, and the drain of the patients who did not have air leakage and whose drainage amount was 100 cc serous was terminated. Control chest X-ray was seen 6 hours after the drain was removed, and patients with expanded lung appearance were discharged. On the 10th day after discharge, a control chest X-ray was seen in the outpatient clinic, and the sutures were removed by the thoracic surgeon who performed the surgery. Information on long-term recurrence of the cases was obtained from the phone numbers or e-mail addresses registered in the hospital data system.

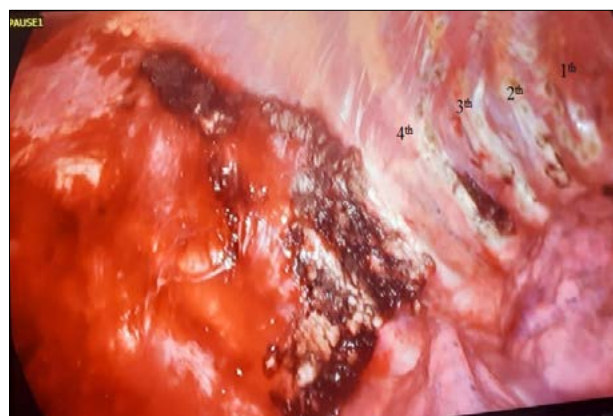


Figure 1. Picture of Lateral Pleurectomy (LP) and apical pleural abrasion combination technique obtained during uniportal VATS.

Statistical Method

Statistical analysis was performed using the "IBM SPSS Statistics for Windows. Version 22.0 (Statistical Package for the Social Sciences, IBM Corp., Armonk, NY, USA)" program. Descriptive statistics of the research: frequency and percentage for categorical variables, mean and standard deviations for numerical variables.

RESULTS

The baseline demographic characteristics of the patients are given in Table 1. Table 2 shows the patients' perioperative information.

Table 1. Baseline Sociodemographic Characteristics of Patients

	n (%) mean ±SD
Gender	
Female	6 (12)
Male	44 (88)
Age	22.3±5.9
Pneumothorax side	
Right	32 (64)
Left	18 (36)
Operation indication	
Prolonged air leakage	18 (36)
First recurrence	12 (24)
Second recurrence	8 (16)
Recurrence in the opposite side	6 (12)
Two-sided pneumothorax	5 (10)
Recurrence after surgery	1 (2)
Smoking History	
Yes	15 (30)
No	35 (70)

Complications were seen in 2 (4%) cases. One case with major complications was hypotension due to hemorrhagic drainage that developed at the post-operative 4th hour. When a single incision site was explored, hemorrhage originating from the intercostal artery was detected and bleeding was controlled from the same incision site, and he was discharged three days later. The other case was wound infection and healing was achieved with wound debridement and suturing (Table 2).

Table 2. Per-operative variables of the patients

	n (%) mean ±SD
Incision length (cm)	2.8±3.9
Incision location	
Current drain incision	32 (64)
Former drain scar	11 (22)
New incision	7 (14)
Air leakage duration (days)	2.96±4.1
Tube thoracostomy duration	2.7±0.97
Post-operative LOS	3.6±0.89
Complication	
No	48 (96)
Yes	2 (4)
Recurrence	
No	48 (96)
Yes	2 (4)
Pain Scores	
POD1	5±1.19
POD3	3.3±1.16
POD10	0.32±0.65

Note: LOS: Length of hospital stay, POD1: post-operative day 1, POD2: post-operative day 2, POD 3: post-operative day 3.

The patients' pain scores on the 1st, 3rd, and 10th days post-operative according to VNPS are given in Table 2. On the first post-operative day, three patients (6%) described the pain as mild, 33 patients (66%) moderate pain and 14 patients (28%) very severe pain. On the third post-operative day, 32 patients (64%) described mild pain, 15 patients (30%) moderate, and two patients (4%) very severe pain. On the tenth post-operative day, 39 patients (78%) reported no pain, while 11 patients (22%) reported mild pain.

The cases were followed between 12 and 42 months after surgery for recurrence. Recurrence developed in only two patients (4%). One patient was addicted to inhaler drugs (cocaine-marijuana addict) and stated that he continued to use it extensively after discharge. He presented with recurrent pneumothorax only at the apex one month after the operation. He was discharged with an expanded lung after three days of follow-up with closed underwater drainage with a catheter thoracostomy (8 F). No recurrence was observed in the 3-year follow-up of the patient who stopped using drugs. The other case was admitted with recurrent pneumothorax in the 6th month post-operatively. The patient, who underwent a re-uniportal VATS procedure with apical wedge resection and total pleurectomy, was discharged without complications after four days of inpatient follow-up. During the recurrent pneumothorax operation, it was observed that the air leak was from the former stapler line, and wedge resection was performed by placing a new stapler under the stapler line. To prevent a recurrence, a pleurectomy was completed to total pleurectomy. The patient, diagnosed with granulomatous inflammation in favor of tuberculosis due to post-operative pleural pathology, Long-term (9 months) anti-tuberculosis treatment was applied to the patient, whose pathology result of his second operation showed granulomatous inflammation compatible with tuberculosis. No recurrence of pneumothorax was observed in the next two years. Furthermore, no evidence of secondary spontaneous pneumothorax was found in the patient's anamnesis or CT findings before the first operation.

DISCUSSION

The primary purpose of operations for PSP is to prevent air leakage and recurrence. There are many studies on the results of operations performed with standard posterolateral thoracotomy, axillary thoracotomy, tri-

portal VATS, and currently uniportal VATS procedure. Although the current uniportal VATS procedures successfully reduce the recurrence rate, it is still known that the thoracotomy procedure has the most successful rate in preventing recurrence (4, 9). However, the significant success of uniportal VATS in terms of minimal incision scar, post-operative pain advantage, drainage, LOS, and early return to routine life has made it the standard PSP surgical procedure today (10-12). This study was conducted to present the advantages of using uniportal VATS and lateral pleurectomy technique as an alternative to apical pleurectomy, which is used in many centers for PSP, in the light of case results.

Less pain and drainage, shorter tube residence time and LOS time, and better cosmetic results detected in studies showing the superiority of the uniportal approach compared to the tri-portal VATS approach in the literature were also confirmed in our study (11-13). The incision size reported in these large-series studies is similar to the mean length of 2.8 cm we found in our study (11-13). In addition, it was observed that the reported 2-5% post-operative complication rates were similar to those in our study (1, 11-15). Finding similar results in the LP procedure with Uniportal VATS as in the AP procedure indicates that it is a safe method that can be applied more easily and in a shorter time as a surgical technique. In addition, performing a pleurectomy over the internal mammarian artery and subclavian artery in AP carries the risk of severe intra-operative and post-operative hemorrhage. With LP, it is possible to avoid this risk.

Pain from parietal pleural origin due to pleurectomy is an inevitable outcome in the post-operative period. As there are many other ways to reduce pain, the intercostal nerve blocking method that the surgeon can perform, unfortunately, seems difficult or even impossible to apply in the AP technique in the high-level ribs and cupula region. However, in the combination technique of LP and apical pleural abrasion, the incision's lower and upper intercostal spaces and the 4-10th intercostal spaces can be easily reached, and intercostal nerve blockade can be applied at multiple levels. Thus, pain caused by post-operative pleurectomy in the LP technique is prevented locally and effectively. However, we would like to point out that this issue should be investigated with future studies involving large case series on this subject.

As Caecilia et al. (1) mentioned in their study, avoidance of pleurectomy in the internal mammarian artery-vein (IMA/IMV) and subclavian artery and vein areas in AP is an essential issue in preventing the possible complication of massive hemorrhage in AP. Although it is mentioned in some studies that AP with Uniportal VATS that AP completely covers the IMA/IMV and subclavian artery and vein areas, we think that it is a difficult pleurectomy procedure in practice (7, 14). The risk of undesired massive hemorrhage in the IMA/IMV and subclavian artery and vein areas with the LP and apical pleural abrasion technique is relatively low, and it is technically easier to apply. We believe that the recurrence rate in PSP surgery will be similar to that in the AP technique, with the surgeon's easier-to-apply LP technique. However, we would like to point out that comparative studies involving larger series are needed on this subject.

Uniportal VATS LP procedure was performed from the existing drain site in 32 (64%) cases and the old drain scar in 11 (22%) cases. This result shows us that the LP technique can also be applied from the existing or old drain site. The fact that no new incisions are made in patients indicates that the LP technique is compatible with achieving better cosmetic results, which is one of the goals of uniportal VATS surgery.

In meta-analysis studies published in the literature, it has been frequently mentioned that PSP patients are tall and thin people with typical physical features and smoking habits (4, 6, 14, 15). In our study, the mean BMI was 19.8 kg/m², and 35 (70%) of the cases were smokers. These findings are compatible with classical literature knowledge.

Many studies have been published to reveal which method is better between AP and apical pleural abrasion for decreasing recurrence rates after PSP surgery. Although studies show that the effects of abrasion and pleurectomy on recurrence are close, meta-analysis studies have reported that AP has a statistically lower recurrence rate than abrasion (6, 13-15). Our study showed recurrence in 2 (4%) patients who underwent LP with uniportal VATS surgery. One of these patients relapsed during the post-operative continuation of heavy inhaler drug use. The patient did not give any information about inhaler drug use before the first operation. He shared information about

substance use after recurrence development. In addition, with the LP applied in the first surgery, the recurrence was limited only to the apical region. It was treated with a minimally invasive intervention such as a catheter thoracostomy. Similarly, in the literature, recurrence of PSP due to inhaler drug use has also been reported in cases who underwent the AP procedure (16, 17). In the second operation of the other relapsed patient, tuberculosis was found due to pleural pathological evaluation. It is pleasing that this patient did not experience complications secondary to advanced tuberculosis, such as empyema and non-expanded lung. The recurrence in this patient is thought to be related to parenchymal tuberculosis rather than the LP procedure. Before the first operation, there was no anamnesis, physical examination, or CT findings in this patient to suggest tuberculosis as a secondary cause of spontaneous pneumothorax. However, detection of leakage from the stapler line during the operation could be due to inadequacy of the surgical technique or tuberculosis. The follow-up time of our cases is 12-42 months, and 5- and 10-year follow-up results should have waited for precise results regarding recurrence. However, it was observed that the current recurrence rates were similar to the procedure performed with AP (1, 5, 7, 8, 18).

Limitations

The main limitations of our study are that the follow-up period has not yet reached at least five years, the number of patients is low, and the absence of a control group. We think that these limiting factors can be eliminated by presenting further studies with five and 10-year follow-up results in terms of PSP recurrence.

As a result, the AP or apical pleural abrasion technique applied with bulla or bleb excision with uniportal VATS, which is the current surgical approach of PSP, has become a standard procedure in many centers. AP is a relatively difficult and long-lasting surgical procedure with an increased risk of hemorrhage. The LP and apical pleural abrasion techniques we applied in our study both ease the application and reduce the risk of hemorrhagic drainage. We think the LP technique is safe, easily applicable, and less risky in terms of per-operative hemorrhage.

Declarations

The authors received no financial support for this article's research and/or authorship. There is no conflict of interest.

This study was approved by the clinical research ethics committee of the Ordu University (Date:25.03.2022, Approval Number: 2022/74)

Abbreviations

AP: Apical Pleurectomy

BMI: Body-Mass Index

COPD: Chronic Obstructive Pulmonary Disease

F: French

LOS: Length of Hospital Stay

LP: Lateral Pleurectomy

PSP: Primary Spontaneous Pneumothorax

SSP: Secondary Spontaneous Pneumothorax

VATS: Videothoroscopic Thoracic Surgery

VNPS: Verbal Numeric Pain Scala

REFERENCES

1. Caecilia NG, Maier HT, Kocher F, Jud S, Lucciarini P, Ofner D, et al. VATS Partial Pleurectomy Versus VATS Pleural Abrasion: Significant Reduction in Pneumothorax Recurrence Rates After Pleurectomy. *World J Surg.* 2018;42(10):3256-62.
2. Hallifax RJ, Goldacre R, Landray MJ, Rahman NM, Goldacre MJ. Trends in the Incidence and Recurrence of Inpatient-Treated Spontaneous Pneumothorax, 1968-2016. *JAMA.* 2018;320(14):1471-80.
3. Savitsky E, Oh SS, Lee JM. The Evolving Epidemiology and Management of Spontaneous Pneumothorax. *JAMA.* 2018;320(14):1441-43.
4. MacDuff A, Arnold A, Harvey J; BTS Pleural Disease Guideline Group. Management of spontaneous pneumothorax: British Thoracic Society Pleural Disease Guideline 2010. *Thorax.* 2010;2:18-31.
5. Kopicibasi HO. Uniportal VATS technique for primary spontaneous pneumothorax: An analysis of 46 cases. *Pak J Med Sci.* 2020;36(2):224-8.
6. Vuong NL, Elshafay A, Thao LP, Abdalla AR, Mohyeldin IA, Elsabaa K, et al. Efficacy of treatments in primary spontaneous pneumothorax: A systematic review and network meta-analysis of randomized clinical trials. *Respir Med.* 2018;152-66.
7. Ocakcioglu I, Kupeli M. Surgical Treatment of Spontaneous Pneumothorax: Pleural Abrasion or Pleurectomy? *Surg Laparosc Endosc Percutan Tech.* 2019;29(1):58-63.
8. Patterson KN, Lawrence AE, Beyene TJ, Aldrink JH, Michalsky M, Minneci PC. Recurrence Rates After Video-Assisted Thoracoscopic Surgery for Spontaneous Pneumothorax. *J Laparoendosc Adv Surg Tech A.* 2021;31(12):1424-30.
9. Dadas E, Ozkan B, Sabuncu T, Tanju S, Toker A, Dilege S. Video-Assisted Thoracoscopic Pleurectomy in Spontaneous Pneumothorax Surgery. *Turk Thorac J.* 2015;16(1):22-7.
10. Xu W, Wang Y, Song J, Mo L, Jiang T. One-port video-assisted thoracic surgery versus three-port video-assisted thoracic surgery for primary spontaneous pneumothorax: a meta-analysis. *Surg Endosc.* 2017;31(1):17-24.

11. Qin SL, Huang JB, Yang YL, Xian L. Uniportal versus three-port video-assisted thoracoscopic surgery for spontaneous pneumothorax: a meta-analysis. *J Thorac Dis.* 2015;7(12):2274-87.
12. Yang Y, Dong J, Huang Y. Single-incision versus conventional three-port video-assisted surgery in the treatment of pneumothorax: a systematic review and meta-analysis. *Interact Cardiovasc Thorac Surg.* 2016;23(5):722-8.
13. Masmoudi H, Etienne H, Sylvestre R, Evrard D, Ouede R, Le Roux M, et al. Three Hundred Fifty-One Patients With Pneumothorax Undergoing Uniportal (Single Port) Video-Assisted Thoracic Surgery. *Ann Thorac Surg.* 2017;104(1):254-60.
14. Huh U, Kim YD, Cho JS, IH, Lee JG, Lee JH. The Effect of Thoracoscopic Pleurodesis in Primary Spontaneous Pneumothorax: Apical Parietal Pleurectomy versus Pleural Abrasion. *Korean J Thorac Cardiovasc Surg.* 2012;45(5):316-9.
15. Lin Z, Zhang Z, Wang Q, Li J, Peng W, Ge G. A systematic review and meta-analysis of video-assisted thoracoscopic surgery treating spontaneous pneumothorax. *J Thorac Dis.* 2021;13(5):3093-104.
16. Ciriaco P, Rossetti F, Carretta A, Sant'Angelo M, Arrigoni G, Negri G. Spontaneous pneumothorax in cocaine users. *QJM.* 2019;112(7):519-22.
17. Wakefield CJ, Seder CW, Arndt AT, Geissen N, Liptay MJ, Karush JM. Cannabis Use Is Associated With Recurrence After Primary Spontaneous Pneumothorax. *Front Surg.* 2021;8:668588.
18. Bertolaccini L, Pardolesi A, Brandolini J, Solli P. Uniportal video-assisted thoracic surgery for pneumothorax and blebs/bullae. *J Vis Surg.* 2017;3:107.

Note: Our study, which consists of the majority of the patients in this study, was presented as an oral presentation at the 11th National Thoracic Surgery Congress held in Antalya on 24-27 October 2021.