

Posterior Segment Optical Coherence Tomography Findings in Patients with COVID-19

COVID -19 Hastalarında Arka Segment Optik Koherens Tomografi Bulguları

Alev Kockar¹, Hayati Yılmaz², Betül İlkay Sezgin Akcay¹, Erdal Yuzbasioglu³

¹University of Health Science Umraniye Training and Research Hospital, Department of Ophthalmology, Istanbul, Türkiye

²Hitit University, Department of Ophthalmology, Corum, Türkiye

³Demiroğlu Bilim University Faculty of Medicine, Department of Ophthalmology, Istanbul, Türkiye

Geliş Tarihi/Received: 31.05.2022

Kabul Tarihi/Accepted: 03.07.2022

Yazışma Adresi/Address for

Correspondence:

Hayati Yılmaz

Hitit Üniversitesi Tıp Fakültesi Göz Hastalıkları

Anabilimdalı, Merkez/Çorum

E-posta: dr.hyilmaz@hotmail.com

Anahtar Sözcükler

COVID-19

Maküler kalınlık

Optik koherens tomografi

Retina

Retina sinir lifi tabakası

Keywords

COVID-19

Macular thickness

Optical coherence tomography

Retina

Retinal nerve fiber layer

Orcid No



AK¹ :0000-0002-1457-8511

HY² :0000-0001-5051-5713

BISA⁴ :0000-0003-1932-7671

EY³ :0000-0003-1008-4511

Abstract

Objective: COVID-19 which is still the leading health problem in the world, is not yet fully understood, therefore the study aims to investigate the posterior segment of the eye in patients with COVID-19 using optical coherence tomography.

Material and Method: The present study was designed prospective and cross-sectional. Patients with a positive test result of COVID-19 and healthy controls who were older than 18 years were included in the study. Excluded from the study were the patients with any systemic comorbidity and ocular disease. The demographic and clinical data, including ocular findings and the optical coherence tomography data, including hyper-reflective lesions, retinal nerve fiber layer, ganglion cell complex, and macular thicknesses were recorded as outcomes and analyzed.

Results: Twenty patients with SARS-CoV-2 and 20 healthy subjects were included in this study. There was no difference between COVID-19 patients and healthy controls in terms of the retinal nerve fiber layer, ganglion cell complex, and macular thicknesses ($p>0,05$). Hyper-reflective lesions were detected in 18(45%) eyes of 9(45%) patients with COVID - 19 and 15(37,5%) eyes of 8(40%) healthy subjects' retina with no significant difference between groups ($p = 0,165$).

Conclusion: Hyper-reflective lesions could only be retinal vessels' tangential cuts seen in optical coherence tomography B-Scans. There was not enough data that could indicate posterior segment involvement of COVID-19.

Öz

Amaç: Kliniği tam olarak anlayamamış olan COVID-19, hala dünyanın önde gelen sağlık problemi olmaya devam etmektedir. Bu nedenle bu çalışmada optik koherens tomografi kullanılarak COVID-19 hastalarının gözlerinin arka segmentini araştırmayı amaçladık.

Gereç ve Yöntem: Çalışma prospektif ve kesitsel olarak tasarlanmıştır. On sekiz yaşından büyük COVID - 19 test sonucu pozitif olan hastalar ve sağlıklı kontroller çalışmaya dahil edilmiştir. Göz ya da sistemik komorbiditesi olan hastalar çalışma dışı bırakılmıştır. Göz muayene bulguları, hiper-reflektif lezyonlar, retina sinir lifi tabakası, ganglion hücre kompleksi ve maküler kalınlıkları olmak üzere optik koherens tomografi verilerini de içeren demografik ve klinik veriler kayıt edilmiş ve sonuçlar analiz edilmiştir.

Bulgular: Yirmi COVID-19 hastası ve 20 sağlıklı gönüllü çalışmaya dahil edilmiştir. Sağlıklı gönüllüler ile hastalar arasında retina sinir lifi tabakası, ganglion hücre kompleksi ve maküler kalınlıklar açısından anlamlı fark görülmemiştir ($p>0,05$). Hiper-reflektif lezyonlar 9 (%45) hastanın 18 (%45) gözünde ve 8 (%40) sağlıklı gönüllünün 15 (%37,5) gözünün retinalarında tespit edildi. Hiper-reflektif lezyon varlığı açısından gruplar arasında anlamlı bir fark tespit edilmemiştir ($p = 0,165$).

Sonuç: Hiper-reflektif lezyonlar yalnızca retinal damarların optik koherens tomografi B taramalarında izlenen tanjansiyal kesiti olabilir. COVID-19'un gözün arka segmentini etkileyebileceğini gösteren yeterli veri elde edilememiştir.

INTRODUCTION

Coronavirus disease (COVID-19), first reported in December 2019 in Wuhan, China, has been spreading worldwide since then. The pathogen causing this disease is a non-segmented positive-sense RNA virus called severe acute respiratory syndrome coronavirus-2 (SARS CoV-2), which has a similar binding receptor (angiotensin-converting enzyme - 2) and similar pathologic features and epidemiological characteristics with SARS CoV (1,2). It is believed that Coronaviridae are not always confined to the respiratory tract, and neurological signs, such as headache, nausea, and vomiting suggest the CNS involvement of these viruses (3,4) Although it is very well known that SARS CoV mainly affects the respiratory system, a few studies have underlined the eye as a potential site for replication and transmission (5,6).

Recently, Marinho et al.(7) released a new report showing hyper-reflective (HR) lesions at the level of ganglion cells and inner plexiform layers of the papillomacular bundle using spectral domain-optical coherence tomography (SD-OCT) in 12 healthcare professionals with COVID - 19. However this study had several major limitations. One of the most important limitations was that the study had no controls. There are also case reports which indicate that posterior segment manifestations could be seen in COVID - 19 patients' eyes (8,9). In this study, we aimed primarily to investigate the posterior segment of the eyes in patients with COVID - 19 using SD-OCT and secondly, show these HR lesions if there are any and search for associations between the presence of these lesions and the thicknesses of the retinal nerve fiber layer (RNFL), ganglion cell complex (GCC) and macula.

MATERIAL and METHODS

Demographic and clinical data

The study design was prospective and cross-sectional. Twenty healthy subjects and 26 COVID-19 patients with mild to moderate severity of pneumonia who were hospitalized between 1st to 30th April 2020 for diagnosis and treatment were included in this study. The demographic features, including age and gender, and clinical features, including symptoms, the severity of pneumonia according to the Turkish Ministry of Health, Scientific Committee, Guidelines for COVID-19 (10), elapsed time since the first symptom occurred, elapsed time since hospitalization, the time from the first symptom to hospitalization, and the treatment applied was recorded for each case. All participants underwent a complete ophthalmological examination, including best-corrected visual acuity (BCVA) with a Snellen chart, intraocular pressure measurement with a non-contact air-puff tonometer, slit-lamp biomicroscopy examination, and dilated funduscopy along with SD-OCT (RTVue-100 OCT, Optovue Inc, Fremont, CA) scanning.

The study included patients older than 18 years. Patients with a positive test result of COVID-19 according to the real-time reverse transcriptase-polymerase chain reaction (rRT-PCR, using nasal or oral swabs) test were included in the COVID - 19 patients group. Excluded from the study were

patients with severe COVID-19, those with systemic comorbidities (diabetes mellitus, hypertension, chronic obstructive lung diseases, such as asthma, connective tissue disorders, and autoimmune diseases), and those with ocular diseases (any ocular surgery history, spherical equivalent $> \pm 3$ D, corneal astigmatism $> \pm 3$ D, cataract, corneal diseases, glaucoma, retinal diseases, such as retinal vascular obstruction and age-related macular degeneration).

SD-OCT scanning

An RTVue-100 OCT device (Optovue Inc, Fremont, CA) was used for scanning. The RNFLT, MRT, and GCCT of both eyes of the study participants were evaluated. The RNFLT map was measured along a circle of 3.45 mm in diameter centered on the optic disc. A 3D disc protocol was used to register the edge of the optic nerve head. The global (average) RNFL thickness, the RNFL thickness of the superior and inferior hemifields, and the temporal, superior, nasal, and inferior quadrants were recorded for the analyses. The GCC protocol explored parameters within a circle of 6 mm diameter with the center of the GCC scan being shifted approximately 1 mm temporal to the fovea to improve the sampling of temporal peripheral nerve fibers. The GCC thickness of the superior and inferior hemifields and the global (average) GCC thickness were recorded from these scans. The macular thicknesses of the same fields as GCC were also obtained from the same scans. The enhanced deep imaging mode of SD-OCT was used to evaluate the macula and papillomacular bundle for the HR lesions which are described as HR foci or plaque seen in the papillomacular bundle at the level of ganglion cell and inner plexiform layers.(7)

Statistical analyses

The Statistical Package for the Social Sciences v. 21 (SPSS, Inc., Chicago, IL, USA) was used for statistical analysis. Quantitative variables were defined as mean and standard deviation (SD) and qualitative variables as percentages. Power calculation was not required due to the exploratory nature of the study. The Shapiro-Wilk test was used to determine whether the sample came from a normally distributed population. The Pearson chi-square test was used to analyze the gender and symptom distribution among the groups and the presence of HR lesions. According to the normality test results, the Mann-Whitney U test or Student's t-test was used to compare the age between COVID - 19 patients and controls. All the eye-related parameters were compared using generalized estimating equations (GEE). For each parameter [RNFL, GCC and macular thicknesses, and intraocular pressure (IOP)], a single age- and gender-corrected GEE model with the correlation matrix "independent" was created. In these models, eye-related parameters were chosen as the dependent variables, gender and grouping as factors, and age as the covariant. At the end of this process, the main effects of grouping on eye-related models were calculated. The GEE results were given with the correlation coefficient (B), 95% Wald confidence interval (CI), and P value. A P value less than 0.05 was considered statistically significant.

Ethical approval

This study was carried out under the principles of the Declaration of Helsinki after obtaining the permission of the Turkish Ministry of Health and the approval of the Clinical Research

Ethics Committee of Umraniye Training and Research Hospital, Istanbul, Turkey (Approval number: B.10.1.THK.4.34.H.GP.01/205). Written informed consent was obtained from each patient.

RESULTS

Demographic and clinical data

Six patients were excluded from the study due to having a history of intraocular surgery (n = 2), diabetes mellitus (n = 1), or arterial hypertension (n = 3); thus, the analyses were conducted in the remaining 40 participants. HR lesions were found in 18 eyes of 9 patients (45%) and 15 eyes of 8 healthy subjects (40%) (Figure 1). According to the presence of HR lesions, two groups were similar (P = 0.165). The two groups had a similar distribution in terms of age and gender (P = 0.214 and 0.572, respectively). Sixteen patients were hospitalized due to mild pneumonia and 4 due to moderate pneumonia. At the time of presentation to the hospital, the patients' symptoms were fever (n = 13, 65%), cough (n = 12, 60%), dyspnea (n = 7, 35%), muscle soreness and fatigue (n = 4, 20%), headache (n = 5, 25%), nausea (1, 5%), diarrhea (n = 1, 5%), and anosmia (n = 4, 20%). The demographic and clinical features of the participants are given in Table 1.

Figure 1. The samples of HR lesions which were detected using optical coherence tomography of the macula. White arrowheads; HR dots, red arrowheads; HR plaques. HR: hyper-reflective.

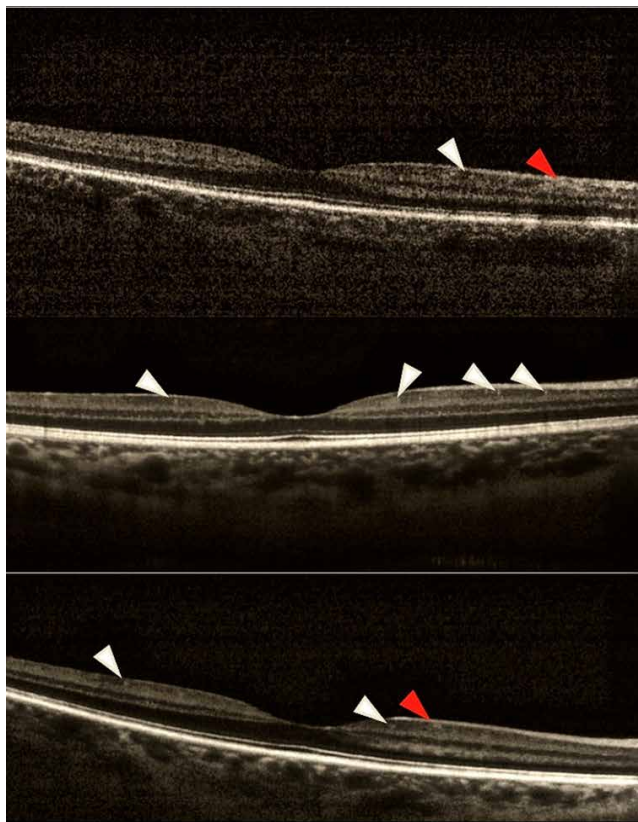


Table I. Demographic and clinical features of the participants

	COVID - 19 Patients, n = 20	Healthy Controls, n = 20	P
Age (years ± SD)	42.55 ± 11.50	41.12 ± 14.06	0.214*
Female (n/%)	7/35.0	8/40.0	0.572**
Time since the first symptom (day/range)	7.18/3-18	n/a	n/a
Time since hospitalization (day/range)	4.39/1-15	n/a	n/a
Time from symptom onset to hospitalization (day/range)	2.84/0-7	n/a	n/a
Pneumonia, mild (n/%) - moderate (n/%)	16/80.0 - 4/20.0	n/a	n/a
IOP (mmHg ± SD)	13.7 ± 3.15	14.2 ± 3.21	0.426***
BCVA (LogMAR ± SD)	0.00 ± 0.0	0.00 ± 0.0	n/a
Presence of HR lesions (eyes/%)	18/45.0	15/37.5	0.165**

SD; standard deviation, IOP; intra-ocular pressure, BCVA; best-corrected visual acuity, HR; hyper-reflective. *Mann-Whitney U test, **Pearson's chi-square test, ***Generalized estimation equations.

The groups showed no significant difference in terms of IOP (P = 0.426). The mean LogMAR-converted BCVA was 0.00 for both groups. No conjunctivitis or anterior segment involvement was seen in any patient. With the dilated fundus examinations, no sign of retinal involvement was presented in any patient and healthy subject.

Analyses of SD-OCT scans; RNFL

The RNFL thickness values of the participants and the results of GEE analyses are given in Table 2. RNFL of all quadrants, independent of age and gender, were not significantly differed between patients and healthy subjects. (P > 0.05 for all quadrants)

Table II. RNFL thickness values of the participants and the results of GEE analyses

	COVID-19 Patients, n = 20, 40 eyes	Healthy Controls, n = 20, 40 eyes	B	95% Wald CI	P
RNFL, global (µm ± SD)	102.91 ± 12.82	101.42 ± 9.19	1.465	-1.302 / 3.720	0.314
RNFL, sup. h. (µm ± SD)	104.45 ± 15.57	99.00 ± 9.13	6.409	-0.440 / 7.258	0.081
RNFL, inf. h. (µm ± SD)	101.57 ± 11.36	97.87 ± 11.49	3.833	-2.306 / 5.360	0.251
RNFL, temporal (µm ± SD)	80.13 ± 16.61	77.17 ± 14.48	2.061	-4.838 / 7.959	0.316
RNFL, sup. (µm ± SD)	126.18 ± 21.96	120.01 ± 12.82	4.182	-2.382 / 8.745	0.206
RNFL, nasal (µm ± SD)	76.14 ± 11.92	73.56 ± 13.86	2.581	-1.400 / 5.761	0.221
RNFL, inf. (µm ± SD)	129.32 ± 14.20	125.78 ± 17.70	3.540	-3.235 / 9.845	0.215

RNFL; retinal nerve fiber layer, GEE; generalized estimating equations, B; coefficient, CI; confidence interval, sup; superior, h; hemisphere, inf; inferior. Significant P values are shown in bold.

Analyses of SD-OCT scans; Macula and GCC

The macular and GCC thickness values of the participants and the results of GEE analyses are given in Table 3. There was no significant difference in terms of the global macular thickness of that of the superior and inferior hemifields ($P = 0.861, 0.720, \text{ and } 0.369$, respectively). Although the GCC of the patients with COVID - 19 was thicker than healthy subjects, the differences were not significant ($P = 0.303, 0.218, \text{ and } 0.265$, respectively).

Table III. Macular and GCC thickness values of the participants and the results of GEE analyses

	COVID-19 Patients, n = 20, 40 eyes	Healthy Controls, n = 20, 40 eyes	B	95% Wald CI	P
Macula, global ($\mu\text{m} \pm \text{SD}$)	263.34 \pm 11.62	264.22 \pm 12.43	-0.874	-10.663 / 8.915	0.861
Macula, sup. h ($\mu\text{m} \pm \text{SD}$)	266.57 \pm 14.49	264.55 \pm 12.38	2.019	-9.028 / 13.065	0.720
Macula, inf. h ($\mu\text{m} \pm \text{SD}$)	259.71 \pm 11.24	263.93 \pm 13.72	-4.223	-18.973 / 5.527	0.396
GCC, global ($\mu\text{m} \pm \text{SD}$)	97.52 \pm 8.03	94.83 \pm 6.01	2.690	-2.721 / 8.101	0.303
GCC, sup. h ($\mu\text{m} \pm \text{SD}$)	97.56 \pm 9.92	93.61 \pm 4.83	3.941	-2.331 / 10.213	0.218
GCC, inf. h ($\mu\text{m} \pm \text{SD}$)	97.52 \pm 8.18	96.81 \pm 8.89	0.712	-2.440 / 8.863	0.265

GCC; ganglion cell complex, GEE; generalized estimating equations, B; coefficient, CI; confidence interval, sup; superior, h; hemisphere, inf; inferior.

DISCUSSION

In the present study, we investigated COVID-19 patients with mild to moderate pneumonia and healthy subjects for HR lesions, which Marinho et al.(7) described. Twenty of 26 patients and 20 healthy subjects met the inclusion criteria. We detected HR lesions in 18 eyes of 9 patients and 15 eyes of 8 healthy subjects. There was no significant difference between the COVID - 19 patients and healthy individuals. These results suggest that the HR lesions which were presented in the papillomacular bundle could only be retinal vessels' tangentially cut on OCT B-scans. In our study, we also found no significant differences between healthy and COVID - 19 patients in terms of the thicknesses of RNFL, GCC, and macula. Although it is almost impossible to draw definite conclusions because of such a small sample size, we believe that the retinal involvement is not likely in COVID-19.

The Coronaviridae family of viruses consists of enveloped viruses with a large plus-strand RNA genome (27 - 32 kb) that is polyadenylated and capped. COVID-19 is not the only coronavirus-associated disease. There were seven coronaviruses types known before SARS-CoV-2, which could infect humans: 229E (alphacoronavirus), NL63 (alphacoronavirus), OC43 (betacoronavirus), HKU1 (betacoronavirus), SARS-CoV (betacoronavirus) and middle eastern respiratory syndrome-CoV (MERS-CoV, betacoronavirus)(11). Among these, SARS-CoV and MERS-CoV are known to cause critical respiratory failure (6,12). Additionally, it is now acknowledged that SARS-CoV-2 is a life-threatening cause of pneumonia with the

common features of the binding receptor and pathological and epidemiological findings (1,13,14). Although COVID-19 is mainly a disease of the respiratory system, enteric involvement, neurologic and ocular manifestations of SARS-CoV-2 have also been shown (5,15,16). Conjunctivitis with hyperemia, chemosis, and epiphora have been seen in up to 30% of COVID-19 patients (5,13). COVID - 19 induced bilateral optic neuropathy and COVID - 19 associated retinopathy are also described in the literature (8,9). In the light of this knowledge, we investigated the posterior segment involvement of the COVID - 19.

Recently, Marinho et al. presented a report that revealed HR lesions in the retina of 12 COVID-19 patients, especially in the papillomacular bundle and at the level of ganglion cells and inner plexiform layers. This report was the first to show the posterior segment/retinal involvement of SARS-CoV-2. Four of the patients in that report also had subtle cotton wool spots and microhemorrhages along the retinal arcade. All the patients had the symptoms of fever, asthenia, and dyspnea, and 11 also presented with anosmia. The main limitation of this study is that no comparison was made with the control group. Marinho et al. assumed that the presence of these HR lesions were proof of the retinal or a reflection of central nervous system (CNS) involvement, however, it is impossible to support these assumptions without a control group. In the current study including 20 cases, nine patients had similar HR lesions, however the same lesions were seen in 8 healthy individuals. Therefore, we agree with the various criticisms that have been made of the work of Marinho et al. (17-21) In addition to the report of Marinho et al., we also searched for associations of the OCT data including RNFL, GCC, and macular thicknesses with COVID-19. However, we found no significant differences in any of these parameters. Gündoğan et al.(22) also investigated the posterior segment involvement of the COVID-19 and concluded the same with our study. However, Pereira et al.(23) reported cotton wool spots and flame-shaped hemorrhages on the retina of the COVID-19 patients. They investigated the posterior segments of the hospitalized severe patients and this could be the reason for the inconsistency.

It is believed that SARS-CoV and MERS-CoV are not always confined to the respiratory tract, and neurological signs, such as headache, nausea, and vomiting suggest the CNS involvement of these viruses (3,4). Furthermore, the neurological invasion of SARS-CoV has been shown in both patients and experimental animals (24-26). The high similarity between SARS-CoV and SARS-CoV-2 leads to the idea that the same neurological concerns may be valid for SARS-CoV-2, thus playing a role in the respiratory failure of COVID-19 patients (27). Lastly, Moriguchi et al (28). reported the first case of meningitis and encephalitis associated with SARS-CoV-2. There are also some animal coronaviruses, such as mouse hepatitis virus (MHV) with both neurological and ocular manifestations. MHV is used for the creation of virally induced optic neuritis and retinal degeneration models (29-31). MHV has also been believed to be one of the etiological factors of multiple sclerosis (29). In the light of these investigations and reports, we can hypothesize that possible neurological findings may have reflections on the posterior segment of the eye, such as the

swelling of the optic nerve head and RNFL. In our investigations, with such a small sample size, we found no signs of retinal or CNS involvement. Further experimental studies are needed to verify or reject this hypothesis.

The small sample size is the main limitation of this study, which did not allow us to analyze the effect of treatment strategies on the retina. Secondly, due to the study's cross-sectional design, it is almost impossible to draw definite conclusions. Another limitation was we could not use any additional imaging techniques due to pandemic reasons such as color fundus photography or fluorescein angiography which could give us more information about the posterior segment. And lastly, we also did not search for the associations with serum inflammation biomarkers which could give us more information about the disease severity.

CONCLUSION

In conclusion, the hyper-reflective lesions which were seen in the OCT images could only be retinal vessels tangential cuts seen in OCT B-Scans. On the other hand, COVID-19 is caused by a virus that is not yet fully understood. Including our study, there are not enough data to assume that the SARS-CoV-2 could affect the posterior segment of the eye, therefore, physicians should be aware of neurological and ocular manifestations of this disease. Future follow-up and experimental studies are needed to provide an understanding of the true nature of this disease.

Authorship Contribution: Idea/Hypothesis: AK, HY, BISA, EY
Design: AK, HY, EY
Data collection/Data processing: AK, HY, BISA
Data Analysis: AK, BISA
Preparation of the article: AK, HY

Ethics Committee Approval: This research was approved by the Ethics Committee of Umraniye Training and Research Hospital, in accordance with the Research and Publication Ethics, with the decision of the board numbered B.10.1.THK.4.34.H.GP.0.01/205.

Informed Consent: Consents were obtained from the patients.

Peer Review: Evaluated by independent reviewers working in two different institutions appointed by the field editor.

Conflict of Interest: No conflict of interest was declared by the authors.

Financial Disclosure: No financial support.

REFERENCES

1. Lu R, Zhao X, Li J, et al. Genomic characterisation and epidemiology of 2019 novel coronavirus: implications for virus origins and receptor binding. *Lancet* 2020;395(10224):565–574.
2. To KF, Lo AWI. Exploring the pathogenesis of severe acute respiratory syndrome (SARS): The tissue distribution of the coronavirus (SARS-CoV) and its putative receptor, angiotensin-converting enzyme 2 (ACE2). *J Pathol* 2004;203:740–743.
3. Li K, Wohlford-Lenane C, Perlman S, et al. Middle east respiratory syndrome coronavirus causes multiple organ damage and lethal disease in mice transgenic for human

4. Glass WG, Subbarao K, Murphy B, Murphy PM. Mechanisms of Host Defense following Severe Acute Respiratory Syndrome-Coronavirus (SARS-CoV) Pulmonary Infection of Mice. *J Immunol* 2004;173:4030–4039.
5. Wu P, Duan F, Luo C, et al. Characteristics of Ocular Findings of Patients With Coronavirus Disease 2019 (COVID-19) in Hubei Province, China. *JAMA Ophthalmol* 2020;2019:4–7.
6. Peiris JSM, Guan Y, Yuen KY. Severe acute respiratory syndrome. *Nat Med* 2004;10:88–97.
7. Marinho PM, Marcos AAA, Romano AC, Nascimento H, Belfort Jr R. Retinal findings in patients with COVID-19. *Lancet* 2020;395(10237):1610.
8. Gascon P, Briantais A, Bertrand E, et al. Covid-19-Associated Retinopathy: A Case Report. *Ocul Immunol Inflamm* 2020;28:1293-1297.
9. Sawalha K, Adeodokun S, Kamoga GR. COVID-19-Induced Acute Bilateral Optic Neuritis. *J Investig Med High Impact Case Reports* 2020;8:2324709620976018
10. Turkish Health Ministry, Scientific Comity Study, Guidelines for COVID-19 [Internet]. 2020. Available from: https://covid19bilgi.saglik.gov.tr/depo/rehberler/COVID-19_Rehberi.pdf?type=file,02/06/2020
11. Seah I, Agrawal R. Can the Coronavirus Disease 2019 (COVID-19) Affect the Eyes? A Review of Coronaviruses and Ocular Implications in Humans and Animals. *Ocul Immunol Inflamm* 2020;28:391-395..
12. Gralinski LE, Baric RS. Molecular pathology of emerging coronavirus infections. *J Pathol* 2015;235:185–195.
13. Wu F, Zhao S, Yu B, et al. A new coronavirus associated with human respiratory disease in China. *Nature* 2020;579:265–269.
14. Yüzbaşıoğlu E. The Latest Pandemic : Covid-19 & Eye. *Clin Exp Ocul Trauma Infect* 2020;2:3–5.
15. Yeo C, Kaushal S, Yeo D. Enteric involvement of coronaviruses: is faecal–oral transmission of SARS-CoV-2 possible? *Lancet Gastroenterol Hepatol* 2020;5:335–337.
16. Li Z, Liu T, Yang N, et al. Neurological manifestations of patients with COVID-19: potential routes of SARS-CoV-2 neuroinvasion from the periphery to the brain. *Front Med* 2020;14(5):533-541.
17. Collison FT, Carroll J. Seeking clarity on retinal findings in patients with COVID-19. *Lancet* 2020;396(10254):e38.
18. Brandão-de-Resende C, Diniz-Filho A, Vasconcelos-Santos D V. Seeking clarity on retinal findings in patients with COVID-19. *Lancet* 2020;396(10254):e37.
19. Ouyang P, Zhang X, Peng Y, Jiang B. Seeking clarity on retinal findings in patients with COVID-19. *Lancet* 2020;396(10254):e35.
20. Venkatesh P. Seeking clarity on retinal findings in patients with COVID-19. *Lancet* 2020;396(10254):e36.
21. Vavvas DG, Sarraf D, Sadda SVR, et al. Concerns about the interpretation of OCT and fundus findings in COVID-19 patients in recent Lancet publication. *Eye (Lond)* 2020;34(12):2153-2154.
22. Gündogan M, Kiliç S, Göktas S, et al. Severe COVID-19 and Retina: Are There Any Retinal Manifestations? *Klin Monbl Augenheilkd* 2022;239:284-287.
23. Pereira LA, Soares LCM, Nascimento PA, et al. Retinal

findings in hospitalised patients with severe COVID-19. *Br J Ophthalmol* 2022;106(1):102-105.

24. Ding Y, He L, Zhang Q, et al. Organ distribution of severe acute respiratory syndrome (SARS) associated coronavirus (SARS-CoV) in SARS patients: Implications for pathogenesis virus transmission pathways. *J Pathol* 2004;203:622–630.

25. Gu J, Gong E, Zhang B, et al. Multiple organ infection and the pathogenesis of SARS. *J Exp Med* 2005;202:415–424.

26. Xu J, Zhong S, Liu J, et al. Detection of Severe Acute Respiratory Syndrome Coronavirus in the Brain: Potential Role of the Chemokine Mig in Pathogenesis. *Clin Infect Dis* 2005;41:1089–1096.

27. Li YC, Bai WZ, Hashikawa T. The neuroinvasive potential of SARS-CoV2 may play a role in the respiratory failure of COVID-19 patients. *J Med Virol* 2020;92:552–555.

28. Moriguchi T, Harii N, Goto J, et al. A first case of meningitis/encephalitis associated with SARS-Coronavirus-2. *Int J Infect Dis* 2020;94:55-58.