

**Modifiye Davydov Tekniği Kullanılarak Laparoskopik Neovajina Oluşturulması****Laparoscopic Neovagina Creation by Using Modified Davydov Technique**<sup>1</sup>Serkan KAHYAOGU, <sup>2</sup>Eda UREYEN OZDEMİR<sup>1</sup>Department of Reproductive Endocrinology, Ankara City Hospital, University of Health Sciences, Ankara, Türkiye<sup>2</sup>Department of Reproductive Endocrinology, Ankara City Hospital, Ankara, TürkiyeSerkan Kahyaoglu: <https://orcid.org/0000-0001-8964-3552>Eda Ureyen Ozdemir: <https://orcid.org/0000-0001-9636-9336>**ÖZ**

Meyer Rokitamsky Kuster Hauser sendromlu 21 yaşındaki bir kadın amenore ve koitus sırasında vajinal penetrasyon sağlayamama şikayetleri ile başvurdu. Manyetik rezonans incelemede normal görünen overlerin yanında bilaterak rudimenter uterin kalıntıları ve uterus yokluğu tespit edildi. Laparoskopik olarak vajinal yolla yukarı itilmiş olan pelvik peritoneum ve vezikorektal boşluktaki vajinal apekse 3 cm'lik bir insizyon yapılarak kör vajinaya 2 parmak genişliğinde bir açıklık oluşturuldu. Ön ve arka viseral periton kenarları vajinal grasper yardımı ile yeni oluşturulmuş vajinal açıklıktan aşağı doğru çekilerek vajinal epitelyal sınıra dikildi. Purse string sütür tekniği ile sütüre edilerek yeni oluşturulmuş olan neovajinal açıklık kapatıldı. Hastanın postoperatif dönemi sorunsuz geçti. Hasta 3 ay boyunca geceleri vajinal silikon dilatör kullandı ve takiben cinsel aktivitede bulunmasına izin verildi. Modifiye Davydov prosedürü diğer cerrahi yöntemlerle karşılaştırıldığında; düşük komplikasyon oranları ve düşük vajinal stenoz oranlarının yanında daha iyi kozmetik sonuçlar ve daha yüksek seksüel tatmin oranları olan etkili bir cerrahi işlemdir.

**Anahtar Kelimeler:** Davydov, laparoskopi, vajinal agenezis, vajinoplasti

**ABSTRACT**

A-21 year-old woman diagnosed with Meyer Rokitamsky Kuster Hauser syndrome has presented with a complaint of amenorrhea and failure to have vaginal penetration during coitus. On magnetic resonance imaging, bilateral rudimentary uterine remnants next to normal-appearing ovaries with absence of uterus have been detected. Laparoscopically, a 3 cm transverse incision was made pelvic peritoneum and vaginal apex to create a two-finger width opening to the blind vagina. Anterior and posterior visceral peritoneal edges have been grasped and sutured vaginally to the vaginal epithelial border. A continuous purse string stitch technique has been utilized to close the proximal part of the neovagina. The postoperative course of the patient was uneventful. The patient kept using a vaginal silicone dilatator every night for 3 months and she was allowed to have regular coital activity after then. The modified Davydov procedure is an efficient surgical technique with lower complication rates and vaginal stenosis rates.

**Keywords:** Davydov, laparoscopy, vaginal agenesis, vaginoplasty

**Sorumlu Yazar / Corresponding Author:**

Serkan Kahyaoglu

University of Health Sciences, Ankara City Hospital, Department of Reproductive Endocrinology, Ankara, Türkiye.

Tel: +905058868040

E-mail: [mdserkankahyaoglu@gmail.com](mailto:mdserkankahyaoglu@gmail.com)**Yayın Bilgisi / Article Info:**

Gönderi Tarihi/ Received: 31/08/2022

Kabul Tarihi/ Accepted: 12/10/2022

Online Yayın Tarihi/ Published: 10/12/2022

**Atf/ Cited:** Kahyaoglu S and Ureyen Ozdemir E. Laparoscopic Neovagina Creation by Using Modified Davydov Technique. *Online Türk Sağlık Bilimleri Dergisi*, 2022;7(4):631-635. doi: 10.26453/otjhs.1169138

**INTRODUCTION**

Vaginal agenesis can be seen as an isolated congenital anomaly or as a clinical component of androgen insensitivity syndrome or Meyer Rokitamsky Kuster Hauser (MRKH) syndrome. MRKH syndrome is a polygenic congenital anomaly of the female genital system which is seen in 1 in 5000 women. Vaginal

agenesis is a part of this syndrome which precludes vaginal penetration during coital activity. Apart from the fertility issues, a vaginal reconstruction procedure is generally needed when vaginal dilatation efforts fail. Split/full-thickness skin flap technique, intestinal vaginoplasty, Vecchiatti procedure and modified Davydov procedure are second-line

surgical options to create a neovagina. The modified Davydov procedure is an efficient surgical technique with lower complication rates and vaginal stenosis rates besides higher cosmetic outcomes and sexual satisfaction rates when compared with other surgical techniques.

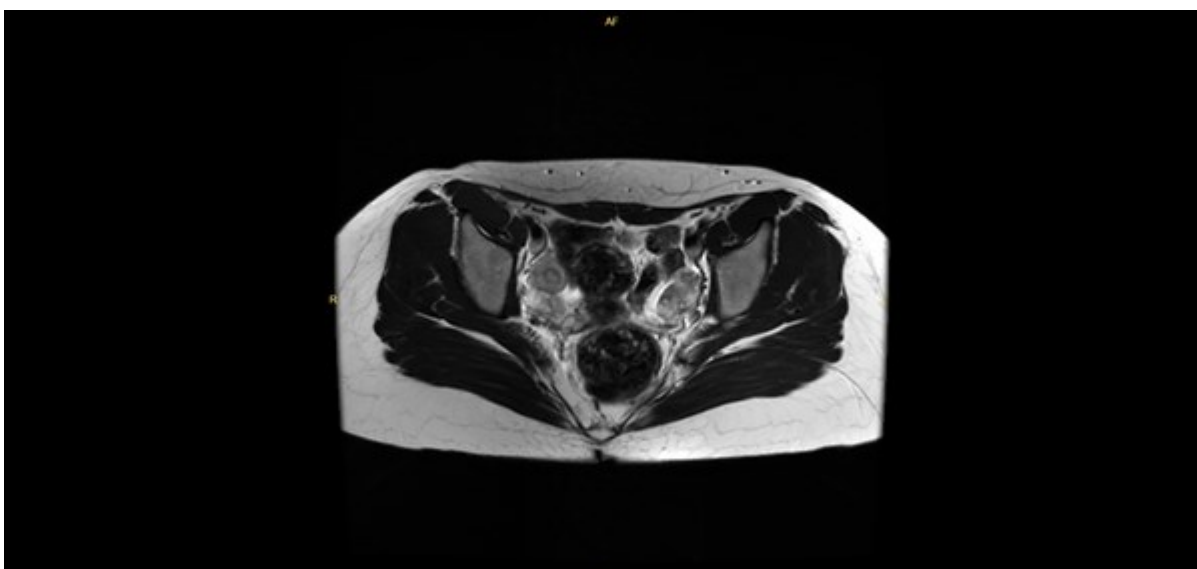
**CASE REPORT**

Since this study is a case report, ethical permission is not required. Also, this study was performed in accordance with the principles of the Declaration of Helsinki. A signed informed consent has been taken from the patient to use her surgical videos and photographs for scientific purposes.

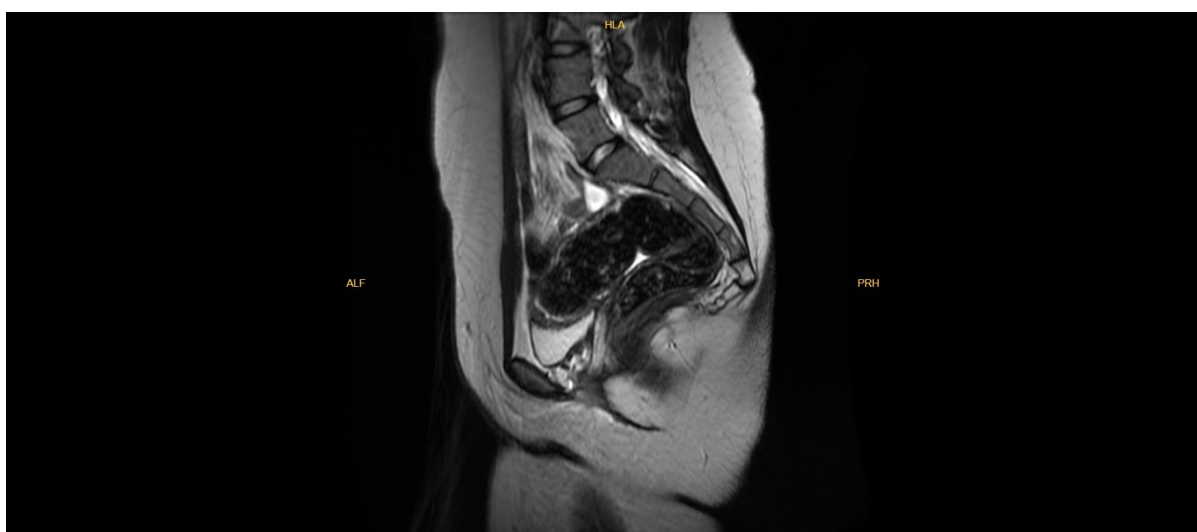A 21-year-old woman has presented to our reproductive endocrinology unit with a complaint of amenor-

rhea and failure to succeed vaginal penetration during coital activity. A blind vagina which was 2 cm long from the hymenal ring was detected upon vaginal examination. Her serum follicle-stimulating hormone, luteinising hormone, estradiol, thyroid-stimulating hormone and prolactin levels were completely in the normal range. A normal karyotype (46, XX) has been revealed upon her chromosomal analysis procedure. Suprapubic pelvic ultrasonography and magnetic resonance imaging procedures have demonstrated bilateral rudimentary uterine remnants next to normal-appearing ovaries and the absence of a uterus (Figures 1, 2).

She had previously used vaginal dilators to increase the vaginal length but these efforts have not resulted in a satisfactorily long vagina. The patient



**Figure 1.** T2 transverse magnetic resonance imaging view of bilateral rudimentary horns and



**Figure 2.** T2 sagittal magnetic resonance imaging view of pelvic cavity demonstrating uterine, cervical and vaginal agenesis.

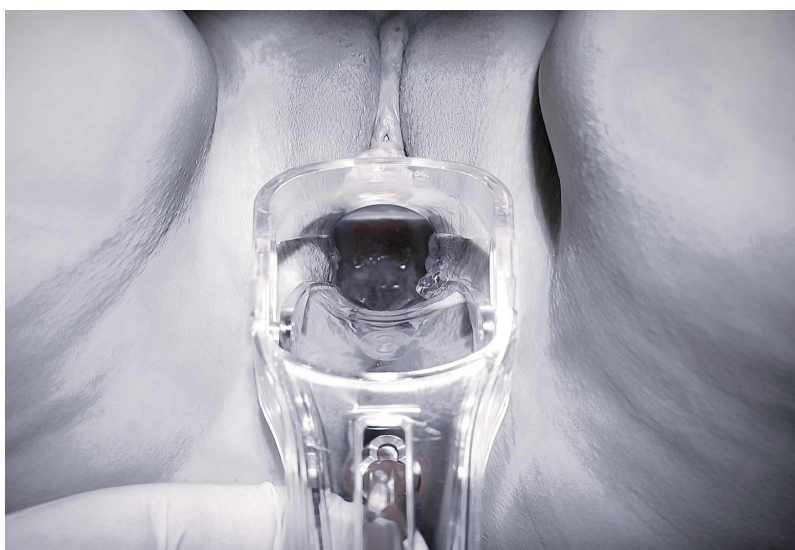
opted to have a neovagina creation procedure. Based on the outcomes, invasiveness and complication rates of currently performed neovagina procedures and the informed consent of the patient, we decided to perform a laparoscopic Modified Davydov neovagina creation procedure.

The patient has been operated in the dorsal lithotomy position. An intraumbilical 10 mm trocar has been used to visualize the abdominal cavity with a 0-degree endoscope. Three ancillary trocars, two left ipsilateral trocars and one right trocar, have been introduced. Uterine agenesis and laterally localised ovaries including rudimentary uterine horns and fallopian tubes have been seen on laparoscopic view. Bilateral pelvic ureters were detected by observation of classic transperitoneal vermication movements. A surgery assistant between the legs of the patient pushed the blind vagina upwards by using a sponge forceps. A 3 cm transverse incision was made to vaginally elevated pelvic peritoneum and vaginal apex which was on the top of the vesicorectal space by using L hook monopolar cautery to create a two finger width opening to the blind vagina. Anterior and posterior visceral peritoneal edges have been grasped and stitched by using 2/0 polyglactin sutures to facilitate pulling downwards into the vaginal mucosal edge. At this part, these two peritoneal edges have been sutured to the vaginal mucosal edge by using separate 2/0 polyglactin sutures circumferentially. Two sponges have been accommodated in a sterile condom to make a soft vaginal mold which was introduced into the abdominal cavity from the newly formed vaginal space. Bilateral fallopian tubes have been resected and exteriorized from the abdominal cavity by using a Ligasure energy device. A continuous purse string stitch technique has been

utilized which included the left rudimentary uterine horn, bladder peritoneum, right rudimentary uterine horn, right pelvic wall peritoneum, rectal serosa, left pelvic wall peritoneum and finally left rudimentary uterine horn by using a 2/0 polydioxanone (PDS) suture to close the proximal part of the neovagina. This purse-string continuous suture line has been tightened and the proximal part of the neovagina has been closed with these tissues by exerting extreme caution not to entrap rudimentary horns or ureters within this suture. Two mattress sutures by using a 2/0 PDS suture have also been used to strengthen the newly created vaginal roof (Video 1). The postoperative course of the patient was uneventful. Vaginal soft mold has been left in neovagina for 48 hours postoperatively and afterward, the patients have been advised to introduce a vaginal silicone dilator which was 10 cm long and 2 cm thick in size every night for 3 months. The patient has been discharged from the hospital on the second postoperative day. She was rescheduled for a vaginal examination on the postoperative 15th day. Vaginal mucosa has been seen in a fully healed situation and a vaginal silicon dilator was easily introduced into the neovagina. The patient kept using her silicone vaginal dilator every night for 3 months and she was allowed to have regular coital activity after then. During the second follow-up visit in 3rd month following surgery, a completely healed 9 cm neovagina has been seen upon vaginal examination (Figure 3). The patient has stated that she was experiencing satisfactory coital activity with her neovagina.

#### DISCUSSION AND CONCLUSION

The laparoscopic Davydov technique is a safe and effective option for the surgical creation of a ne-



**Figure 3.** Neovaginal examination with speculum on postoperative 3rd month demonstrated a 9 cm vaginal length.

ovagina in women with MRKH syndrome. When compared with other surgical treatment options, the main advantages of this technique are minimal invasive nature, short learning curve and low scarring in the skin of the patients. Davydov et al.<sup>1</sup> described the method in 1974 and modifications of this surgical technique have been developed by other surgeons. Adamyan et al.<sup>2</sup> have published the largest series of 324 Davydov colpocoeisis, 27 of which were performed laparoscopically. The laparoscopic approach has been performed with shorter surgical duration, shorter hospitalization days and lower intraoperative complication rates. Postoperative anatomic correction rates of vaginal agenesis were similar between laparotomy and laparoscopy cases. Fedele et al.<sup>3</sup> evaluated the anatomic and functional results after the laparoscopic Davydov procedure for the creation of a neovagina in MRKH syndrome. They concluded that this procedure was an effective and safe procedure with no perioperative complications and high anatomic and functional success rates which were demonstrated with the application of the Female Sexual Function Index (FSFI) questionnaire to the patients. Postoperative vaginoscopy and vaginal biopsy results of the neovagina have shown iodine-positive multiple-layer vaginal epithelium in the formerly single-layer epithelial tissue of the vaginal apex. Dargent et al.<sup>4</sup> have published the surgical outcomes of 28 MRKH syndromes. They have concluded that two perioperative and two postoperative complications have occurred. Four patients have like incision and dilatation have been needed in their patient cohort. In this study, the authors have recommended the Davydov procedure as a good alternative to more complex Vecchietti procedures and more invasive intestinal vaginoplasty. The modification of the Davydov colpocoeisis procedure included a laparoscopic step during which transverse mobilization of supravescical and bilateral lateral pelvic walls' peritoneal tissues, 1-2 purse string late absorbable suture placement and as a last step vesicorectal dissection and anastomosis of the peritoneum to the vaginal vestibulum. In our case report, we have not dissected any peritoneal tissue or vesicorectal space. Directly elevation of the blind vagina by using sponge forceps has delineated the exact point of the roof of the neovagina on laparoscopic view. We have paid attention not to include rudimentary horns or ovaries below the purse string suture. During the lateral pelvic wall suture placement part of the purse string suture, both superior and inferior parts of the lateral pelvic wall peritoneum have been caught by the suture to decrease ureteral obstruction risk. We utilized only one purse string 2/0 PDS suture to form the neovaginal apex and we also empowered the neovaginal apex by using two additional 2/0 PDS mattress sutures to de-

crease tension on the pelvic peritoneum. Neovaginal/peritoneal sutured edge was located 5 cm high from the introitus. We have spared both round ligaments and rudimentary uterine horns to support the neovaginal apex and we resected both fallopian tubes to decrease the future probability of ectopic pregnancy and high-grade ovarian cancer risk. The total surgery duration was 110 minutes including the vaginal part of the procedure. McIndoe, Vecchietti and sigmoid vaginoplasty techniques, which are performed to create neovagina, necessitate sophisticated surgical instruments and a multidisciplinary approach, unlike laparoscopic Davydov procedure which can be easily performed by a gynecologist who is experienced in laparoscopy and vaginal surgery. Besides, complication rates of the Davydov technique have been reported to be very low which involve intraoperative damage to the bladder, ureters, or rectum.<sup>5-8</sup> Based on the FSFI results of the patients, postoperative sexual satisfaction rates were comparable with the age-matched controls except for insufficient lubrication and rare mild superficial/deep dyspareunia which was reported in one study.<sup>9,10</sup> Subjectivity of sexual satisfaction evaluation tests and patients' motivation to maintain their neovaginal integrity by performing regular coital activity preclude the reliability of the studies' postoperative sexual satisfaction results.

In conclusion, the laparoscopic modified Davydov technique is an effective and safe surgical procedure to create a neovagina for vaginal agenesis with high postoperative sexual satisfaction scores.

**Ethics Committee Approval:** Since this study is a case report, ethical permission is not required. Also, this study was performed in accordance with the principles of the Declaration of Helsinki. A signed informed consent has been taken from the patient to use her surgical videos and photographs for scientific purposes.

**Conflict of Interest:** No conflict of interest was declared by the authors.

**Author Contributions:** Concept– SK; Supervision– SK; Materials – SK, EUO; Data Collection and/or Processing – SK, EUO; Analysis and/or Interpretation– SK, EUO; Writing – SK.

**Peer-review:** Externally peer-reviewed.

## REFERENCES

1. Davydov SN, Zhvitiashvili OD. Formation of vagina (colpocoeisis) from peritoneum of Douglas pouch. *Acta Chir Plast.* 1974;16(1):35-41.
2. Adamyan LV, Kulakov VI, Murvatov KD, Zurabiani Z. Application of endoscopy in surgery for malformations of genitalia. *J Am Assoc Gynecol Laparosc.* 1994;1(4, Part 2):1. doi:10.1016/s1074-3804(05)80868-0

3. Fedele L, Frontino G, Restelli E, Ciappina N, Motta F, Bianchi S. Creation of a neovagina by Davydov's laparoscopic modified technique in patients with Rokitansky syndrome. *Am J Obstet Gynecol.* 2010;202(1):33.e1-6. doi:10.1016/j.ajog.2009.08.035
4. Dargent D, Marchiolè P, Giannesi A, Benchaïb M, Chevret-Méasson M, Mathevet P. Laparoscopic Davydov or laparoscopic transposition of the peritoneal colpoptosis described by Davydov for the treatment of congenital vaginal genesis: the technique and its evolution. *Gynecol Obstet Fertil.* 2004;32(12):1023-1030.
5. Darai E, Toullalan O, Besse O, Potiron L, Delga P. Anatomic and functional results of laparoscopic-perineal neovagina construction by sigmoid colpoplasty in women with Rokitansky's syndrome. *Hum Reprod.* 2003;18(11):2454-2459.
6. Giannesi A, Marchiole P, Benchaib M, Chevret-Measson M, Mathevet P, Dargent D. Sexuality after laparoscopic Davydov in patients affected by congenital complete vaginal agenesis associated with uterine agenesis or hypoplasia. *Hum Reprod.* 2005;20(10):2954-2957.
7. Ismail IS, Cutner AS, Creighton SM. Laparoscopic vaginoplasty: Alternative techniques in vaginal reconstruction. *BJOG.* 2006;113(3):340-343. doi:10.1111/j.1471-0528.2005.00845.x
8. Templeman CL, Hertweck SP, Levine RL, Reich H. Use of laparoscopically mobilized peritoneum in the creation of a neovagina. *Fertil Steril.* 2000;74(3):589-592. doi:10.1016/s0015-0282(00)00700-7.74:589-92
9. Rosen R, Brown C, Heiman J, et al. The Female Sexual Function Index (FSFI): A multidimensional self-report instrument for the assessment of female sexual function. *J Sex Marital Ther.* 2000;26(2):191-208. doi:10.1080/009262300278597
10. Yang X, Zhu L, Wang YJ, et al. Comparison of the modified laparoscopic Vecchietti and Davydov colpoplasty techniques in Mayer-Rokitansky-Küster-Hauser syndrome: A long-term follow-up analysis. *J Obstet Gynaecol Res.* 2022;48(7):1930-1937. doi:10.1111/jog.15262