

The importance of linear measurements made using panoramic radiography in pre-implant site assessment: actual vs. measured

Raif Alan¹  Ahmet Afşin Erbeyoğlu² 

1 Çanakkale Onsekiz Mart University, Faculty of Dentistry, Department of Periodontology, Çanakkale, Turkey.

2 Private Practice, Division of Periodontics, İstanbul, Turkey.

Abstract

Background: In order to reduce post-operative failure and ensure successful rehabilitation, patients scheduled for dental implant treatment are often evaluated pre-operatively using radiographic images in addition to clinical examination. This study aimed to investigate the reliability of digital panoramic radiography in the pre-implant site assessment.

Methods: Panoramic images of 150 patients with a total of 396 implants placed in the maxilla (n=165) and mandible (n=231), were examined in the study. Radiographic measurements (vertical and horizontal) were recorded on the computer using the automatic calibration tab for each radiograph and compared with the actual implant dimensions. Moreover, the effects of location, gender, and change in dimensions on magnification rate (MR) were also investigated. The measurements were made by two experienced observers.

Results: Panoramic vertical measurements were significantly higher in both the maxilla and mandible compared to the actual implant lengths ($p<0.05$), with excellent inter-observer agreement values ($r=0.969$). MR of horizontal measurements showed significant differences just in the premolar and molar regions ($p<0.05$). MR exhibited negative correlation with increases in the implant length and diameter.

Conclusions: When attempting to use panoramic radiographs for pre-implant site assessment, the MRs should be considered along with a good clinical examination and experience.

Keywords: Dental Implants, Dimensional Measurement Accuracy, Image Processing, Panoramic Radiography.

Cite this article as: Alan R, Erbeyoğlu AA. The importance of linear measurements made using panoramic radiography in pre-implant site assessment: actual vs. measured. Arch Curr Med Res. 2023;4(1):24-30

Corresponding Author:

Raif Alan, Çanakkale Onsekiz Mart University, Faculty of Dentistry, Department of Periodontology, Çanakkale, Turkey.
E-Mail: drraifalan17@gmail.com



Content of this journal is licensed under a Creative Commons Attribution-NonCommercial 4.0 International License.

INTRODUCTION

Prior to dental implant surgery, evaluation of the height of the residual alveolar bone in the region where the dental implants will be inserted, the position of the base of the nose and maxillary sinus, the position of the mandibular canal, the determination of lesions in the bones and the distance to the adjacent dental roots are prerequisites (1). The presence of a restricted bone volume and weak bone quality may result in early implant failure and less predictable bone apposition. A comprehensive radiographic evaluation is crucial to evaluate these factors and to inform patients about dental implants for successful rehabilitation. The purpose of the pre-operative radiographic assessment is to detect pathological lesions, determine critical structures in potential implant sites and the guidance of the implants. Bone quantity and quality will affect the selection of implants by number, diameter, length, and type (2).

In recent years, the frequency of Computed Tomography (CT) and Cone Beam Computed Tomography (CBCT) usage has increased for pre-implantation evaluation. CT and CBCT techniques allow the anatomical osseous structures to be displayed in three planes in accordance with the dimensions and show the best image quality without distortion (3-5). However, if there are metal components, CT may produce artifact lines. In addition, another disadvantage of CT is that the patient has to stand still for a relatively long-time during imaging (6,7).

Panoramic radiographs are often used as a radiographic method for the preparation of pre-implant evaluation and treatment protocols (1). Panoramic radiographs are fast, inexpensive and their radiation dose is low in comparison to CTs and other equivalent/similar techniques (6,7). On the other hand, unpredictable distortion of structures, low level of repeatability (2) and uneven magnification of parts (8) are the main disadvantages of panoramic radiography.

Due to the widespread use and sometimes first choice method, it becomes a question of whether panoramic radiographs are reliable due to these disadvantages. The aim of this study is to examine the reliability of panoramic radiography in the pre-implant region evaluation by considering the dimensions of the dental implants placed.

MATERIALS AND METHODS

This retrospective study was approved by the ethics committee of the Faculty of Dentistry at Necmettin Erbakan University (Date 08.2018, Decision Number 2018/02) and conducted in the Department of Periodontology, Faculty of Dentistry, Necmettin Erbakan University. The sample group was gathered from the panoramic radiographic images (pre-op. and postop.) of 150 patients with implants placed in the edentulous areas. A total of 396 implants from 7 different implant systems were placed in the edentulous areas.

Panoramic images were obtained with Morita Veraviewepocs 3D Digital Panoramic X-Ray Device (J. Morita Corp, Kyoto, Japan). Dental implant application areas were divided into four groups; anterior, canine, premolar and molar regions. Radiographic measurements (vertical and horizontal) were recorded on the computer using the automatic calibration tab for each radiograph and compared with the actual implant dimensions. To determine the radiographic linear measurements of surgically placed implants, the distance corresponding to the length and diameter of implant recommended by the dental implant manufacturers was measured. Moreover, the magnification rate (MR) was calculated for each implant as follows: (radiological implant dimensions/ actual implant dimensions) \times 100 (1). In addition, the effects of gender, implant sites (anterior, canine, premolar or molar region), locations (maxilla or mandible), increase in length and diameter on MR were also investigated. Dental implant application and radiographic analysis were performed by two experienced physicians.

The data were analyzed using SPSS 17.0 (SPSS Inc., Chicago, USA) for Windows. All data were first analyzed descriptively and presented as mean, SD, min and max values. Kruskal-Wallis and Mann-Whitney U test were used to compare the mean values. Correlation between observers was analyzed using Pearson correlation coefficient. The significance level was set at $p < 0.05$.

RESULTS

Of the 396 implants, 165 and 231 implants were placed in the maxilla and mandible, respectively. The distribution of the actual length and diameters of implants analyzed according to their placement areas were presented in Figure 1.

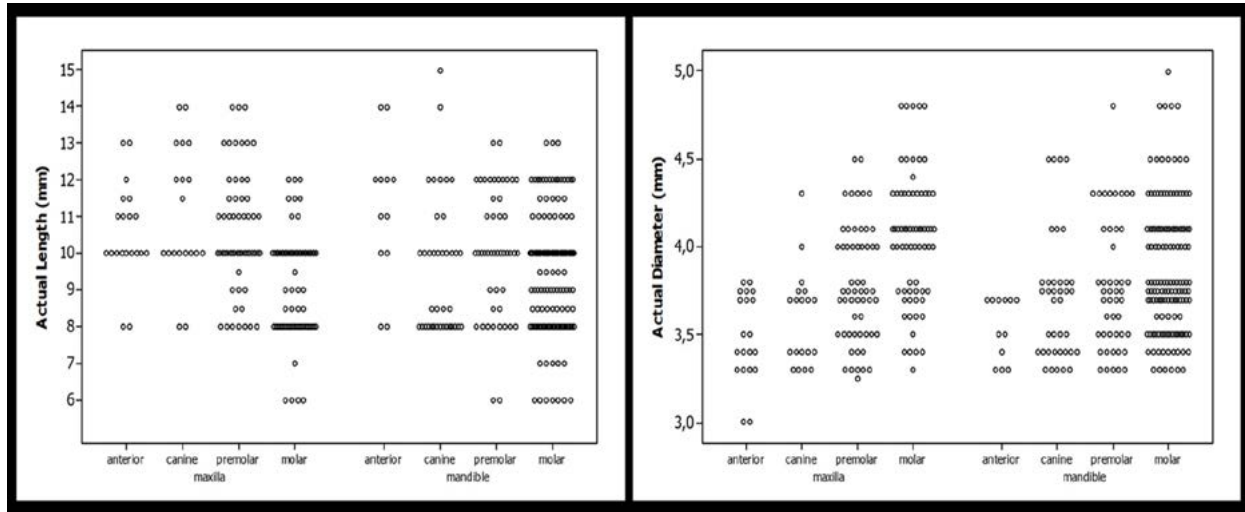


Figure 1. Distribution of actual implant dimensions according to their placement areas.

An evaluation with respect to the locations showed that inter-observer reliability was good and the correlation coefficient for vertical measurements was 0.969. The radiographic vertical measurements were significantly high in both maxilla and mandible, compared with the

known implant lengths ($p < 0.05$). On the other hand, significant differences between observers were found according to horizontal measurements in both maxilla and mandible although excellent inter-observer agreement values were obtained in vertical measurements (Table 1).

Table 1. Comparison of the radiographic and actual implant dimensions.

Maxilla ($n=165$)									
Length					Diameter				
	Mean	SD	Min	Max		Mean	SD	Min	Max
Actual	10.03	1.72	6.00	14.00		3.84	0.39	3.00	4.80
Obs-1	10.42 ^a	1.66	7.25	14.90		3.86	0.53	2.55	5.45
Obs-2	10.51 ^a	1.66	7.00	14.80		3.73 ^{ab}	0.50	2.60	5.00
p-value	0.006				p-value	0.024			
Mandible ($n=231$)									
Length					Diameter				
	Mean	SD	Min	Max		Mean	SD	Min	Max
Actual	9.70	1.76	6.00	15.00		3.81	0.37	3.30	5.00
Obs-1	10.20 ^a	1.78	5.45	15.00		4.02 ^a	0.49	2.85	5.80
Obs-2	10.31 ^a	1.76	6.10	14.80		3.89 ^b	0.50	2.90	5.80
p-value	<0.001				p-value	<0.001			

These notations must be deleted because the actual p-values were indicated in the table.

^astatistically significant difference according to actual measures

^bstatistically significant difference according to Obs-1

Comparison of the total MRs of the length and diameter according to the location (maxilla or mandible), and the anterior, canine, premolar, and molar regions for both

observers were presented in Table 2. There were significant differences between MR of horizontal measurements just in the premolar and molar regions ($p < 0.05$).

Table 2. Comparison of the MRs of the length and diameter according to the regions.

	Maxilla ($n=165$)								
	MR _{Length} mean±SD					MR _{Diameter} mean±SD			
	anterior	canine	premolar	molar		anterior	canine	premolar	molar
Obs-1	0.99±0.06	1.01±0.04	1.04±0.04	1.07±0.06		1.00±0.15	1.02±0.14	0.99±0.09	1.02±0.10
Obs-2	1.01±0.04	1.04±0.05	1.05±0.04	1.08±0.07		0.97±0.13	1.00±0.10	0.96±0.08	0.98±0.09
p-value	0.279	0.075	0.339	0.711		0.279	0.430	0.040	0.015
	Mandible ($n=231$)								
	MR _{Length} mean±SD					MR _{Diameter} mean±SD			
	anterior	canine	premolar	molar		anterior	canine	premolar	molar
Obs-1	1.02±0.07	1.06±0.04	1.04±0.05	1.06±0.04		1.14±0.17	1.13±0.11	1.07±0.11	1.03±0.09
Obs-2	1.06±0.07	1.07±0.04	1.06±0.04	1.07±0.05		1.06±0.14	1.09±0.13	1.04±0.10	1.00±0.09
p-value	0.119	0.063	0.067	0.413		0.165	0.104	0.063	0.001

These notations must be deleted because the actual p-values were indicated in the table.

MR= Magnification Ratio

The effects of an increase in length and diameter of the implant on MRs for both observers were presented in Figure 2. MR exhibited negative correlation with

increasing in the implant length and diameter. Increase in length and diameter of the implant decrease MRs for both observers.

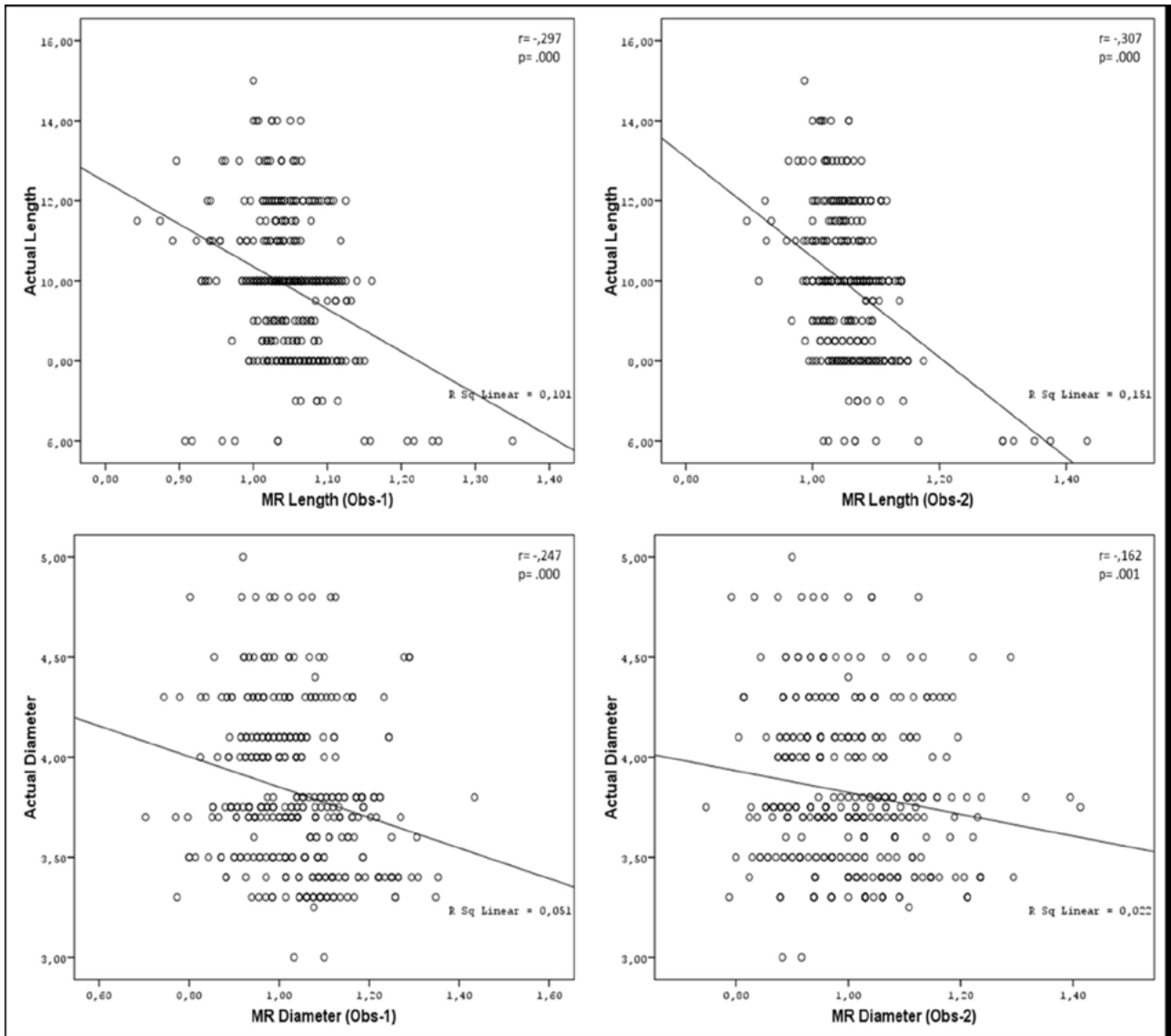


Figure 2. The effects of an increase in length and diameter of the implant on MRs.

In 150 patients whose radiographic images were analyzed, there were 80 female and 70 male patients with a mean age of 48.70 ± 13.28 and 54.14 ± 11.96 , respectively. There was significant difference in the magnification of diameter for

the implant in regard to gender for both observers. Based on this, the average MRs of the diameter was higher in females than those in males for both observers ($p < 0.001$) (Table 3).

Table 3. Comparison of the MRs of the implant dimensions according to gender.

	MR _{Length}									
	Female				Male					
	Mean	SD	Min	Max	Mean	SD	Min	Max		
Obs-1	1.06	0.05	0.84	1.35		1.04	0.05	0.89	1.25	0.007
Obs-2	1.06	0.05	0.90	1.32		1.06	0.06	0.93	1.43	0.396
	MR _{Diameter}									
	Female				Male					
	Mean	SD	Min	Max	Mean	SD	Min	Max		
Obs-1	1.07	0.11	0.80	1.43		1.01	0.11	0.70	1.29	<0.001
Obs-2	1.02	0.10	0.79	1.41		0.98	0.10	0.75	1.40	<0.001

These notations must be deleted because the actual p-values were indicated in the table.

MR= Magnification Ratio

DISCUSSION

Appropriate treatment planning is an essential step in implant treatment, and radiographic evaluation of the recipient area for an appropriately sized implant selection is an indispensable part of this procedure (9). Digital panoramic radiographs are a valuable aid in implant dentistry for helping preoperative diagnosis and treatment planning. In most cases, these radiographs, together with appropriate clinical examination, may be sufficient to determine the size and location of the implants if distortion is taken into account (10).

Distortion is one of the limitations of panoramic radiographs and occurs when the degree of magnification changes in vertical and horizontal planes (11). Image magnification can be affected by different factors such as patient position, jaw shape and size, mandibular angulation, implant type, gender, and anatomical area in the jaw (12,13). In addition, based on the results of this study, it is believed that the probability of the MR increasing is related to the decrease in the measured distance.

Choi et al. (12) evaluated the effects of gender on magnification and concluded that the horizontal magnification was significantly higher in females. However, gender did not affect vertical magnification. In addition, in another study, the authors found that there

was no significant difference in vertical and horizontal magnifications of implants by gender (1). On the contrary, in the present study, higher horizontal MR was detected in females for both observers. These differences are thought to confirm the view that the jaw structure (shape, size) is effective on MR.

Kim et al. (1) found that vertical and horizontal MR differ significantly depending on the anatomical location and stated that the maxilla tends to be slightly more distorted when compared to the mandible. Similarly, in this study, a significant difference was observed in the premolar region in addition to the molar region in the maxilla in terms of horizontal MR. On the other hand, it has been reported that digital panoramic radiography can accurately determine the length of the preoperative implant in the premolar and molar mandibular segments (14). As mentioned earlier, these differences may occur depending on the patient's position, jaw shape/size, and mandibular angulation (12,13). To reduce positional errors, the calibration using the correct bite block and guide beam lines can be beneficial (13).

The vertical size should be carefully evaluated and an adequate margin of safety should be established, especially when the treatment site is close to vital structures such as the inferior alveolar canal and the maxillary sinus (10). Vazquez et al. (14) have confirmed that vertical measurements have acceptable accuracy and

repeatability, and if a software-based calibrated measuring instrument is used, digital panoramic radiography can be safely used to determine the preoperative length of the implant in the premolar and molar mandibular segments. In this study, higher vertical and horizontal radiographic measurements were found in both jaws compared to the actual implant size. In addition, although there was no difference between observers in vertical measurements, a difference was observed in horizontal measurements. On the contrary, another study reported no difference between the actual diameter in both the mandible and the maxilla and radiographic measurements (10). This discrepancy may be a problem in the clinic. The choice of the length and diameter of the implant is primarily determined by the volume of the alveolar crest, the position of the adjacent teeth and the location of the vital anatomical structures. This is based on the principle that the implant body should ideally be encircled by a sufficient bone quantity. It is sensible to assume that an attentive radiographic evaluation and excellent implant size selection reduce the risk of injury and associated complications of vital anatomical structures (9). Since jaw size and shape, mandibular angulation, and patient position, which are not evaluated in this study and can therefore be considered as limitations, may affect the magnification (12,13), further studies including these factors are recommended to overcome these limitations.

In conclusion, MRs of panoramic radiographs and the factors affecting these MRs should be taken into account during the pre-implant site assessment. Thus, the chance of success in implant placement can be increased. Therefore, the clinician is expected to be successful in estimating appropriate implant sizes with experience in radiographic measurements (reading calibration skills). This reduces the risk of unexpected events and any injuries or complications during and after the procedure.

Declarations

The authors received no financial support for the research and/or authorship of this article. There is no conflict of interest.

This study was approved by the ethics committee of the Faculty of Dentistry at Necmettin Erbakan University. (Date 08.2018, Decision Number 2018/02).

REFERENCES

1. Kim YK, Park JY, Kim SG, Kim JS, Kim JD. Magnification rate of digital panoramic radiographs and its effectiveness for preoperative assessment of dental implants. *Dentomaxillofac Radiol.* 2011;40(2):76-83.
2. Siu AS, Chu FC, Li TK, Chow T, Deng F. Imaging modalities for preoperative assessment in dental implant therapy: an overview. *Hong Kong Dent J.* 2010;7:23-30.
3. Mengel R, Candir M, Shiratori K, Flores-de-Jacoby L. Digital volume tomography in the diagnosis of periodontal defects: an in vitro study on native pig and human mandibles. *J Periodontol.* 2005;76(5):665-73.
4. Mengel R, Kruse B, Flores-de-Jacoby L. Digital volume tomography in the diagnosis of peri-implant defects: an in vitro study on native pig mandibles. *J Periodontol.* 2006;77(7):1234-41.
5. Tohna S, Mehnert AJ, Mahoney M, Crozier S. Synthesizing dental radiographs for human identification. *J Dent Res.* 2007;86(11):1057-62.
6. Cho YS. Diagnostic value of dental CT (DentaScan) in dental implant. *Chungbuk Med J.* 1998;8:11-9.
7. Nagarajan A, Perumalsamy R, Thyagarajan R, Namasivayam A. Diagnostic imaging for dental implant therapy. *J Clin Imaging Sci.* 2014;27:4(Suppl 2):4.
8. Ogawa K, Langlais RP, McDavid WD, Noujeim M, Seki K, Okano T, et al. Development of a new dental panoramic radiographic system based on a tomosynthesis method. *Dentomaxillofac Radiol.* 2010;39(1):47-53.
9. Schropp L, Stavropoulos A, Gottfredsen E, Wenzel A. Comparison of panoramic and conventional cross-sectional tomography for preoperative selection of implant size. *Clin Oral Implants Res.* 2011;22(4):424-9.
10. Kayal RA. Distortion of digital panoramic radiographs used for implant site assessment. *J Orthod Sci.* 2016;5(4):117-20.
11. McDavid WD, Dove SB, Welander U, Tronje G. Dimensional reproduction in direct digital rotational panoramic radiography. *Oral Surg Oral Med Oral Pathol.* 1993;75(4):523-7.
12. Choi YG, Kim YK, Eckert SE, Shim CH. Cross-sectional study of the factors that influence radiographic magnification of implant diameter and length. *Int J Oral Maxillofac Implants.* 2004;19(4):594-6.
13. Park JB. The evaluation of digital panoramic radiographs taken for implant dentistry in the daily practice. *Med Oral Patol Oral Cir Bucal.* 2010;15(4):e663-6.
14. Vazquez L, Nizamaldin Y, Combesure C, Nedir R, Bischof M, Dohan Ehrenfest DM, et al. Accuracy of vertical height measurements on direct digital panoramic radiographs using posterior mandibular implants and metal balls as reference objects. *Dentomaxillofac Radiol.* 2013;42(2):20110429.