



Pregnancy Diagnosis in Goats By Ultrasonography

Sinem Özlem ENGİNLER¹, Kutlay GÜRBULAK²

¹Department of Obstetrics and Gynaecology, Faculty of Veterinary Medicine, Istanbul University, Avcılar Campus, 34320, Avcılar, Istanbul-TURKEY

²Department of Obstetrics and Gynaecology, Faculty of Veterinary Medicine, Erciyes University, Kayseri-TURKEY

Summary: Ultrasonography is a technique commonly used in veterinary reproduction in species including goats. Pregnancy in goats can be detected as early as the 16th day post-breeding via transrectal way. However, because of the early embryonic losses, it is recommended to delay the transrectal examination until days 32-34 of gestation. Transabdominal (TA) ultrasonography for pregnancy diagnosis in goats can be preferred from the second trimester on because after this period the gravid uterus starts to descend into the cranio-ventral direction. The transrectal (TR) ultrasonography in this period becomes inadequate to distinguish the parts of the foetus. But it can still detect the pregnancy. By using the TA ultrasonography with 3.5mHz, fluid filled vesicles were observed approximately from 25 day onwards in goats. Transvaginal ultrasound scanning can be an early pregnancy diagnosis in goats approximately 7 weeks post mating. In conclusion, the TR can be considered superior to TA in small ruminants to detect the pregnancy as it leads 4-5 days earlier diagnosis in the TR way than the TA way. Pregnancy can be detected, using the TR ultrasonography after second trimester; but, as the gravid uterus descends cranio-ventral direction, it is difficult to distinguish the parts of the foetus. In this review, the ways of ultrasonography for pregnancy determination in goats were discussed.

Key Words: Goat, pregnancy determination, ultrasonography

Keçilerde Ultrasonografi ile Gebelik Teşhisi

Özet: Ultrasonografi veteriner reproduksiyonunda keçileri de içeren türlerde sıklıkla kullanılan bir tekniktir. Transrektal yolla keçilerde gebelik çiftleşmeden sonra en erken 16.günde saptanabilir. Ama keçilerde erken embriyonik ölümlerden transrektal muayene için dolayı gebeliğin 32-34. günlerine kadar beklenilmesi önerilir. Keçilerde transabdominal ultrasonografi (TA) ile gebelik teşhisi gebeliğin 2. yarısından sonra tercih edilebilir çünkü bu dönemden sonra gebe uterus cranio-ventrale doğru inmeye başlar ve transrektal ultrasonografi bu dönemde yavru kısımlarının ayırt edilmesinde yetersiz kalırken gebelik yine bu yolla da teşhis edilebilir. Keçilerde 3.5 mHz TA ultrasonografi ile içi sıvı dolu keseler yaklaşık 25 gün ve sonrasında rahatlıkla gözlemlenmiştir. Transvaginal ultrasonografi taraması keçilerde çiftleşme sonrasında yaklaşık 7.haftada erken gebeliğin teşhisine izin verebilir. Sonuç olarak, TR, TA'ya göre gebeliği 4-5 gün önceden teşhis etmeye izin verdiği için daha iyi olarak düşünülebilir. Gebelik, TR muayenesinde de teşhis edilebilir fakat gebe uterus cranio-ventrale indiğinden fôtusun kısımlarının ayırt edilmesi güçtür. Bu derlemede, keçilerde gebeliğin saptanmasında ultrasonografinin yolları tartışıldı.

Anahtar Kelimeler: Gebelik teşhisi, keçi, ultrasonografi

Introduction

Pregnancy in a goat herd would require the farmer to consider some special animal expenses like feed, labour and labour management because pregnant animals may require special feed supplementation, extra care and special areas to shelter. Thus, with the special feed supplementantation, mortality due to metabolic diseases like pregnancy toxemia incidence can decrease (16).

Considerably, costs associated with diseases can be reduced. Moreover, pregnancy detection aids culling or rebreeding of barren does and provides a valuable tool for controlled breeding programs. In addition, the exact information about the stage of gestation could be effective on drying off the lactating animals for adequate period and to monitor females near birth

(13). Inability to detect early pregnancy can result in economic losses in milk and offspring production due to longer kidding intervals. Ultrasonography has been used in small ruminants to detect pregnancy. The Doppler system (42) based on the fetal circulation or fetal movements and A mode system (44) which detects tissue interfaces with different acoustic impedance can detect pregnancy during the second half of the gestation accurately.

Real-time (B-mode) ultrasonography has been available since the early 1980s. It is rapid, safe and practical to diagnose pregnancy in livestock. Improvement in small ruminants' ultrasonography techniques for detection of pregnancy is the priority for accurately managing reproduction. The present paper was aimed to review the best way for pregnancy diagnosis in goats by ultrasonography.

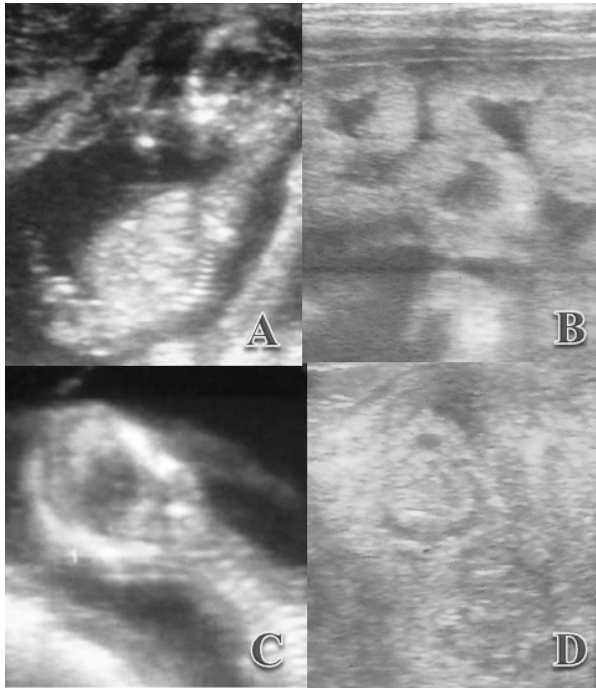


Figure 1. Foetus of a Saanen goat during pregnancy (A) (Enginler 2013). Placentome during pregnancy in a Saanen goat (B) (Enginler 2013). Foetal biparietal diameter in a Saanen goat foetus during gestation (C) (Enginler 2013). Postpartum uterine involution in a Saanen goat (D) (Enginler 2013).

Ultrasonography

Ultrasound is defined as any sound frequency above the human ear range greater than 20,000 Hz. Sound waves in ultrasound devices are produced from the vibration of special crystals named “piezoelectric crystals” located in an ultrasound transducer. Vibration of these crystals was formed with the electric current pulses. A proportion of the sound waves reflected back to the probe is converted to electric current and leads to display an echo on the ultrasound screen. The transducer acts like both sender and receiver of the echoes.

These echoes shade like the tones of gray on the screen (31). Yet, ultrasound is a preferable tool as it is simple, reliable and invasive technique in small ruminants. Early pregnancy and embryo determination by ultrasonography in goats can be distinguished as echogenic areas in anechogenic regions. Besides, foetal vesicles, foetus, foetal organs and foetal movements, skull, foetal bones, ribs can be seen in advanced pregnancy (8). Ultrasonography can be applied via transrectally, transabdominally (transcutaneously) and transvaginally in goats. Linear, sector and convex probes can be used during ultrasonography with the frequency of 3.5-5-7.5 mHz as probe options in small ruminants.

1)A-mode Ultrasonic Techniques

Ultrasound waves are reflected between different tissues to the transducers which converts the electrical energy in the form of audible or visual signals and sounds from tissues are shown as vertical deviations on a baseline on the screen (7, 23). Units with an oscilloscope display reflections as peaks or blips on the screen (11). These units are sensitive at a depth of 10 to 20 cm. The transducer can be placed in front of the udder while animal is at standing position (23). A-mode ultrasound has been reported to be reliable from 50 to 120 days of gestation in sheep and goats (43,44). Although A-mode is a quick, practical technique, it is not possible to evaluate the foetal number or viability with A-mode ultrasonography (15). Non-pregnancy is considered when the peaks are present only in the left half of the screen. When fluid-filled structure is observed, peaks can be able to visualise on the right half of the screen too (11). Accuracy was detected in a study (11) as 80-85% between 60-120 days of gestation.

2)TM mode Ultrasonic Techniques

In this technique, horizontal scans are continuously analyzed with respect to time on a screen in which data can be obtained with an A-mode unit. Mobile structures can be displayed as oblique lines (graphs) and immobile structures can be displayed as direct lines on the screen (7). This tool includes an A-mode unit which is completed with an electronic system which allows to scan by time. During scanning, obtained images can be seen as a photo or can be printed on a paper strip in the form of perpetual motion type electrocardiography. The TM-mode recently has been used in cardiology, it can also be useful to obtain heart activities and to observe of the fetal movements in obstetrical ecography (7).

3)Real-Time B-mode Ultrasonic Techniques

Real-time B mode ultrasonography was developed in Australia. In this method, the lines in A-mode can be displayed as points. The brightness of the points shows the severity of reflected sounds. Topographic acoustic cross section of the area can be obtained when the transducer was moved at intended plans (23). It produces two dimensional moving images of the uterus, foetal fluids, foetus, foetal heart beat and placentomes on the screen which can be photographed by a camera (7,23). Real-time B mode ultrasonography allows effective diagnosis, especially in obstetrics and gynaecology (12,34).

a)Transrectal Ultrasonography: The goat’s rectum can be manually emptied before the examination and ultrasonic coupling gel can be applied to the transducer face covered with a lubricated plastic sleeve before its introduction into the rectum. The transducer is then progressed cranially along the rectal floor to overlie the reproductive tract. Similar to

this transrectal technique, Gürbulak et al. (19) have used the extension rod with prob to detect postpartum uterine involution in Tuj Breed sheep. The transducer face must be pressed firmly against the rectal mucosa in order to facilitate the visualisation of the gestational sac properly. A straw bale can be located under the animal or abdomen can be pushed upwards manually to allow the foetus seen on the equipment's monitor. Santiago-Moreno et al. (38,39) have reported the earliest pregnancy period as 16th day of the gestation in goats via transrectal way. Singh et al. (41) have used 5mHz B-mode transrectal transducer for early pregnancy diagnosis and their accuracy was detected as 66% (4/6) from 17 to 19th days; 83% (5/6) from 21 to 23th days and 100% (6/6) from 24 to 26th days, respectively.

Amer (3) reported a small non-echogenic vesicle about 1 cm in diameter in the uterine lumen from 19.5 ± 0.3 day onwards and the foetal heart beat was distinguished on day 22.9 ± 0.7 by the same author using 6 mHz TR ultrasonography. Padilla-Rivas et al. (32) have reported that they predicted the pregnancy from day 21.9 onwards, using 7.5mHz linear array transducer transrectally in Boer goats. Four days later on day 26 the foetal heart beat was recognizable. Baronet and Vaillancourt (8) have reported that pregnancy could be diagnosed at the 20-30th gestation day by TR ultrasonography. Besides, Arthur et al. (6) have reported accurate detection of pregnancy after the 25th day of gestation transrectally in goats. In the TR ultrasonography, 3.5-5-7.5mHz transducers can be used properly and in early pregnancy detection, 7.5mHz transducer can be preferred. Gonzales-Bulnes et al. (18) recommended not to perform ultrasonography until the 32-34th days of gestation because of the early embryonic losses in goats. Garcia et al. (17) reported the accurate fetal number detection as the 45-50th gestational day. Placentomes can be detected by the TR ultrasonography, using a 5mHz linear probe between days 28 to 30 of gestation. They firstly appear as small echogenic areas on the surface of the endometrium, later as the gestational age increases the placentomes appear as cup-shaped, hyperechogenic structures with the concave surfaces (8-10,21). Authors (8,10,20,27,35,37) have reported that 3-5mHz transducers could be used to detect pregnancy in goats for either the TA and the TR ultrasonography. Some fluid filled compartments can be an evidence for pregnancy that can be observed a few days earlier by the TR ultrasonography than the TA ultrasonography (24). Hesselink and Taverne (22) have reported that foetus could not be observed using the TR ultrasonography in goats at day 30 of the gestation. Doize et al. (13) have reported that one main advantage of the TR approach in small ruminants was that no other special transducer was needed, a regular linear transducer could be used for

examination.

b)Transabdominal Ultrasonography: Transabdominal ultrasonography can be preferred from the second trimester (>50 days) for pregnancy diagnosis in goats because after this period the gravid uterus started to descend into the cranio-ventral direction and TR ultrasonography becomes inadequate in this period (15). The TA ultrasonography can be used on animals when they are in standing position or layed on their backs (dorsal recumbency) and well restrained. Area of scanning can be chosen as ventral abdominal wall just in front of the udder and may be necessary to be hair-shaved before the examination. Sufficient ultrasonic gel can be applied to the ventral abdomen to improve the image quality. In a study by Amer (4), the TA ultrasonography with a 3.5-5mHz sector-array transducer was used for early pregnancy detection in goats. Amer (3) has reported that with 3.5mHz TA ultrasonography, fluid filled vesicles were reliably spotted from 24.7 ± 0.4 day onwards and fetal heart beats were first identified as late as 27.0 ± 0.6 date of gestation. Padilla-Rivas et al. (32) have reported that they predicted the pregnancy from day 26.4 onwards, using 3.5mHz linear array transducer transabdominally in Boer goats, and the foetal heart beat was firstly observed on day 33.1 in their study. Buckrell (10) has reported that pregnancy could be diagnosed between the 25-30th gestation days transabdominally from inguinal region in Saanen goats. Küplülü et al. (26) have used 5mHz B-mode real time ultrasonography transabdominally in their study between the 15th and the 38th gestation days in Saanen goats and they found that the 25th gestation day is the most accurate period for pregnancy diagnosis transabdominally. They also found that early periods (the 15, 19 and 20th gestation days) were inaccurate for pregnancy diagnosis transabdominally because the uterus was still located in the pelvic canal. Enginler et al. (14) reported that transabdominal ultrasonography was more difficult to perform than transrectal ultrasonography when used to detect the biparietal diameter and fetal sex on weekly examinations from the 10th to the 14th weeks of gestation in Saanen goat fetuses.

c)Transvaginal Ultrasonography: Transvaginal probe is not often a preferable tool in field conditions as it is expensive. As it is well known, transvaginal probe can also be used in large animals for ovum pick-up procedures. Koker et al. (25) have preferred transvaginal ultrasonography because of the risk of haemorrhage and luminal wall injury during TR ultrasonography in Saanen goats' pregnancy detection. B-mode real time scanner attached to an annular array sector of 5-7.5 mHz multi-frequency transvaginal probe to predict the pregnancy in Saanen goats have reported by them. Transvaginal examinations were performed with the animal in the normal standing position, with gel lubricated probe

covered by a disposable sheath and cleaned with a chlorhexidine solution prior each examination. They have introduced the probe into the vagina firstly at a 45 degree angle upward and then forward straight cranially. Pregnancy could be diagnosed when the gestational sac was observed as a circular or an elongated anechoic structure (≥ 2 cm in diameter) within the uterine cavity which was lining cranial to the urinary bladder. They found that transvaginal ultrasound scanning can diagnose early pregnancy in Saanen goats 7 week post mating. Aria et al. (5) have reported that transvaginal ultrasonography is easier than TA ultrasonography. They have found transvaginal ultrasonography was hygienic and safer than transrectal technique in small ruminants in their study conducted on 48 Massese sheep and on 3 goats.

4) Doppler Ultrasonography

In Doppler ultrasonography, transducer emits ultrasound waves; motionless structures reflect the sounds at the same frequency, whereas moving organ like foetal heart and pulsatile arteries reflects the sound in different frequency and then determined frequency variations converted into the audible sounds (2,11). When an ultrasound beam encounters a moving object towards the transducer this is known as positive Doppler shift (31). An object travelling away from the transducer, it leads reduced frequency and named as negative Doppler shift (31). Pregnancy diagnosis with doppler ultrasonography can include movements as an indication of pregnancy such as foetal heart beat, foetal circulation and foetal movements (42-44). Foetal blood flow is the most diagnostic feature. Foetal pulse which is faster than maternal pulse or foetal movements are all positive criteria for pregnancy (28,29). Colour Doppler, Power Doppler and Pulsed Doppler Systems have been used in small ruminant practices. Umbilical cord vessels, caudal cava vein and ductus venosus of the foetus could be investigated with doppler ultrasonography (1,33, 36,40).

a) Transabdominal Doppler Ultrasonography: After shaving of the abdomen, the transducer can be applied in front of the udder. The examination can be performed on the standing doe. The lubricated probe can be applied to the skin in the inguinal region across the abdomen cranial to pelvic brim. The ideal time has been reported as between 40 and 75 days of gestation (23).

b) Transrectal Doppler Ultrasonography: Transrectal doppler technique is superior to external technique as it allows to identify early pregnancy. Its best use has been reported as between 35 and 40 days post-breeding. Transrectal doppler technique allows us to diagnose pregnancy earlier than A scan technique (30). But accurate detection of fetal load can be

difficult with doppler ultrasonography (23).

Conclusion

Ultrasonography is still a routinely used technique to diagnose pregnancy in goats. As it is practical, harmless, easy and reliable method; it is highly recommended under field conditions especially where immediate determinations are required. In conclusion, the TR can be considered superior to the TA in small ruminants to detect pregnancy 4-5 days earlier than the TA route. But because of the early embryonic losses in goats, transrectal ultrasonography can be repeated to confirm the pregnancy until the 50th day of gestation.

In the TR examination pregnancy can be detected after second trimester; but, as the gravid uterus descends cranio-ventral direction, it is difficult to distinguish the parts of the foetus. Transvaginal ultrasonography in goats can be effective for early pregnancy assessment. Further studies are needed to determine the effectiveness of transvaginal route in pregnancy diagnosis in goats.

References

1. Acharya G, Erkinaro T, Makikallio K, Lappalainen T, Rasanen J. Relationships among doppler-derived umbilical artery absolute velocities, cardiac function, and placental volume blood flow and resistance in fetal sheep. *Am J Physiol-Heart C* 2003; 286: 1266-72.
2. Allen WE, Meredith MJ. Detection of proegnancy in the bitch: a study of abdominal palpation, A-Mode ultrasound and Doppler ultrasound techniques. *J Small Anim Pract* 1981; 22: 609-22.
3. Amer HA. Determination of first pregnancy and foetal measurements in Egyptian Baladi goats (*Capra hircus*). *Vet Ital* 2008; 44 (2): 429-37.
4. Amer HA. Ultrasonographic assessment of early pregnancy diagnosis, fetometry and sex determination in goats. *Anim Reprod Sci* 2010; 117: 226-31.
5. Aria G, Shau Z, Botta R, Giuliotti L, Rota A. Transvaginal echographic approach to early pregnancy diagnosis in small ruminants. *Ann Fac Med Vet Pisa* 2004; 57: 99-105.
6. Arthur GH, Noakes DE, Pearson H, Parkinson T. *Veterinary Reproduction and Obstetrics*. England: WB Saunders Company Ltd, 1996.
7. Atmaca NS. *Diagnostik Ultrasonografi*. İkinci Baskı. Ankara: 1989.
8. Baronet D, Vaillancourt D. Pregnancy diagnosis in goats by echotomography. *Med Vet Du Oueb* 1989; 19 (2): 67-73.

9. Bretzlaff K, Edwards J, Forrest D, Nuti L. Ultrasonographic determination of pregnancy in small ruminants. *Vet Med* 1993; 88: 12-24.
10. Buckrell BC. Application of ultrasonography in reproduction in sheep and goats. *Theriogenology* 1988; 29: 71-84.
11. Dawson LJ. Pregnancy diagnosis in goats. Fourteenth Annual Goat Field Day. 1999; Langston University-Langston.
12. Dinç DA, Alaçam E. Evcil hayvanlarda ultrason ile gebelik teşhisi. *Türk Vet Hek Bir Vak Derg* 1990; 2 (5): 11-3.
13. Doize F, Vaillancourt H, Carabin H, Belanger D. Determination of gestational age in sheep and goats transrectal ultrasonographic measurement of placentome. *Theriogenology* 1997; 48: 449-60.
14. Enginler SÖ, Özdaş ÖB, Sandal Aİ, Arıcı R, Ertürk E, Mohammed IF, Çınar EM, Gündüz MC, Doğan N, Baran A. Accuracy of ultrasonographic diagnosis of sex and effect of sex and birth type on biparietal diameter of Saanen goat fetuses. *SGRJ* 2013; 28: 10-5.
15. Erdogan G. Ultrasonic assessment during pregnancy in goats-a review. *Reprod Domestic Anim* 2012; 47: 157-63.
16. Ford EJH. Pregnancy toxæmia. Martin WB. ed. In: *Diseases of sheep*. London: Blackwell Scientific Publications, 1983; pp. 147-51.
17. Garcia A, Neary MK, Kelly GR, Pierson RA. Accuracy of ultrasonography in early pregnancy diagnosis in the ewe. *Theriogenology* 1993; 39: 847- 61.
18. Gonzales-Bulnes A, Pallares P, Vazquez MI. Ultrasonographic imaging in small ruminant reproduction. *Reprod Domestic Anim* 2010; 45: 9-20.
19. Gürbulak K, Pancarcı ŞM, Güngör Ö, Cihan K, Oral H, Kırmızıgül AH, Kamiloğlu N, Karapehlivan M, Duygu K. Kış döneminde doğuran Tuj koyunlarında uterus involüsyon süresi ve subklinik hipokalseminin involüsyon süresi üzerine etkisi. *Kafkas Univ Vet Fak Derg* 2005; 11(1): 55-9.
20. Haibel GK. Real time ultrasonic fetal head measurement and gestational age in dairy goats. *Theriogenology* 1988; 30 (6): 1053-57.
21. Haibel GK. Use of ultrasonography in reproductive management of sheep and goat herds. *Vet Clin North Am* 1990; 6: 597-613.
22. Hesselink JW, Taverne MAM. Ultrasonography of the uterus of the goat. *Vet Q* 1994; 16 (1): 41-5.
23. Ishwar AK. Pregnancy diagnosis in sheep and goats. a review. *Small Ruminant Res* 1995; 17: 37-44.
24. Kaspar B. Ultraschalluntersuchung bei ziegen: eine zuverlässige methode zur trachtigkeitsfeststellung. *Der Ziegenzüchter* 1989; 5: 8-12.
25. Koker A, Ince D, Sezik M. The accuracy of transvaginal ultrasonography for early pregnancy diagnosis in Saanen goats: A pilot study. *Small Ruminant Res* 2012; 105: 277-81.
26. Küplülü Ş, Vural R, Aslan S, Salmanoğlu R, Kılıçoğlu Ç, İzgür H. Saanen ırkı keçilerde erken gebeliğin B-mode real time ultrasonografi ile tanısı. *Ankara Üniv Vet Fak Derg* 1993; 40 (2): 220-30.
27. Lavoit MC, Taverna MAM, eds. The diagnosis of pregnancy and pseudopregnancy and the determination of foetal numbers of goats by means of real time ultrasound scanning. In: *Diagnostic ultrasound and animal reproduction*. Kluwer Academic Publishers, 1989; pp. 89.
28. Lindahl IL. Comparison of ultrasonic techniques for the detection of pregnancy in ewes. *J Reprod Fertil* 1969a; 18: 117-20.
29. Lindahl IL. Pregnancy diagnosis in dairy goats using ultrasonic Doppler instrument. *J Dairy Sci* 1969b; 52: 529-30.
30. Lindahl IL. Pregnancy diagnosis in ewe by intrarectal Doppler. *J Anim Sci* 1971; 32: 922-5.
31. Medan MS, Abd El-Aty AM. Advances in ultrasonography and its applications in domestic ruminants and other farm animals reproduction. *JAR* 2010; 1: 123-8.
32. Padilla-Rivas GR, Sohnrey B, Holtz W. Early pregnancy detection by real-time ultrasonography in Boer goats. *Small Ruminant Res* 2005; 58: 87-92.
33. Panarace M, Garnil C, Cane L, Rodriguez E, Medina M. Echo-Doppler ultrasonographic assessment of resistance and velocity of blood flow in the ductus venosus throughout gestation in fetal lambs. *Theriogenology* 2008; 70: 648-54.
34. Pierson RA, Kastelic JP, Ginther OJ. Basic principles and techniques for transrectal ultrasonography in cattle and horses. *Theriogenology* 1988; 29: 3-20.
35. Pieterse MC, Taverne MAM. Hydrometra in goats: Diagnosis with real time ultrasound and treatment with prostaglandins or oxytocin. *Theriogenology* 1986; 26: 813-21.

36. Reed KL, Chaffin DG, Anderson CF. Umbilical venous doppler velocity pulsations and inferior vena cava pressure elevations in foetal lambs. *Obstet Gynecol* 1996; 87: 617-20.
37. Reichle JK, Haibel GK. Ultrasonic biparietal diameter of second trimester pygmy goat fetuses. *Theriogenology* 1991; 35 (4): 689-94.
38. Santiago-Moreno J, Gonzalez-Bulnes A, Garcia-Lopez M, Lopez-Sebastian A. Diagnostico precoz de gestaion y determinacion del numero de embriones mediante ecografia transrectal en la cabra. *ITEA* 1995a; 91A: 37-43.
39. Santiago-Moreno J, Gonzalez-Bulnes A, Garcia-Lopez M, Lopez-Sebastian A. Valoracion de estadios precoces de gestacion en oveja y cabra mediante ecografia transrectal. *Invest Agr* 1995b; 10: 53-61.
40. Serin G, Gokdal O, Tarimcilar T, Atay O. Umbilical artery doppler sonography in Saanen goat fetuses during singleton and multiple pregnancies. *Theriogenology* 2010; 74: 1082-87.
41. Singh NS, Awande PG, Mishra OP, Nema RK, Mishra UK, Singh M. Accuracy of ultrasonography in early pregnancy diagnosis in Doe. *Asian Aust J Anim Sci* 2004; 17 (6): 760-68.
42. Trapp MJ, Slyter AL. Pregnancy diagnosis in the ewe. *J Anim Sci* 1983; 57: 1-15.
43. Wani GM. Ultrasonic pregnancy diagnosis in sheep and goats. *World Rev Anim Prod* 1981; 17 (4): 43-8.
44. Watt BR, Anderson GA, Campell IP. A comparison of six methods used for detecting pregnancy in sheep. *Aust Vet J* 1984; 61: 377-81.

Yazışma Adresi:

Dr. Sinem Özlem ENGİNLER
İstanbul Üniversitesi Doğum ve Jinekoloji Anabilim
Dalı Avcılar, 34320, İstanbul-Türkiye
Tel: 0 212 473 70 70-17137
E-posta: soapaydin@hotmail.com