



USE OF VENTRICULOPERITONEAL SHUNT RESERVOIR AS AN ALTERNATIVE TO LUMBAR PUNCTURE, CASE SERIES

Murat DUYAN^{1*}, Hakan ÇAKIN², Nafis VURAL³, Ali SARIDAŞ⁴

¹Antalya Training and Research Hospital, Department of Emergency Medicine, 07100, Antalya, Türkiye

²Akdeniz University, Faculty of Medicine, Department of Neurosurgery, 07070, Antalya, Türkiye

³Ereğli State Hospital, Department of Emergency Medicine, 42310, Konya, Türkiye


⁴Prof. Dr. Cemil Taşcıoğlu City Hospital, Department of Emergency Medicine, 34384, Istanbul, Türkiye


Abstract: Hydrocephalus is a common neurological disorder in both childhood and adulthood. Non-communicating hydrocephalus may occur due to obstruction of the cerebrospinal fluid (CSF) flow pathways by structural anomalies such as tumors, infections, adhesions, and developmental defects while communicating hydrocephalus might develop due to CSF absorption disorders or excess production. In symptomatic cases, treatment is divided into two approaches as medical and surgical. The most commonly used method in surgical treatment is the ventriculoperitoneal (VP) shunt system. The VP shunt system can have numerous advantages and complications and is expected to yield continuous and long-term solutions. One of its advantages is that CSF samples can be taken from the reservoir located on it. In cases suspected of intracranial infection but for whom Lumbar puncture (LP) cannot be performed, the shunt reservoir in the patient provides sufficient opportunity for CSF retrieval.


Keywords: Shunt tapping, Lumbar puncture, Emergency department, Hydrocephalus, Central nervous system infection


*Corresponding author: Antalya Training and Research Hospital, Department of Emergency Medicine, 07100, Antalya, Türkiye

E mail: drmuratduyan@gmail.com (M. DUYAN)

Murat DUYAN  <https://orcid.org/0000-0002-6420-3259>

Hakan ÇAKIN  <https://orcid.org/0000-0002-2635-4953>

Nafis VURAL  <https://orcid.org/0000-0002-3551-201X>

Ali SARIDAŞ  <https://orcid.org/0000-0002-2725-6001>

Received: November 09, 2022

Accepted: November 30, 2022

Published: January 01, 2023

Cite as: Duyan M, Çakin H, Vural N, Sarıdaş A. 2023. Use of ventriculoperitoneal shunt reservoir as an alternative to lumbar puncture, case series. *BSJ Health Sci*, 6(1): 172-174.

1. Introduction

In the emergency department (ED), it may be necessary to take CSF samples from patients for many different reasons: central nervous system and shunt infections, pseudotumor cerebri, and suspected subarachnoid hemorrhage (SAH). When LP cannot be performed due to various reasons such as intracranial space-occupying formation, increased intracranial pressure, infected or injured lumbar region skin tissue, obesity, previous lumbar region surgery or meningocele operations, puncture from the VP shunt reservoir is an effective, practical, less invasive and more comfortable method for both obtaining CSF samples and reducing intracranial pressure (Doherty and Forbes, 2014; Kazan and Çakin, 2015; Ozdol et al., 2019; Ferras et al., 2020).

Central nervous system infections, such as meningitis, encephalitis, and brain abscess, are uncommon but time-critical emergency department diagnoses (Dorsett and Liang, 2016). Between 1993 and 2008, in the United States, approximately 66000 ED patients per year were diagnosed with meningitis, with an incidence of 62 per 100000 visits (Takhar et al., 2012). The reported incidence of encephalitis of all etiologies ranges from 0.7 to 12.6 per 100000 adults and 10.5 to 13.8 per 100000 children (Solomon et al., 2012). The reported incidence of brain abscesses ranges from 0.4 to 0.9 cases per

100000 population, with a higher incidence reported in immunocompromised populations (Helweg-Larsen et al., 2012).

The incidence of hydrocephalus in the US ranges from one in 10,000 births to 32 cases, depending on the definition used and the population studied (Kahle et al., 2016). VP shunt is the most commonly used procedure for the treatment of hydrocephalus. VP shunts account for over 70% of diversion procedures (Khan et al., 2021).

2. Case Report

2.1. Case 1

A 54-year-old male patient was admitted to the emergency room with fever and generally poor health complaints. The patient, who has operated on for aneurysmatic SAH 2 years ago with a history of diabetes and hypertension, is fed through a gastrostomy catheter. There is a pressure sore in the lumbar area. There is a VP shunt, and the shunt pump (reservoir) is working.

Brain computerized tomography (CT) and thorax CT were requested. Operation material, VP shunt, and large ventricles were observed in the CT. On thorax CT, there was suspected pneumonic infiltration in the lower lobe of the left lung.

Since the lumbar area was unsuitable for patients with altered consciousness, a shunt reservoir was used to



obtain CSF samples to exclude central nervous system (CNS) infection. The sample was not compatible with the disease. The patient was hospitalized with a pre-diagnosis of pneumonia.

2.2. Case 2

A 58-year-old female patient who installed a shunt following the diagnosis of hydrocephalus six years ago, who was also bedridden, was admitted to the emergency service with a fever that did not fall for two days. On her physical examination, she exhibited confusion of consciousness, disorientation, and lack of cooperation, fever, and neck stiffness. Other system examinations were within acceptable limits. In her CT, the shunt system and previous multiple infarcts were observed.

Since the lumbar area with pressure sore was not suitable for CSF sample collection for CNS infection exclusion, the sample was obtained from the shunt reservoir. Consistent with the infection, CSF glucose was 61 mg/dl (simultaneous blood glucose 170 mg/dl) and CSF protein 777 mg/dl. The patient was admitted to the infection service with a pre-diagnosis of meningitis.

2.3. Case 3

Shunt insertion was conducted in a 77-year-old male patient diagnosed with normal pressure hydrocephalus 1.5 years ago. The patient was admitted with fever, malaise, and fluctuations in the level of consciousness. General condition is within moderate limits; he was partially cooperative and disorientated with no neck stiffness. The shunt reservoir was filled by applying pressure on it. In CT, chronic ischemic changes were observed in shunt catheter.

CSF sample was taken from the shunt reservoir of the patient who did not give his consent for LP. The sample was not found to be compatible with the infection. The patient was admitted to the neurology clinic for further examination.

During the follow-up in all three cases, no complications related to the shunt developed after the procedure.

3. Discussion

VP shunt usually consists of the short (ventricular) catheter, shunt valve, and long (peritoneal) catheter (URL1). The reservoir is usually located near the valve. The cranial catheter is fed into the lateral ventricles with "a burr hole" opened in the skull. This catheter is often combined with the valve system in the parietooccipital area under the skin, which regulates the amount of CSF to be evacuated by pressure adjustment. On the other end of the valve system, a peritoneal catheter is connected under the skin, connected to the anterior part of the abdomen, and then into the peritoneum.

When CSF sampling or extraction is required, the shunt reservoir is palpated, which exhibits subcutaneous swelling in the parietooccipital region and thus can be palpated, collapses when pressure is applied to it with fingertips, but rises as filled with CSF again within seconds. If there is any doubt about its location, a plain radiograph can be taken (Figure 1).

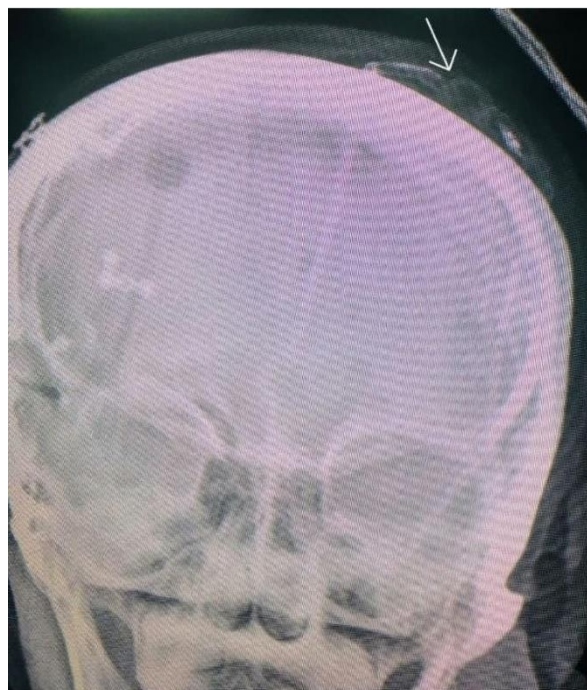

Figure 1. Ventriculoperitoneal shunt reservoir on plain skull radiography (white arrow).

The area is disinfected with antiseptic agents at least three times over the skin using sterile sponges. The needle section of the insulin injector, which is 26 gauge, is placed on the tip of the 10cc injector barrel according to the required CSF amount required to be drained. The insulin injector needle is advanced in a Z-shape under the unshaved skin next to the swelling of the reservoir, piercing the silicon surface of the reservoir and applying negative pressure to provide CSF drainage. Due care should be taken in order not to cause intracranial hypotension with excessive drainage.

Drainage is obtained according to the amount of CSF needed. It is a painless, fast, and safe method requiring local anesthesia. LP complications such as CSF fistula, headache, epidural bleeding, and herniation syndromes can also be avoided.

LP is a vital intervention strategy in the diagnosis and treatment stages of neurological and infective diseases throughout medicine. To avoid damaging the valve part of the shunt, the classic recommendation is to teach the shunt tap to control the life-threatening intracranial pressure increase or by emergency physicians in the absence of a brain and neurosurgeon (Ladde, 2020).

On the other hand, the fact that this sampling method is free from such detrimental effects as epidural-subdural hemorrhages, headaches, and intracranial hypotension due to BSF fistula, skin infections, inappropriate lumbar region structure, and most importantly, death due to tonsillar herniation, which might develop about LP procedure, are some advantages of using a shunt. In patients with VP shunt, the existence of an alternative method such as CSF removal from the shunt reservoir can be considered as turning the existing situation into an opportunity. It is a minimally invasive method, which

does not require any initial condition such as local anesthesia and LP; it is also is a fast procedure, which is an effective and practical method to reach and diagnose CSF, especially in emergency services.

4. Conclusion

As a result, in a patient with a VP shunt, tapping from the reservoir to obtain CSF is a practical method preferred in the emergency department, which has significant advantages over LP.

Author Contributions

The percentage of the author(s) contributions is present below. All authors reviewed and approved final version of the manuscript.

	M.D.	H.Ç.	N.V.	A.S.
C	50	20	15	15
D	50	20	20	10
S	50	20	20	10
DCP	50	20	30	10
DAI	50	20	20	10
L	50	20	20	10
W	50	20	20	10
CR	50	30	15	15
SR	50	20	20	10
PM	50	20	20	10
FA	50	20	20	10

C=Concept, D= design, S= supervision, DCP= data collection and/or processing, DAI= data analysis and/or interpretation, L= literature search, W= writing, CR= critical review, SR= submission and revision, PM= project management, FA= funding acquisition.

Conflict of Interest

The authors declared that there is no conflict of interest.

Ethical Approval/Informed Consent

Written an informed consent form was obtained from the patients for the case presentation and necessary information was given to the family.

References

- Doherty CM, Forbes RB. 2014. Diagnostic lumbar puncture. *Ulster Med J*, 83(2): 93-102.
- Dorsett M, Liang SY. 2016. Diagnosis and treatment of central nervous system infections in the emergency department. *Emerg Med Clin North America*, 34(4): 917-942. DOI: 10.1016/J.EMC.2016.06.013.
- Ferras M, McCauley N, Stead T, Ganti L, Desai B. 2020. Ventriculoperitoneal shunts in the emergency department: A review. *Cureus*, 12(2): e6857. DOI: 10.7759/CUREUS.6857.
- Helweg-Larsen J, Astradsson A, Richhall H, Erdal J, Laursen A, Brennum J. 2012. Pyogenic brain abscess, a 15 year survey. *BMC Infect Diseases*, 12: 332. DOI: 10.1186/1471-2334-12-332.
- Kahle KT, Kulkarni AV, Limbrick DD, Warf BC. 2016. Hydrocephalus in children. *Lancet*, 387(10020): 788-799. DOI: 10.1016/S0140-6736(15)60694-8.
- Kazan S, Çakin H. 2015. Mechanical complications of shunt in hydrocephalus. *Turkiye Klin Neurosurg*, 5(1): 59-63.
- Khan B, Hamayun S, Haqqani U, Khanzada K, Ullah S, Khattak R, Zadrán N, Bibi Z, Khan AW. 2021. Early complications of ventriculoperitoneal shunt in pediatric patients with hydrocephalus. *Cureus*, 13(2): e13506. DOI: 10.7759/CUREUS.13506.
- Ladde JG. 2020. Cardiovascular disease. in: Tintinalli JE, Ma OJ, Yealy DM, Meckler GD, Stapczynski JS, Cline DM, Thomas SH edition. *Emergency medicine: A comprehensive study guide*. McGraw-Hill Education, Columbus, US, pp: 2176.
- Ozdol C, Gediz T, Basak AT, Basak N, Aghayev K. 2019. Shunt tapping versus lumbar puncture for evaluating cerebrospinal fluid infections in a pediatric population. *Turkish Neurosurg*, 29(2): 275-278. DOI: 10.5137/1019-5149.JTN.24714-18.1.
- Solomon T, Michael BD, Smith PE, Sanderson F, Davies NWS, Hart IJ, Beeching NJ. 2012. Management of suspected viral encephalitis in adults-Association of British Neurologists and British Infection Association National Guidelines. *Infection*, 64(4): 347-373. DOI: 10.1016/J.JINF.2011.11.014.
- Takhar SS, Ting SA, Camargo CA, Pallin DJ. 2012. U.S. emergency department visits for meningitis, 1993-2008. *Acad Emerg Med*, 19(6): 632-639. DOI: 10.1111/J.1553-2712.2012.01377.X.
- URL1: <https://texasnasc.com/?s=ventriculoperitoneal> (access date: August 16, 2022).