

COMPARISON OF DIRECT AND INDIRECT COSTS OF MAGNETIC RESONANCE AND COMPUTED TOMOGRAPHY IN THE EVALUATION OF INCIDENTAL ADRENAL MASSES

İnsidental Adrenal Kitlelerin Değerlendirilmesinde Manyetik Rezonans ve Bilgisayarlı Tomografinin Direkt ve Dolaylı Maliyetlerinin Karşılaştırılması

Mutlu GÜNEŞ¹ 

¹ University of Health Sciences, Bursa Yüksek İhtisas Training and Research Hospital, Division of Endocrinology Diabetes and Metabolic Diseases, BURSA, TÜRKİYE

ABSTRACT

Objective: It was planned to compare the direct and indirect costs of computed tomography (CT) and magnetic resonance (MR) methods in the differentiation of adrenal adenoma and non adenoma.

Material and Methods: CT, MR, pathology, laboratory and other information of the patients were obtained from the patient files. Radiological examination and unilateral laparoscopic adrenalectomy cost information was obtained from the accounting department. For cost calculation; the scenario was used in which 500 patients were referred equally to CT and MR, individuals diagnosed with non-adenoma were referred to the operation after the first control, individuals diagnosed with adenoma were followed, and standard follow-up was done every 6 months for 4 years.

Results: A total of 31 patients (8 males and 23 females) were eligible for the study. The mean age of the patients was 48.1±17.7 years. In the CT group, an excess cost of 609,0 ₺ per person for 1 year and 2435,9 ₺ per person for 4 years was incurred. In the diagnosis of adenoma and non-adenoma, CT was inaccurate in 24.4% of patients, whereas MR was inaccurate in 5.2%. When used for the diagnosis of pheochromocytoma, it was found that in the CT group, 609,0 ₺ per person for 1 year and 2435,9 ₺ per person for 4 years resulted in an excess cost, whereas CT was erroneous in 17.6% of patients and MR in 15.8% of patients. In the diagnosis of malignancy, in the CT group, an excess cost of 522,2 ₺ per person for 1 year and 2088,7 ₺ per person for 4 years was incurred. It was determined that correct decision could not be made in 33.2% of the patients in the CT group and in 5.8% of the patients in the MR group.

Conclusion: The use of contrast-enhanced MR in patients of adrenal masses reduces unnecessary interventions and the resulting expenditures.

Keywords: Adrenal adenoma, computed tomography, magnetic resonance

ÖZ

Amaç: Bilgisayarlı tomografi (BT) ve manyetik rezonans (MR) yöntemlerinin adrenal adenom ve non adenom ayırımında direkt ve dolaylı maliyetlerinin karşılaştırılması planlanmıştır.

Gereç ve Yöntemler: Hastaların BT, MR, patoloji, laboratuvar ve diğer bilgileri hasta dosyalarından elde edildi. Sosyal Güvenlik Kurumu'nun kontrastlı BT için 170 Türk Lirası (₺), kontrastlı MR için 202 ₺, tek taraflı laparoskopik sürrenalektomi için 18036 ₺ ödeme yaptığı fatura bölümünden öğrenildi. Maliyet hesaplaması için, 500 hastanın eşit olarak BT'ye ve MR'a yönlendirildiği, non adenom tanısı alanların ilk kontrol sonrası operasyona yönlendirildiği, adenom tanısı alanların ise takip edildiği; standart takibin 4 yıl boyunca 6 ayda bir yapıldığı senaryosu kullanıldı.

Bulgular: Çalışmaya uygun olan 8 erkek ve 23 kadın olmak üzere 31 hasta tespit edildi. Hastaların yaş ortalaması 48.1±17.7 idi. BT kolunda 1 yıl için kişi başı 609,0 ₺ fazla, 4 yıl için kişi başı 2435,9 ₺ maliyet oluşmaktadır. Adenom ve non adenom tanısında BT'nin hastaların %24.4'ünde, MR'ın ise hastaların %5.2'sinde hatalı karar verdiği görüldü. Feokromositoma tanısı için kullanıldığında BT'nin 1 yıl için kişi başı 609,0 ₺; 4 yıl için kişi başı 2435,9 ₺ fazla maliyet oluşturduğu, buna karşın BT'nin hastaların %17.6'sında, MR'ın ise hastaların %15.8'inde hatalı karar verdiği tespit edildi. Malignite tanısında BT kolunda 1 yıl için kişi başı 522,2 ₺, 4 yıl için kişi başı 2088,7 ₺ fazla maliyet oluşmaktadır. BT grubunda hastaların %33.2'sinde, buna karşılık MR grubunda %5.8'inde doğru karar verilemediği saptandı.

Sonuç: Endokrinoloji polikliniğine yönlendirilen adrenal kitlelerin değerlendirilmesinde kontrastlı MR kullanılması gereksiz müdahaleleri ve bundan kaynaklı harcamaları azaltmaktadır.

Anahtar Kelimeler: Adrenal adenom, bilgisayarlı tomografi, manyetik rezonans



Correspondence / Yazışma Adresi:

University of Health Sciences, Bursa Yüksek İhtisas Training and Research Hospital, Division of Endocrinology Diabetes and Metabolic Diseases, BURSA, TÜRKİYE

Phone / Tel: +905056533953

Received / Geliş Tarihi: 09.12.2022

Dr. Mutlu GÜNEŞ

E-mail / E-posta: drmutlugunes@gmail.com

Accepted / Kabul Tarihi: 29.03.2023

INTRODUCTION

The increase in the frequency of use of imaging methods in daily practice has led to a higher incidence of incidental adrenal masses. It has been reported that the frequency of adrenal adenoma in the community is 3.5% (1), and its frequency increases up to 7% with age (2). The incidence of primary adrenal cancer in adrenal adenomas is approximately 5% (3).

Evaluation of detected adrenal masses consists of two basic steps; the first step is to determine whether there is hormone hypersecretion which can be assessed by cortisol, aldosterone and catecholamine levels (4).

The second step in the evaluation of detected adrenal masses; is the distinction between adenoma and non-adenoma. Primary adrenal cancer, metastases, lymphoma, pheochromocytoma, and inflammatory processes are radiologically defined as non-adenoma due to their low fat content (5). International guidelines generally recommend CT for the detection of non-adenomas because of its effectiveness and low cost (4). It is suspected in terms of malignancy that the detected adrenal lesions have irregular border, inhomogeneous structure, calcification, mass diameter >6 cm, a "washout" of contrast after 15 min of less than 40% and hounsfield unit (HU) value >10 on CT findings (4).

There are few studies comparing the efficacy of CT and MR in the differentiation of pathologically confirmed adrenal lesions from adenoma and non-adenoma (6,7). In addition, studies evaluating the direct and indirect costs of the preferred imaging method and screening tests are much less (8).

CT and MR costs are close in our country. For this reason, it is planned to compare the direct and indirect costs of contrast-enhanced CT and contrast-enhanced MR imaging methods over a 4-year period in the differentiation of adrenal lesions referred to the endocrinology outpatient clinic.

MATERIALS AND METHODS

Patients who applied to the endocrinology, metabolism and diabetes clinics between January 2016 and June 2022 were searched through the hospital database. A

total of 821 patients diagnosed with adrenal adenoma, who met the criteria and whose file information could be obtained, were identified. The present study was approved by the ethics committee of the Health Sciences University, Bursa Yüksek İhtisas Training and Research Hospital (2011-KAEK-25 2022/02-11). CT, MR, pathology, laboratory and other information of the patients were obtained from the patient files. For cost calculation, social health insurance (SHI) payment information for the year 2022 was obtained from the accounting department; CT with contrast was 170 Turkish Lira (₺), MR with contrast was 202 ₺ and the package price of unilateral laparoscopic adrenalectomy was 18036 ₺.

For price calculation; it is stated that 500 adenoma patients were referred equally to CT and MR, and there was no data on how many of those diagnosed with non-adenoma were referred for the operation at the 2nd or 3rd follow-up, after the 1st control. The scenario was used, in which those diagnosed with adenoma were followed, and standard follow-up was done every 6 months for 4 years.

IBM® SPSS Statistics 20 program was used to compare the data. After the normal distribution was determined, the independent samples "t" test was performed for the data showing normal distribution. A $p < 0.05$ was considered statistically significant.

RESULTS

General features

31 patients, 8 men and 23 women, who were operated and whose file information was obtained, were identified. The mean age of the patients was 48.1 ± 17.7 years, the mean age was 44.1 ± 25.2 years in those diagnosed with non-adenoma, and 50.1 ± 13.1 years in those diagnosed with adenoma ($p > 0.05$). The largest tumor (TM) diameter was found to be 49.5 ± 35.0 mm in the whole group, the largest TM diameter was 72.1 ± 22.4 mm in the non-adenoma group, and the largest TM diameter was 38.7 ± 30.9 mm in the adenoma group ($p = 0.004$). As radiological examination, 19 patients

were evaluated with MR, 18 patients with CT, and 6 patients were evaluated with both CT and MR.

Cost calculation in the differentiation of adenoma and non-adenoma;

In the MR group, radiological examination costs 653672 ₺ in 4 years for 500 people, and in the CT group, radiological examination costs 425000 ₺ in 4 years for 500 people. Due to the use of MR, the cost of radiological examination for 4 years is 457,3 ₺, and the annual cost is 114,3 ₺ per person. In addition, when the cost is calculated based on the situation in which non-adenoma patients are referred to adrenalectomy, the

total cost is 3402360 ₺ in the MR group and 4849000 ₺ in the CT group. In the CT group, an extra cost of 2893,3 ₺ per person for 4 years and 723,3 ₺ per person for 1 year is incurred. When the excess radiological cost is deducted, an extra cost of 2435,9 ₺ per person for 4 years and 609,0 ₺ for 1 year per person occurs in the CT group.

In addition to the high cost of using CT and MR as a radiological examination, the correct decision could not be made in 122 (24.4%) of 500 patients in the CT group and in 26 (5.2%) of 500 patients in the MR group.

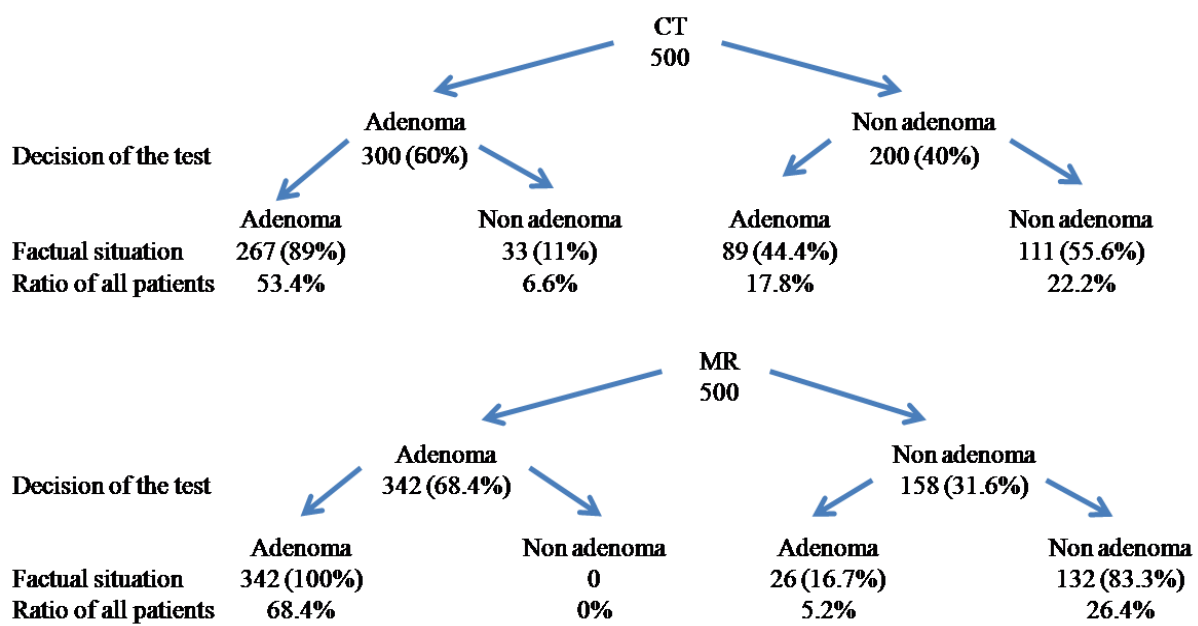


Figure 1: Decision of the test and factual situation for the diagnosis of adenoma and non adenoma, assuming that 500 people are referred equally to MR and CT

Cost calculation for the diagnosis of heochromocytoma

In the MR group, radiological examination costs 653672 ₺ in 4 years for 500 people, and in the CTgroup, radiological examination costs 404600 ₺ in 4 years for 500 people. Due to the use of MR, the cost of radiological examination for 4 years is 498,1 ₺ and the annual cost is 124,5 ₺ per person. In addition, in non-adenoma patients referred to adrenalectomy, the total cost is 2745560 ₺ in the MR group and 5099140 ₺ in the

CT group. In the CT group, an extra cost of 4707,2 ₺ per person for 4 years and 1176,8 ₺ per person for 1 year is incurred. When the excess of radiological cost is deducted, an extra cost of 4209 ₺ per person for 4 years and 1052,3 ₺ per person for 1 year occurs in the CT group.

In addition to the high cost of using CT as a radiological examination, the correct decision could not be made in 88 (17.6%) of 500 patients in CT group, and 79 (15.8%) of 500 patients in the MR group.(Figure 2)

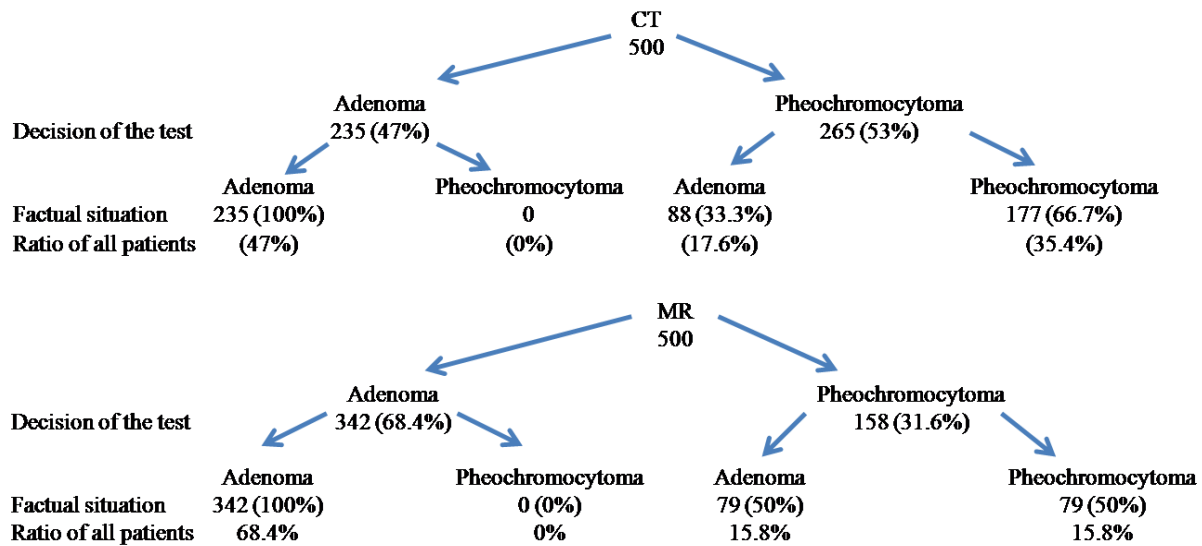


Figure 2: Decision of the test and factual situation for the diagnosis of pheochromocytoma, assuming that 500 people are referred equally to MR and CT

Cost calculation for the diagnosis of malignant mass

In the MR group, radiological examination cost is 718312 ₺ in 4 years for 500 people, while in the CT group, 493000 ₺ radiological examination costs are incurred in 4 years for 500 people. Due to the use of MR, the cost of radiological examination for 4 years is 450,6 ₺, and the annual cost is 112,7 ₺ per person. In addition, in non-adenoma patients referred to adrenalectomy, the total cost is 2745560 ₺ in the MR group and 4015200 ₺

in the CT group. In the CT group, an extra cost of 2539,3 ₺ per person for 4 years and 634,8 ₺ per person for 1 year is incurred. When the excess radiological cost is deducted, in the CT group 2088,7 ₺ for 4 years and 522,2 ₺ for 1 year excess cost was detected per person. In addition to the high cost of using CT as a radiological examination, the correct decision could not be made in 166 (33.2%) of 500 patients in CT group, and 29 (5.8%) of 500 patients in the MR group.

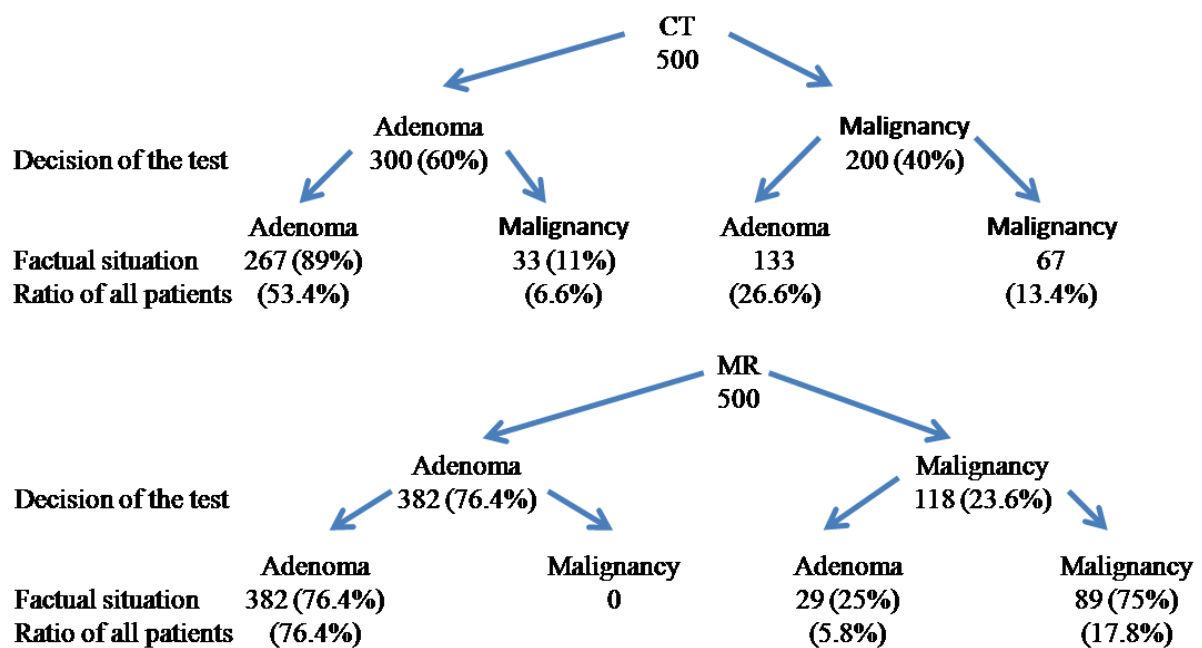


Figure 3: Decision of the test and factual situation for the diagnosis of primary or secondary adrenal malignancy, assuming that 500 people are referred equally to MR and CT

DISCUSSION

In the light of our study, it is clearly seen that contrast-enhanced CT is insufficient in the differentiation of adenoma and non-adenoma adrenal lesions referred to the endocrinology outpatient clinic in conditions where the costs are close to each other, and this situation will increase indirect costs such as unnecessary adrenalectomy and hospitalization. If there is a significant difference between CT and MR costs; it seems more appropriate to evaluate with contrast-enhanced MR before adrenalectomy and in case of clinical and radiological incompatibility.

Differentiation of adrenal adenoma and non-adenoma with CT is basically based on HU values in the unenhanced, portal phase and late series (9). The HU values in the unenhanced series are the most commonly used to differentiate between adrenal adenoma and non-adenoma, with a sensitivity of 0.96 and a specificity of around 0.73 (6, 10-12). In non-contrast series, if the HU value is below 10, adenoma is diagnosed (10-12), but it is not easy to distinguish between adenoma and non-adenoma with HU values >10 (6). In order to correct this situation, the absolute and relative contrast washout ratio, which is calculated according to the HU value in the early and late portal phase, is examined (9). However, despite all these, the reliability of CT in the distinction between adenoma and non-adenoma is not at the required level (9). The situation is slightly better in contrast-enhanced MR. In their study, Inan et al. found the sensitivity of contrast-enhanced MR as 93% and the specificity as 100% (13). However, MR is a more expensive and time-consuming technique than CT. In our study, it was observed that in 166 (33.2%) of 500 patients an incorrect decision was made in the case of using CT as a radiological examination, whereas in 29 (5.8%) of 500 patients an incorrect decision was made in the case of using MR. Advanced evaluation is required in patients who are referred to the endocrinology outpatient clinic with suspected adrenal non-adenoma; requesting contrast-enhanced CT as the second examination to distinguish between adenoma and non-adenoma will cause the patient to receive

unnecessary re-radiation and unnecessary adrenalectomy at a higher rate than MR. In addition, considering that patients should be followed for at least 4 years, MR imaging seems to be more appropriate in terms of decision-making, since it does not contain radiation in this process.

When the Turkish digital database was searched, we could not find any study comparing the direct and indirect costs of CT and MR in the diagnosis of adrenal adenoma and non-adenoma, but there may be studies that are not included in the index. Dwamena et al. evaluated the cost-effectiveness of nine different diagnostic methods, including non-contrast CT, chemical shift MR, and I131-6 β -iodomethylnorcholesterol (NP-59) scintigraphy in their analysis, and they found that a cut-off value of HU<10 in non-contrast CT was accepted as adenoma, the cost/effectiveness of CT and MR was similar, and NP-59 scintigraphy was the most cost-effective method (14). In their analysis, they determined that the MR was more reliable than CT, but CT was more cost/effective CT (14). Unlike our study, there is a significant difference between the prices of CT and MR in the studies of Dwamena et al. (14). In the studies of Lumachi et al.(15), it is seen that the price of CT is 120 euro (€) and the price of MR is 450 euro (15). In this study, the sensitivity of CT was found to be 80-85%, specificity 65-70%, price/effect ratio 1.46; the sensitivity of MR was found to be 90-95%, specificity 80-85%, and price/effect ratio 4.89 (15). The ratio of MR price/CT price is 3.75, MR price impact ratio/CT price/effect ratio is 3.35, in this case, we can say that MR makes more accurate decision in case of equal price (15). The price difference between them is almost 4 times. Although there is such a price difference, CT is generally preferred because the diagnostic accuracy does not differ from each other at the same rate (15). In our country, the price difference between MR and CT is not very significant, which leads to questioning the indirect costs caused by the diagnostic power of CT and MR.

Weaknesses of the study; firstly, the study population is very small, larger-scale studies will contribute to the enlightenment of the subject. Another weakness is that the follow-up status of the patients who were not referred for the operation is not known. With this information, a more accurate cost-effectiveness analysis can be made. Since the study design was retrospective, the number of patients to be enrolled was not calculated in prior, and since patient information was obtained from patient files, no comparison could be made regarding the technical methods used.

In our country, contrast-enhanced MR instead of CT for further radiological evaluation and follow-up in patients referred to the endocrinology outpatient clinic for adenoma and non-adenoma examination, contributes to lower the total costs by reducing unnecessary interventions.

*Conflicts of Interest:*The author have indicated no conflicts of interest regarding the content of this article.

*Ethics Committee Approval:*The present study was approved by the ethics committee of the Health Sciences University, Bursa Yuksek Ihtisas Training and Research Hospital (2011-KAEK-25 2022/02-11).

*Funding statement :*No allowance or funding was received for the costs of the research. The expenses of the study were covered by the researchers

REFERENCES

1. Herrera MF, Grant CS, van Heerden JA, Sheedy PF, Ilstrup DM. Incidentally discovered adrenal tumors: an institutional perspective. *Surgery*. 1991;110(6):1014-21
2. Herra MF, Pantoja JP, Espagna N. Adrenal incidentalomas. In: Linos D, van Heerden JA, eds. *Adrenal glands: diagnostic aspects and surgical therapy*. Berlin: Springer-Verlag. 2005;231-44
3. Young Jr WF. Management approaches to adrenal incidentalomas. A view from Rochester, Minnesota. *Endocrinol Metab Clin North Am*. 2000;29(1):159-85
4. Nieman LK. Approach to the patient with an adrenal incidentaloma. *J Clin Endocrinol Metab*. 2010 Sep;95(9):4106-13.
5. Ghanem N, Althoefer C, Thürl C, Bley T, Langer M. Computertomographie und Magnetresonanztomographie in der Differentialdiagnose von Nebennierenraumforderungen [CT and MRI in the differential diagnosis of lesions of the adrenal gland]. *Med Klin (Munich)*. 2004;99(8):447-52.
6. van Erkel AR, van Gils AP, Lequin M, Kruitwagen C, Bloem JL, Falke TH. CT and MR distinction of adenomas and nonadenomas of the adrenal gland. *J Comput Assist Tomogr*. 1994;18(3):432-8.
7. Schieda N, Alrashed A, Flood TA, Samji K, Shabana W, McInnes MD. Comparison of Quantitative MRI and CT Washout Analysis for Differentiation of Adrenal Pheochromocytoma From Adrenal Adenoma. *AJR Am J Roentgenol*. 2016;206(6):1141-8
8. Kievit J, Haak HR. Diagnosis And Treatment Of Adrenal Incidentaloma: A Cost-Effectiveness Analysis. *Endocrinology and Metabolism Clinics of North America*. 2000;29(1):69-90
9. Wang X, Li K, Sun H, Zhao J, Zheng L, Zhang Z, Bai R, Zhang G. Differentiation between adrenal adenomas and nonadenomas using dynamic contrast-enhanced computed tomography. *Onco Targets Ther*. 2016;9:6809-17.
10. Lee M, Hahn P, Papanicolaou N, et al. Benign and malignant adrenal masses: CT distinction with attenuation coefficients, size and observer analysis. *Radiology*. 1991;179(2):415-8.
11. Singer AA, Obuchowski NA, Einstein DM, Paushter DM. Metastasis or adenoma? Computed tomographic evaluation of the adrenal mass. *Cleveland Clin J Med*. 1994;61(3):200-5.
12. Korobkin, M., Brodeur, F. J., Yutzy, G. G., Francis, I. R., Quint, L. E., Dunnick, N. R., et al. Differentiation of Adrenal Adenomas from Nonadenomas using CT Attenuation values. *Am J Roentgenol*. 1996;166(3):531-6.

13. Inan N, Arslan A, Akansel G, Anik Y, Balci NC, Demirci A. Dynamic contrast enhanced MRI in the differential diagnosis of adrenal adenomas and malignant adrenal masses. *Eur J Radiol.* 2008;65(1):154-62
14. Dwamena BA, Kloos RT, Fendrick AM, Gross MD, Francis IR, Korobkin MT, et al. Diagnostic evaluation of the adrenal incidentaloma: decision and cost-effectiveness analyses. *J Nucl Med.* 1998;39(4):707-12.
15. Lumachi F, Basso SM, Borsato S, Tregnaghi A, Zucchetta P, Marzola MC, et al. Role and cost-effectiveness of adrenal imaging and image-guided FNA cytology in the management of incidentally discovered adrenal tumours. *Anticancer Res.* 2005;25(6C):4559-62.