

Dapsone Induced Aplastic Anemia ***Dapson Kaynaklı Aplastik Anemi***

¹Hava Üsküdar Teke, ²Çiğdem Karakükcü, ³Hediye Uğur, ⁴Salih Tokmak, ⁵Ali Ünal
¹Eskişehir Osmangazi University, Faculty of Medicine, Department of Hematology, Eskişehir, Türkiye
²Kayseri Education and Research Hospital, Biochemistry Division
³Kayseri Education and Research Hospital, Internal Medicine Division, Kayseri, Türkiye
⁴Eskişehir Osmangazi University, Medical School, Internal Medicine Division, Eskişehir, Türkiye
⁵Erciyes University Medical School, Hematology Division, Kayseri, Türkiye

Abstract: Dapsone is a sulfone antibiotic, which has anti-inflammatory and anti-bacterial effects and used in leprosy, intractable skin lesions, rheumatologic diseases like systemic lupus erythematosus and *Pneumocystis jiroveci* prophylaxis. Aplastic anemia is an uncommon adverse hematologic effect in patients treated with dapsone. We present a 59 years old female patient which developed aplastic anemia, direct coombs positively and methemoglobinemia because of dapsone. Before starting dapsone treatment, side effect profile must be discussed thoroughly; periodic CBC must be performed before and after the treatment, even without any patient complaints.

Keywords: Dapsone, aplastic anemia, hemolysis

Üsküdar Teke H. Karakükcü Ç. Uğur H. Tokmak S. Ünal A. (2017) Dapsone Induced Aplastic Anemia, *Osmangazi Journal of Medicine*, 39(1), 90-93. doi: 10.20515/otd.40882

Özet: Dapsone, romatolojik hastalıklardan sistemik lupus eritematozis ve *Pneumocystis jiroveci* profilaksisi ile lepra ve inatçı cilt lezyonlarında kullanılan, anti-inflamatuvar ve antibakteriyel özelliklere sahip bir sülfon antibiyotiktir. Aplastik anemi, dapsonla tedavi edilen hastalarda nadir görülen hematolojik bir yan etkidir. Bu yazıda dapsona bağlı aplastik anemi, direkt coombs pozitifliği ve methemoglobinemi gelişen 59 yaşındaki kadın hastayı sunduk. Dapson başlamadan önce ilacın yan etkileri dikkatli bir şekilde gözden geçirilmeli, ilacı başlamadan önce ve başladıktan sonra periyodik olarak tam kan sayımı yapılmalıdır.

Anahtar Kelimeler: Dapson, aplastik anemi, hemoliz

Üsküdar Teke H. Karakükcü Ç. Uğur H. Tokmak S. Ünal A. (2017) Dapson Kaynaklı Aplastik Anemi, *Osmangazi Tıp Dergisi*, 39(1), 90-93. doi: 10.20515/otd.40882

1. Introduction

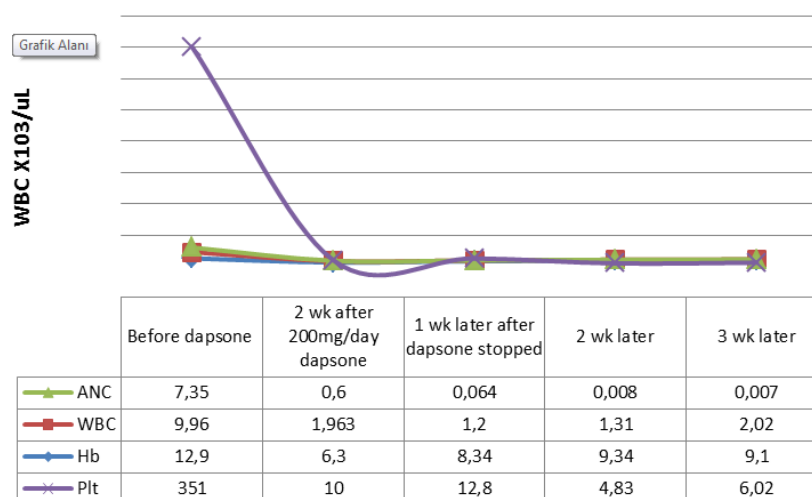
Dapsone (diaminodiphenylsulfone) is a sulfone antibiotic, which has anti-inflammatory and anti-bacterial effects and used in leprosy, intractable skin lesions such as dermatitis herpetiformis, and rheumatologic diseases such as systemic lupus erythematosus, rheumatoid arthritis and *Pneumocystis jiroveci* prophylaxis. Most frequent adverse effects of dapsone are methemoglobinemia and hemolytic anemia. Most frequent hematologic side effect is agranulocytosis (1-3). On rare occasions, it may cause fatal course aplastic anemia (4,5).

In this case, we present a patient who has dermatitis not response to medical treatment, which developed aplastic anemia because of dapsone.

2. Case Presentation

A 59 years old female, suffering from itchiness throughout the body for two and a half years, appeared our dermatology clinic. On physical exam, multiple desquamations in arms and legs, xerosis on arms were determined. Dermographism was negative and neither lymphadenopathy nor hepatosplenomegaly was detected. All the secondary reasons for itchiness were ruled out. One-hundred milligram/day dapsone was started to the patient because the patient's complaints did not diminish with urea creme, levocetirizine, hydroxyzine and fucidic acid+betamethasone valerate creme. Pre-treatment Complete Blood Count (CBC) values were as follows: hemoglobin (Hb): 12.9 g/dL, white blood cells (WBC): $9.960 \times 10^3/\mu\text{L}$, absolute neutrophil counts (ANC): $7.350 \times 10^3/\mu\text{L}$, absolute eosinophil counts (AEC) $0.280 \times 10^3/\mu\text{L}$, platelets: $351 \times 10^3/\mu\text{L}$. After one month of dapsone therapy, patient's complaints decreased minimally and the doses have been doubled. No extra medical or

herbal medicine therapy was given to the patient. After 15 days of 200 mg/day dapsone therapy, patient appeared our emergency service with fatigue, bruises throughout the body and fever. On physical exam, there was no loss of consciousness but $38,5^{\circ}\text{C}$ fever and crepitant rales in lower zones of left lung in auscultation detected. CBC values were as follows: Hb: 6.3 gr/dL, MCV: 98.4 fL, WBC: $1.963 \times 10^3/\mu\text{L}$, ANC: $0.6 \times 10^3/\mu\text{L}$, platelets: $10 \times 10^3/\mu\text{L}$, c-reactive protein: 10 mg/dL, erythrocyte sedimentation rate: 35 mm/h. Infiltration on the left lower zone was detected in chest radiogram. Patient was hospitalized because of pancytopenia and febrile neutropenia. Vitamin B12, folic acid, TSH, fT4, serum iron levels, serum iron binding capacity, ferritin, ANA, antids-DNA, Ig G, A, M, LDH, uric acid, were normal, reticulocyte count was reduced. Tests for hepatitis A, B, C, HIV, EBV, CMV, *Salmonella* and *Brucella* were negative. We performed direct coombs test for "dapsone induced hemolytic anemia" initial diagnosis. Direct Coombs test was positive (+4). Methemoglobin levels were 2.7% (normal range: 0-1%) Bone marrow aspiration and biopsy were performed. Aspiration was hypocellular. In biopsy; cellularity was 10% and distinctive decline in all lineages was determined. Biopsy was consistent with aplastic anemia. Recurrent thrombocyte/erythrocyte transfusions and G-CSF injections were given to the patient for pancytopenia. Meropenem, linezolid, caspofungin and acyclovir were given to the patient for febrile neutropenia. Three weeks after discontinuing dapsone treatment, despite all the replacement therapies, blood count values did not improve (patient's blood counts before and after the dapsone treatment were shown in Graphic 1). Allogeneic stem-cell transplantation treatment was planned but the patient refused the treatment. Replacement therapies were continued.



Graphic 1. Patient's blood counts before and after the dapsone treatment

3. Discussion

Dapsone can cause hematopoietic toxicity even in low doses and rarely peripheral neuropathy, hypoalbuminemia and psychosis (6). Hematologic side effects of dapsone are agranulocytosis, pancytopenia, direct coombs (+) hemolytic anemia, methemoglobinemia and aplastic anemia. Agranulocytosis usually occurs in 4-12 weeks, hemolytic anemia usually occurs in 3-4 weeks and methemoglobinemia usually occurs in two weeks after beginning of the dapsone therapy. These side effects may improve after dissolving therapy. Aplastic anemia usually occurs in 2-12 weeks after beginning therapy,

is very rare but remains even after dissolving therapy and can be fatal (4). Up to date, there have been five dapsone induced aplastic anemia cases in literature and four of them progressed on fatal course. Our case is the sixth dapsone induced aplastic anemia in the literature (Table 1), but he did not proceed on fatal course and the blood count values did not improve (4). Aplastic anemia remained after dissolving therapy but the patient did not consent allogeneic stem-cell transplantation, so symptomatic treatment of transfusions and antibiotics on febrile periods were being administrated.

Table 1

Dapsone induced aplastic anemia patients' clinical features

Case	Age/Sex	Disease	Dosage (mg/day)	Clinical Onset	Outcome
1	13/M	Dermatitis herpetiformis	50	2-3 mo	Fatal
2	18/M	Lepromatous leprosy	50	2-3 wk	Nonfatal
3	37/M	<i>Pneumocystis carinii</i> pneumonia	100	10 days	Fatal
4	41/F	Bullous SLE	200	4 wk	Fatal
5	55/F	Dermatitis herpetiformis	100	6 wk	Fatal
6 (current case)	59/F	Dermatitis	200	6 wk	Nonfatal

Before administrating dapsone treatment, CBC and reticulocyte counts must be performed and these routine tests must be maintained weekly during the first three months, then monthly during the sequent 6

months or biweekly during the first three months, then monthly during the sequent three months or weekly during the first month, then trimonthly. Therapy must be discontinued if leukocyte and/or platelets and/or hemoglobin

levels decreases, especially during the first three months of treatment (4,6,7). In our patient, CBC and reticulocyte counts did not performed before doubling the dose and routine tests did not maintained during the follow-up because the patient did not have any complaints. Aplastic anemia may have prevented if the patient continued frequent follow-ups and stopping the treatment when decreases in leukocyte, thrombocyte or platelets were seen. Before the therapy, patients must be informed about the possible side effects and routine tests must be maintained especially weekly or biweekly during the first three months, and at least monthly during the sequent three months and then trimonthly for lifelong.

4. Conclusion

Before starting dapsone treatment, side effect profile must be discussed thoroughly; periodic CBC must be performed before and after the treatment, even without any patient complaints. Patient must be informed about the side effects and must be warned to appeal the physician when fever, symptoms of infection, bleeding, bruise without trauma, dyspnea and cyanosis occur. We also suggest that the first follow up should be made 7 days after the beginning of treatment, so that adverse side effects can be detected as early as possible.

REFERENCES

1. Plotkin, J. S., Buell, J. F., Njoku, M. J., Wilson, S., Kuo, P. C., Bartlett, S. T., ... & Johnson, L. B. (1997). Methemoglobinemia associated with dapsone treatment in solid organ transplant recipients: A two-case report and review. *Liver Transplantation and Surgery*, 3(2), 149-152.
2. Ranawaka, R. R., Mendis, S., & Weerakoon, H. S. (2008). Dapsone-induced haemolytic anaemia, hepatitis and agranulocytosis in a leprosy patient with normal glucose-6-phosphate-dehydrogenase activity. *Leprosy review*, 79(4), 436.
3. Hörnsten, P., Keisu, M., & Wiholm, B. E. (1990). The incidence of agranulocytosis during treatment of dermatitis herpetiformis with dapsone as reported in Sweden, 1972 through 1988. *Archives of dermatology*, 126(7), 919-922.
4. Meyerson, M. A., & COHEN, P. R. (1994, December). Dapsone-induced aplastic anemia in a woman with bullous systemic lupus erythematosus. In *Mayo Clinic Proceedings* (Vol. 69, No. 12, pp. 1159-1162). Elsevier.
5. Foucauld J, Uphouse W, Berenberg J. (1985). Dapsone and aplastic anemia, *Ann Intern Med* 102:139
6. Mishra, M., & Chhetia, R. (2006). Dapsone-induced agranulocytosis in a patient of leprosy. *Indian Journal of Dermatology, Venereology, and Leprology*, 72(6), 456.
7. Machet, L., Callens, A., Mercier, E., Gargot, S., Lorette, G., & Vaillant, L. (1995, December). [Agranulocytosis induced by dapsone prescribed for dermatitis herpetiformis]. In *Annales de dermatologie et de venerologie* (Vol. 123, No. 5, pp. 328-330).