

The location of mandibular foramen relative to the occlusal plane: a study on anatolian dry mandible

Purpose

The study aims to evaluate the location of mandibular foramen (MF) with respect to the occlusal plane (OP) and its location on the ramus using Anatolian dry mandibles.

Materials and Methods

A total of 115 dry mandibles with mandibular molars were analyzed. The distance between the MF and the OP was examined with a flat metal plate. Group A was above the OP; group L was at level, and group B was below the OP. The distances between the MF and anterior border (A-MF), sigmoid notch (U-MF), posterior border (P-MF), and lower border (L-MF) were measured. The symmetry between the two sides was examined. Pearson chi-square and Student's t-test were performed for statistical analysis.

Results

According to the analysis, 50.23% of MF was located below the OP ($p < 0.05$). The mean distances of Groups A and B were 3.45 and 4.78 mm, respectively. There was no difference between the left and right in groups ($p > 0.05$). The distance A-MF was 14.71 mm. There was no statistical difference between the distances A-MF and P-MF or U-MF and L-MF.




Conclusion

Half of the MF (50.23%) was located below the occlusal plane with a mean distance of 4.78 mm. It may be helpful to place the needle 3-4 mm above the OP and 1.5-2 mm back of the anterior border to obtain a successful inferior alveolar nerve block. The MF was located at the center of the medial surface of the ramus.

Keywords: Anatomy, mandible, mandibular foramen, mandibular nerve, occlusal plane

Introduction

Modern dentistry denies painful practices. However, it is not possible to deny the failure rate of the inferior alveolar nerve block (IANB), which has been reported to be between 13% and 57% (1,2). More dramatically, 90% of the clinicians reported difficulties with obtaining proper anesthesia in dental practice (1). IANB, which is used in the treatment of mandibular posterior teeth, is one of the local anesthesia techniques that require the most diligent and target-oriented application in dental practice. IANB, in other words, the Halsted technique, or 'mandibular nerve block', which is a misnomer according to Malamed (3), is based on the deposition of an anesthetic solution in the pterygomandibular space, which includes the inferior alveolar nerve and foramen mandible. The inferior alveolar nerve enters the mandibular canal through the mandibular foramen and provides innervation to the mandibular molars and premolars along its course (1,3). Various reasons lead to the failure of the anesthetic technique including anatomic variations, uncommon physiology, and the presence of infection; however, the prom-

Ahmet Mert Nalbantoğlu¹ ,
Deniz Yanık² ,
Soner Albay³ 

ORCID IDs of the authors: A.M.N. 0000-0002-0505-867X;
D.Y. 0000-0001-5676-0293; S.A. 0000-0001-8438-8628

¹Antalya Bilim University, School of Dentistry,
Department of Periodontology, Antalya, Turkiye

²Antalya Bilim University, School of Dentistry,
Department of Endodontics, Antalya, Turkiye

³Süleyman Demirel University, School of Medicine,
Department of Anatomy, Isparta, Turkiye

Corresponding Author: Deniz Yanık

E-mail: deniz.yanik@yahoo.com

Received: 7 March 2023

Revised: 19 April 2023

Accepted: 25 May 2023

DOI: 10.26650/eor.20241261599

inent reason for the failure is the inability to determine the mandibular foramen location (4). Since the needle penetration depth or location is adjusted according to the surrounding tissues or landmarks, it is substantial to have a fixed reference point that can be observed directly in the mouth while administering anesthesia, instead of hard-to-observe anatomical formations to ensure the proximity of the anesthetic solution to the nerve (5,6).

For IANB, another important point in addition to the failure of anesthesia is the possible complications including hemorrhage, soft or hard tissue necrosis, or nerve damage, that may occur during the application (6). Therefore, meticulous knowledge about the location of the MF and the topography of the ramus is required. The morphological dimensions of the mandible and the topography of the mandibular foramen relative to the occlusal plane (OP) were evaluated using dry mandible (4,7-10) or radiography (11-15) in different populations. Since different methodologies of radiographic measurement may change in determining the location of MF (13,15), dry mandibles provide substantial data as a direct observation method despite having a limited sample size. Altunsoy *et al.* (12) reported the relative location of MF in children using cone-beam computed tomography (CBCT) in the Turkish population. Oğuz and Bozkır (16) analyzed the morphology of the ramus using Turkish dry mandibles but provided no information about the OP and the relative location of the MF. When considering the effects of racial and methodological factors, more studies are needed to obtain well-established data. The objective of this study is to evaluate the relative location of MF to the OP and to analyze the topographic placement of the MF on the ramus using Anatolian dry mandibles. The null hypothesis of the study was that the MF would not be above the OP.

Materials and Methods

Study design

The study was conducted in the anatomy department laboratory of Akdeniz University Faculty of Medicine and Süleyman Demirel University Faculty of Medicine with the obtained permissions. A total of 298 dry mandibles were scanned. Age and gender were unknown. Inclusion criteria were mandibles with intact ramus and with mandibular molars for analyzing the relative location to the OP. Exclusion criteria were ragged or deformed mandibles excessively enough to affect the measurement, mandibular molars in supraocclusion or inclined mandibular molars, and mandibular molars with advanced crown destruction. The supraocclusion was regarded if the distance between the cementoenamel junction and the alveolar bone was more than 1 mm. For the study, 115 dentate dry adult human mandibles were selected.

Cadaveric measurements

We measured the distance between the MF and the most concave point of the anterior border (coronoid notch) (A-MF), posterior border of the ramus (P-MF), sigmoid (mandibular) notch (U-MF), and lower border

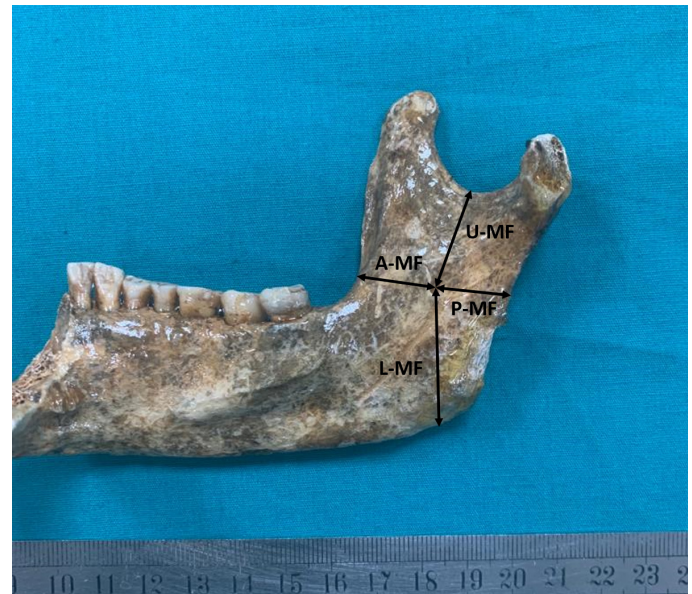

Figure 1. Morphometric measurements of the ramus (MF: Mandibular foramen. A-MF: the distance between the MF and the most concave point of the anterior border. P-MF: the distance between the MF and posterior border of the ramus. U-MF: the distance between the MF and sigmoid notch. L-MF: the distance between the MF and lower border of the ramus).

of the ramus (L-MF), at the left and right sides (Figure 1). The center of the mandibular foramen was taken as a fixed reference point. While determining the occlusal plane, two buccal cups of the second mandibular molar were used according to the basic geometry logic of "a line passes through two points." A rigid flat metal plate of 0.5 mm in thickness was placed on the second molar and stabilized. In the inner surface of the ramus, the point on the line referred by the metal plate and in the MF alignment was marked with a fine-tipped erasable pen, and the distance between the MF and the mark was measured with a digital caliper.

All measurements were performed independently by two observers (DY, a 6-year experienced endodontist, and AMN, a 10-year experienced periodontist) twice to obtain inter-class and intra-class reliability. Prior to measurements, for the calibration of observers, the measurements of 21 dentate mandibles (10% of the total sample size) were performed, and Cohen's kappa values were obtained (ranging from 0.88 to 0.93). The relative location of the MF to the occlusal plane and morphometric measurements was recorded.

Study groups

The relative location of the MF to the OP was allocated to three groups; Group A: MF was above the OP, Group L: MF was at the level of the OP, and Group B: MF was below the OP (Figure 2). Each measurement was performed three times, and the average value was recorded for statistical analysis. All measurements were recorded in millimeters. A digital caliper (SC-6, Mitutoyo Corporation, Tokyo, Japan) was used for the measurements.

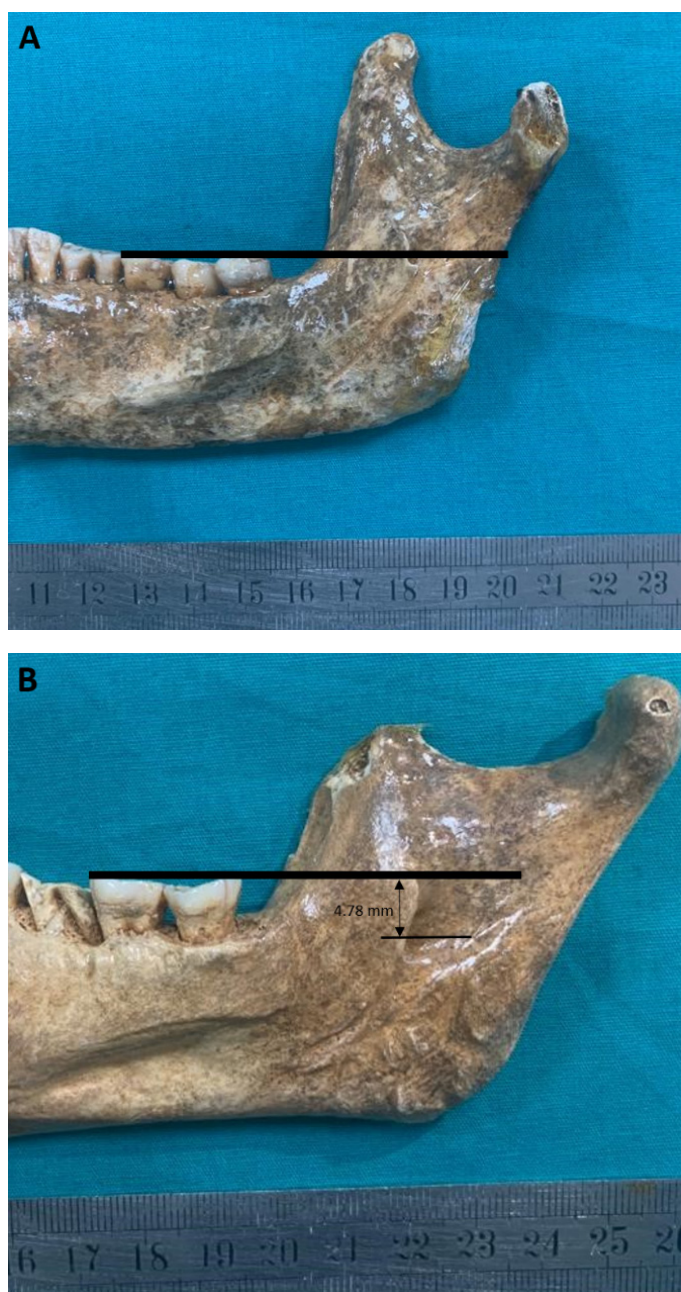

Figure 2. Representative image of the measurement of the location of the mandibular foramen. A: Group L; at level, B: Group B; below the occlusal plane.

Statistical analysis

Dataset was analyzed using SPSS software version 26.0 (IBM SPSS Inc, Armonk, NY, USA). The normality distribution of the data was analyzed using Kolmogorov-Smirnov. Levene's test was performed to determine the homogeneity of the data. Pearson chi-square test was applied for the symmetry of the relative location of the MF to the OP. Morphometric measurements were analyzed with Student's t-test. Interclass correlation coefficient (ICC) was used for the reliability of the observers. Statistical difference was considered significant with a 95% confidence interval at $p < 0.01$ for the ICC, and $p < 0.05$ for other tests.

Results

There was no statistical difference in the intra-observer and inter-observer measurement values. For the morphometric measurements of the MF, ICC values were 0.845 and $ICC = 0.913$. The mean and standard deviations of upper, lower, anterior, and posterior measurements and symmetry of the MF location are presented in Table 1. The distance between the MF and anterior border of the ramus was 14.71 mm. The distance between the MF and posterior border was 12.67 mm. The distance of the MF to the sigmoid notch was 22.61 mm, and the distance to the basis of the ramus was 23.04 mm. According to Student's t-test, no significance was detected between the distances A-MF and P-MF, and similarly, in the distances U-MF and L-MF. Hence, the MF was located approximately at the center of the ramus. There was also no significant difference between the left and right sides in terms of morphometric measurements. The morphometric distances to the OP, and percentages of Group A, L, and B were shown in Table 2. The mean distance between the MF and OP in the group A was 3.45 mm, while group B was 4.78 mm (Figure 2). The MF was located in an area ranging from 11.04 mm superior to 9.89 mm inferior to the occlusal plane. The frequency of groups A, L, and B were 38.43%, 11.34%, and 50.23%, respectively. The most observed (50.23%) location was Group B, which means it was below the OP ($p < 0.05$). No statistical difference was detected in the symmetry of the level of the MF according to the OP between the left and right sides.

Table 1: Morphometric measurements (in mm) and symmetry of the location of the mental foramen

	Total	Symmetry		P value
		Right	Left	
	Mean (\pm Std)	Mean (\pm Std)	Mean (\pm Std)	
Anterior	14.71 (\pm 2.24)	15.77 (\pm 2.51)	13.65 (\pm 1.69)	0.074
Posterior	12.67 (\pm 2.18)	12.19 (\pm 2.60)	13.15 (\pm 1.98)	0.067
P value	0.19	0.07	0.34	
Upper	22.61 (\pm 4.45)	21.92 (\pm 4.90)	23.03 (\pm 3.87)	0.14
Lower	23.04 (\pm 3.23)	23.41 (\pm 3.83)	22.67 (\pm 2.97)	0.063
P value	0.24	0.16	0.21	

No statistical difference was observed between morphometric data or two sides according to the Student's t-test ($p < 0.05$).

Table 2: Relative location of the mental foramen to the occlusal plane

	Total		Right		Left		P value
	Mean (\pm Std)	%	Mean (\pm Std)	%	Mean (\pm Std)	%	
Group A	+3.45 (\pm 1.29)	38.43%	+3.12 (\pm 1.27)	41.01%	+3.78 (\pm 1.35)	35.85%	0.16
Group L	N/A	11.34%	N/A	12.17%	N/A	10.51%	0.27
Group B	-4.78 (\pm 1.28)	50.23%	-4.56 (\pm 1.34)	49.25%	-5.01(\pm 1.13)	51.21%	0.08
P value		0.001		0.002		0.001	

Group A: above, Group L: at level, Group B: below the occlusal plane

Bold p values mean statistical difference according to the Pearson chi-square test ($p < 0.05$). Minus indicates below the OP and indicates above the OP.

Discussion

Within the limited sample size of the study, the most important result of the study is that 50.23% of the MF was located below the OP. Endodontic treatment, extraction, and most dental treatments require block anesthesia rather than local infiltration that does not supply proper anesthesia due to the thick compact bone of the mandible (15). The clinician has blind access to the MF as it is covered by soft tissue, but the solution must be injected as close to the MF as possible to rule out the possible complications including hemorrhage, and persistent injury to the nerve, and for successful anesthesia (13). Therefore, for proper anesthesia, a clinical reference point is required. Previous studies indicated that MF was positioned below the OP in the range of 80.4% to 19.87% in African, Thai, Zimbabwean, Brazilian, and East Indian populations as described in Table 3 (5,7,9-15,17-26). Different methodologies or ethnicity lead to this wide range of results. One of the methodological differences was the measurement point of the MF. The middle of the superior line of the MF (14), the lingula (7,15), or the center of the MF (4,8) was assumed when analyzing the relative location. In the present study, the center of the MF was accepted as the measurement point. Different reference points in different studies make it difficult to compare in millimeters, and the distance of the area where anesthesia will be applied relative to the occlusal plane should be interpreted carefully. Besides the reference point that is covered with soft tissue cannot be directly observed clinically. Another reason for the differences in MF location may be due to various definitions of the occlusal plane in the studies. The first molar (11,20-22), second molar (7,13), or mandibular molars (17-19), the line passing through the canine and molars (23), or the adjusted occlusal plane (14) were considered for the measurements. According to Russ (20), the first molar is the best reference point for IANB. However, the first molar is the first permanent tooth to erupt, it is the most frequently decayed or lost. In the present study, we considered mandibular molars as a reference line using a metal flat line. Taking a single mandibular molar as a reference will affect the measurement, reducing the accuracy of the investigation when considered that the tooth has occlusal wear, restoration, or decay, or that it was in supraocclusion position or pathologic migration. Taking the occlusal plane as a reference by including molars instead of a single molar provides a more precise definition of the occlusal plane.

A previous study performed on dry mandibles analyzed the level of the MF according to the coronoid notch (10).

However, the coronoid notch is covered by the moveable mucosa and may not present a stable point like molar tubercles. Thus, since it is a difficult point to estimate, its precision in clinical practice is reduced when considering the quantitative data. The coronoid notch properly guides the anteroposterior position of the needle, but its reference characteristic for the vertical level of the MF should be interpreted with caution.

The most important drawback in the evaluation of the occlusal plane is the irregularity of the mandibular teeth. The irregular mandibular teeth can alter the data, consequently, the precise location of the MF in mm cannot be compared properly in different populations. Likewise, various reference points, definitions of the occlusal plane, differences in measurement methodologies, and several measurement media may cause millimetric changes in the distance of MF from the occlusal plane, as well as racial factors. On the other hand, in the quantitative analysis of a dry skull, the measurements are performed on an amorphous surface, and minor angle differences affect the results. Besides, due to the curve of Spee, the buccal tubercle levels of mandibular molars may be divergent (27). Therefore, instead of specifying the numeric data belonging to the distance of the MF, which is not already a clinically observable point, determining the area where the MF is located frequently, such as above, below, or at the level of the occlusion, may create a clinically easier and more applicable approach. Therefore, although we provided quantitative data in the present study, we emphasized the areas where MF was concentrated. Group B (below the OP) was higher. The relative location of MF was similar on each side. This result was congruent with previous studies (11,12,14,20). Investigation of the dry mandible provides a direct observation. However, for observation on panoramic radiography, a patient's improper head movement or position may create a false asymmetry between the left and right sides.

We found that the location of the MF was at the center of the ramus, which is consistent with previous studies conducted with Turkish people or other populations (7,16). While measuring the distance of the MF to the anterior border on the ramus, the most concave point, the coronoid notch, was accepted, as in most previous studies (10,14). Topographic measurements of MF localized in the ramus are important for IANB (15). However, during injection, since the posterior border, the sigmoid notch, and the medial aspect of the ramus are not seen totally, clinically observable or palpable points are of greater importance in determining the technique of the anesthesia.

Table 3: Location of mandibular foremen in previous studies

Study	Ethnicity	Methodology	Sample size	References	Location
Afsar	Canadian	Panoramic	79	First molar	1.9 mm above
Hwang	Chinese	Cephalometric	112	Undetermined	4.16 mm above
Feurerstrein	French	CBCT	260	Mandibular teeth	2-3 mm above
Altunsoy	Turkish	CBCT	20	Mandibular molars	2.5-3.6 mm above
Blatcher	American	CBCT	203	Second molar	9 mm above
Al-Shayyab	Jordanian	CBCT	224	First molar	2.5 mm above
Jang		CBCT	125	Second molar	8.85 mm above
Bunyarit	Malay	CBCT	87	Undetermined	10 mm above
Kang	Korean	CT	59	First molar	3.8 mm above
Zhou	Korean	CBCT	106	Mandibular molars	12.4% above (2.5mm) 3.3% at level 84% below (4.5mm)
Russa	Tanzania	Cadaveric mandible	44	First molar	10 mm above
Monnazzi	Brazilian	Dry mandible	44	Mandibular crest	0.02 below
Thangevalu	Indian	Dry mandible	102	Mandibular molars	Few mm above
Kositbowornchai	Thai	Dry mandible	23	First molar	10 mm above
Nicholson	East Indian	Dry mandible	80	Second molar	2.5% above 22.5% at level 75% below
Palma	Brazilian	Dry mandible	82	Mandibular molars	15.1% above 0.8% at level 84.1% below
Jansisyonont	Thai	Dry mandible	146	Mandibular molars	80.13% above (4.5 mm) 19.87% below (3.1 mm)
Mbarjorgu	Zimbabwean	Dry mandible	38	Mandibular molars	29.4% above 47.1% at level 23.5% below
Mwaniki	African	Dry mandible	79	Mandibular molars	4.7% above 30.7% at level 64.6% below
The result of the present study	Anatolian	Dry mandible	105	Mandibular molars	38.43% above (4.5 mm) 11.34% at level 50.23% below (3.1 mm)

CBCT: cone-beam computed tomography

The direct method using skulls or radiographic method was used to determine the relative location of MF with the OP (5,7,9-15,17-26). Although the skull provides direct observation, when the investigation is based on an "imaginary line" without systematic methodology, this approach makes such valuable data as direct observation subjective and unrepeatable. Therefore, the accuracy of the measurements would be skeptical. In the present study, it was used a metal line to determine the OP alignment directly, similar to the study of Palma *et al.* (9) which used plastic to compare the level previously.

The limitation of the study is that it concerns a certain population as it was conducted in dry skulls. In the present study, the effect of age and gender or different skeletal patterns was not examined. Besides, another limitation of the study is that the dry mandibles were obtained from one region of Anatolia and they were limited in number. More clinical and cross-sectional studies on different populations and

a wider sample are needed. From a different perspective, future studies should focus on clinical applications of different anesthetic techniques rather than detecting the exact localization of MF that has different variations. The strength of the study is that it is the first study in which the relationship of the occlusal plane with MF was examined in the Anatolian population by direct observation using a dry mandible.

Conclusion

Due to the limitation of this study, it was concluded that the distance of MF to the coronoid notch was 14.71 mm. The mandibular foramen was located at the center of the medial surface of the ramus. The mandibular foramen was located below the occlusal plane, with a rate of 50.23%. The MF located was in an area that was between 4.78 mm below and 3.45 mm above the plane of occlusion. This anatomic data may be useful in the projection of the needle during

IANB. The take-home message of the present study is that the highest rate of success can be achieved during anesthesia when the needle is positioned slightly above the occlusal plane (approximately 3.5 - 4 mm) and 1.5 - 2 cm behind the anterior edge, given that the results that showed 50% of MF was located below the occlusal plane and the 14.71 mm distance to the coronoid notch. Besides, the results can be informative for the location of osteotomies during maxillofacial surgeries in terms of the avoidance of permanent damage to vital structures including nerves. Nevertheless, it is crucial to remark that the data of the study demonstrated a benchmark result. In clinical practice, it is essential to perform analysis on a case-by-case basis.

Türkçe özet: Mandibular Foramenin Oklüzal Düzleme Göre Konumu: Anadolu Kuru Mandibularları Üzerinde Yapılan Bir Çalışma. Amaç: Bu çalışma, Anadolu kuru mandibularları üzerinde mandibular foramenin (MF) oklüzal düzleme (OP) göre konumunu ve ramus üzerindeki yerleşimini değerlendirmeyi amaçlamaktadır. Gereç ve Yöntem: Mandibular azı dişleri olan toplam 115 kuru mandibula analiz edildi. MF ve OP arasındaki mesafe düz bir metal plaka ile ölçüldü. Grup A, OP'nin üzerinde; Grup L PO seviyesinde ve grup B OP'nin altında olacak şekilde gruplandırıldı. MF ile ramus ön sınırı (A-MF), sigmoid çentik (U-MF), ramus arka sınırı (P-MF) ve ramus alt sınırı (L-MF) arasındaki mesafeler ölçüldü. Sağ ve sol arasındaki simetri incelendi. İstatistiksel analiz için Pearson ki-kare ve Student t-testi yapıldı. Bulgular: Analize göre MF'nin %50.23'ü OP'nin altında yer aldı ($p < 0.05$). Grup A ve B'nin ortalama mesafeleri sırasıyla 3.45 ve 4.78 mm olarak tespit edildi. Gruplarda sağ ve sol arasında fark bulunmadı. A-MF mesafesi 14,71 mm'yd. A-MF ve P-MF veya U-MF ve L-MF mesafeleri arasında istatistiksel fark tespit edilmedi ($p > 0.05$). Sonuç: MF'nin yarısı (%50.23) ortalama 4.78 mm mesafe ile oklüzal düzlemin altında yer alıyordu. MF, ramusun medial yüzeyinin merkezinde konumlandı. Bu sonuçlara göre başarılı bir inferior alveolar sinir bloğu elde etmek için enjektör OP'nin 3-4 mm yukarısına ve ön sınırın 1.5-2 mm arkasına yerleştirmek yararlı olabilir. Anahtar kelimeler: Anatomi, mandibula, mandibular sinir, oklüzyon, lokal anestezi

Ethics Committee Approval: Necessary permissions were obtained from Akdeniz University Faculty of Medicine and Süleyman Demirel University Faculty of Medicine.

Informed Consent: Not required.

Peer-review: Externally peer-reviewed.

Author contributions: AMN, DY, SA participated in designing the study. AMN, DY, SA participated in generating the data for the study. AMN, DY, SA participated in gathering the data for the study. AMN, DY participated in the analysis of the data. DY wrote the majority of the original draft of the paper. AMN, DY, SA participated in writing the paper. AMN, DY has had access to all of the raw data of the study. AMN, DY, SA has reviewed the pertinent raw data on which the results and conclusions of this study are based. AMN, DY, SA have approved the final version of this paper. AMN, DY, SA guarantees that all individuals who meet the Journal's authorship criteria are included as authors of this paper.

Conflict of Interest: The authors declared that they have no conflict of interest.

Financial Disclosure: The authors declared that they have received no financial support.

References

- Kaufman E, Weinstein P, Milgrom P. Difficulties in achieving local anesthesia. *J Am Dent Assoc* 1984;108:205-8. [CrossRef]
- Sawadogo A, Coulibaly M, Quilodran C, Bationo R, Konsem T, Ella B. Success rate of first attempt 4% articaine para-apical anesthesia for the extraction of mandibular wisdom teeth. *J Stomatol Oral Maxillofac Surg* 2018;119:486-8. [CrossRef]
- Malamed SF (2020) Handbook of local anesthesia. 7th edn. Elsevier, St. Louis.
- Palti DG, Almeida CMD, Rodrigues ADC, Andreo JC, Lima JEO. Anesthetic technique for inferior alveolar nerve block: a new approach. *J Appl Oral Sci* 2011;19:11-5. [CrossRef]
- Hwang TJ, Hsu SC, Huang QF, Guo MK. Age changes in location of mandibular foramen. *Zhonghua Ya Yi Xue Hui Za Zhi* 1990;9:98-103.
- Iwanaga J, Choi PJ, Vetter M, Patel M, Kikuta S, Oskouian RJ, Tubbs RS. Anatomical study of the lingual nerve and inferior alveolar nerve in the pterygomandibular space: complications of the inferior alveolar nerve block. *Cureus* 2018;10:e3109. [CrossRef]
- Nicholson ML. A study of the position of the mandibular foramen in the adult human mandible. *Anat Rec* 1985;212:110-2. [CrossRef]
- Prado FB, Groppo FC, Volpato MC, Caria PHF. Morphological changes in the position of the mandibular foramen in dentate and edentate Brazilian subjects. *Clin Anat* 2010;23:394-8. [CrossRef]
- Palma LF, Almeida FSO, Lombardi LA, Cavalli MA, de Moraes LOC. Is the inferior occlusal plane a reliable anatomic landmark for inferior alveolar nerve block? A study on dry mandibles of Brazilian adults. *Morphologie* 2020;104:59-63. [CrossRef]
- Thangavelu K, Kannan R, Kumar NS, Rethish E, Sabitha S, Sayeeganesh N. Significance of localization of mandibular foramen in an inferior alveolar nerve block. *J Nat Sci Biol Med* 2012;3:156-60. [CrossRef]
- Al-Shayyab MH. A simple method to locate mandibular foramen with cone-beam computed tomography and its relevance to oral and maxillofacial surgery: a radio-anatomical study. *Surg Radiol Anat* 2018;40:625-34. [CrossRef]
- Altunsoy M, Aglarci OS, Ok E, Nur BG, Gungor E, Colak M. Localization of the mandibular foramen of 8-18 years old children and youths with cone-beam computed tomography. *J Pediatric Dent* 2014;2:44-8. [CrossRef]
- Blacher J, Van DaHuvel S, Parashar V, Mitchell JC. Variation in location of the mandibular foramen/inferior alveolar nerve complex given anatomic landmarks using cone-beam computed tomographic scans. *J Endod* 2016;42:393-6. [CrossRef]
- Feuerstein D, Costa-Mendes L, Esclassan R, Marty M, Vaysse F, Noirrit E. The mandibular plane: a stable reference to localize the mandibular foramen, even during growth. *Oral Radiol* 2020;36:69-9. [CrossRef]
- Zhou C, Jeon TH, Jun SH, Kwon JJ. Evaluation of mandibular lingula and foramen location using 3-dimensional mandible models reconstructed by cone-beam computed tomography. *Maxillofac Plast Reconstr Surg* 2017;39:1-7. [CrossRef]
- Oguz O, Bozkir MG. Evaluation of location of mandibular and mental foramina in dry, young, adult human male, dentulous mandibles. *West Ind Med J* 2002;51:14-6.
- Mbajiorgu EF, Ekanem AU. A study of the position of the mandibular foramen in adult black Zimbabwean mandibles. *Cent Afr J Med* 2000;46:184-90. [CrossRef]
- Mwaniki DL, Hassanali J. The position of mandibular and mental foramina in Kenyan African mandibles. *East Afr Med J* 1992;69:210-3.
- Jansisyant P, Apinhasmit W, Chompoopong S. Shape, height, and location of the lingula for sagittal ramus osteotomy in Thais. *Clin Anat* 2009;22:787-93. [CrossRef]
- Russa A, Fabian F. Position of the mandibular foramen in adult male Tanzania mandibles. *Ital J Anat Embryol* 2014;119:163-8.
- Afsar A, Haas DA, Rossouw PE, Wood RE. Radiographic localization of mandibular anesthesia landmarks. *Oral Surg Oral Med Oral Pathol Oral Radiol Endod* 1998;86:234-41. [CrossRef]
- Kositbowornchai S, Siritapetawee M, Damrongrungruang T, Khongkankong W, Chatrchaiwiwatana S, Khamanarong K, Chanthaooplee T. Shape of the lingula and its localization by

- panoramic radiograph versus dry mandibular measurement. *Surg Radiol Anat* 2007;29:689-94. [\[CrossRef\]](#)
23. Jang HY, Han SJ. Measurement of mandibular lingula location using cone-beam computed tomography and internal oblique ridge-guided inferior alveolar nerve block. *J Korean Assoc Oral Maxillofac Surg* 2019;45:158-66. [\[CrossRef\]](#)
 24. Bunyarit SS, Ying RPY, Kadir BA, Nizam MM, Rahman M. Dental intervention perspective: Anatomical Variation of Mental and Mandibular Foramen in Selected Malay Patients. *Bangladesh J Med Sci* 2016;15:450-4 [\[CrossRef\]](#)
 25. Kang SH, Byun IY, Kim JH, Park HK, Kim MK. Three-dimensional anatomic analysis of mandibular foramen with mandibular anatomic landmarks for inferior alveolar nerve block anesthesia. *Oral Surg Oral Med Oral Pathol Oral Radiol* 2013;115:17-23. [\[CrossRef\]](#)
 26. Monnazzi MS, Passeri LA, Gabrielli MFR, Bolini PDA, De Carvalho WRS, da Costa Machado H. Anatomic study of the mandibular foramen, lingula and antilingula in dry mandibles, and its statistical relationship between the true lingula and the antilingula. *Int J Oral Maxillofac Surg* 2012;41:74-8. [\[CrossRef\]](#)
 27. Beltrão, P. Treatment of Class II deep overbite with multiloop edgewise arch-wire (MEAW) therapy. Principles in contemporary orthodontics. Rijeka, Croatia: InTech 2011;55-78. [\[CrossRef\]](#)