

## A RARE CASE OF RENAL CLEAR CELL CARCINOMA ACROMETASTASIS AND ITS MANAGEMENT

### NADİR BİR RENAL BERRAK HÜCRELİ KARSİNOM AKROMETASTAZI OLGUSU VE OLGUYA YAKLAŞIM

Erol KOZANOĞLU<sup>1</sup> , Bora Edim AKALIN<sup>1</sup> , Dicle AKSÖYLER<sup>1</sup> , Hayri Ömer BERKÖZ<sup>1</sup> 

<sup>1</sup>Istanbul University, Istanbul Faculty of Medicine, Department of Plastic Reconstructive and Aesthetic Surgery, Istanbul, Türkiye

**ORCID IDs of the authors:** E.K. 0000-0003-1192-9520; B.E.A. 0000-0002-5654-2082; D.A. 0000-0002-3692-8893; H.Ö.B. 0000-0001-8063-9995

**Cite this article as:** Kozanoglu E, Akalin BE, Aksoyler D, Berkoz HO. A rare case of renal clear cell carcinoma acrometastasis and its management. J Ist Faculty Med 2023;86(3):272-274. doi: 10.26650/IUITFD.1290975

#### ABSTRACT

Metastases that affect the distal regions of the upper and the lower extremities are called acrometastases and they affect the bones and the overlying tissues. Various cancer types may have single or multiple acrometastases. A sixty-four-year-old female patient had a painful and enlarging mass at the tip of the fifth digit of her right hand. The lesion appeared as a red macule at the junction between the nail plate and the hyponychium. The patient was in her seventh postoperative year after a left-sided radical nephrectomy with a histopathological diagnosis of renal clear cell carcinoma. Due to multiple metastases to the spleen and left femoral head, she had been treated with twenty sessions of radiotherapy and she was under nivolumab therapy twice a month for two years. A punch biopsy revealed a gland forming, CD 10, PAX 8 and vimentin-positive renal clear cell carcinoma metastasis. The patient was treated with amputation of the distal phalanx. Although rare, acrometastasis should be included in the differential diagnosis of patients with a history of renal clear cell carcinoma.

**Keywords:** Acrometastasis, amputation, hand, phalanx, renal clear cell carcinoma

#### ÖZET

Üst ve alt ekstremitenin distal kısımlarını etkileyen metastazlara akrometastaz denir ve bu tabloda, kemikler ve üzerlerindeki dokular etkilenir. Farklı kanser türleri tekli veya çoklu akrometastazlar yapabilir. Altmış dört yaşındaki bir kadın hasta, sağ elinin beşinci parmağının ucunda ortaya çıkan ağrılı ve sürekli büyüyen bir kitle ile polikliniğe başvurmuştur. Lezyon, tırnak plağı ve hiponiyum kesişimindeki kırmızı bir maküldür. Hasta, yedi yıl önce histopatolojik tanısı renal berrak hücreli karsinom olan bir kitle nedeniyle sol taraflı radikal nefrektomi geçirmiştir. Hastanın dalağında ve sol femur başında çoklu metastazları olduğundan hastaya yirmi seans radyoterapi uygulanmıştır. Hastaya son iki yıldır, ayda iki kez nivolumab tedavisi verilmiştir. Yapılan punch biyopside CD 10, PAX 8 ve vimentin pozitif olan ve gland oluşturan renal berrak hücreli karsinom metastazi saptanmıştır. Hastaya distal falanks amputasyonu ameliyatı yapılmıştır. Renal berrak hücreli karsinom öyküsü olan hastalarda görülen parmak lezyonlarının ayırıcı tanısında, nadir de olsa akrometastaz göz önünde bulundurulmalıdır.

**Anahtar Kelimeler:** Akrometastaz, amputasyon, el, falanks, renal berrak hücreli karsinom

**Corresponding author/İletişim kurulacak yazar:** Erol KOZANOĞLU – erol.kozanoglu@istanbul.edu.tr

**Submitted/Başvuru:** 02.05.2023 • **Revision Requested/Revizyon Talebi:** 13.06.2023 •

**Last Revision Received/Son Revizyon:** 26.06.2023 • **Accepted/Kabul:** 05.07.2023 • **Published Online/Online Yayın:** 25.07.2023



Content of this journal is licensed under a Creative Commons Attribution-NonCommercial 4.0 International License.

## INTRODUCTION

The metastases that affect the distal regions of the upper and the lower extremities are called acrometastases and they affect the bones and the overlying tissues (1). Acrometastasis is a very rare entity and it comprises only 0.1% of all metastases (2). Various cancer types such as lung, colorectal, breast and genitourinary cancer may have single or multiple acrometastases (2, 3). Although this pathology can be seen in all genders and age groups, it is usually detected in the dominant hands of males (1, 4, 5).

Renal cell carcinoma accounts for 3% of all malignant lesions and approximately 400,000 new cases are diagnosed annually. Hand acrometastasis may be seen in 0.1% of patients with renal cell carcinoma (5-8). In this case report, a patient with a single renal clear cell carcinoma acrometastasis to the right fifth distal phalanx and her treatment plan are presented.

## CASE REPORT

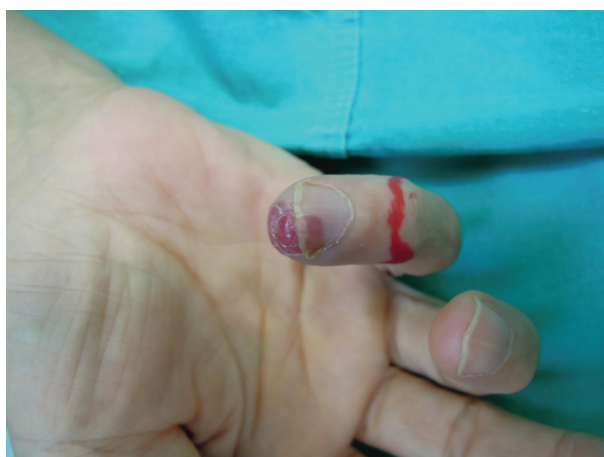A sixty-four-year-old female patient was referred to the Department of Plastic Reconstructive and Aesthetic Surgery by the Department of Medical Oncology. She had a painful and enlarging mass at the tip of the fifth digit of her right hand (Figure 1). The patient, with a dominant right hand, stated that she noticed the lesion which appeared as a red macule at the junction between the nail plate and the hyponychium three months ago.

The patient had a left-sided total nephrectomy due to a histopathological diagnosis of renal clear cell carcinoma (WHO/ISUP Grade 2) and she was in her seventh postoperative year. The patient did not have any distant metastases until her fifth postoperative year when multiple metastases were detected in her spleen and in her left femoral head. The multidisciplinary tumor board did not

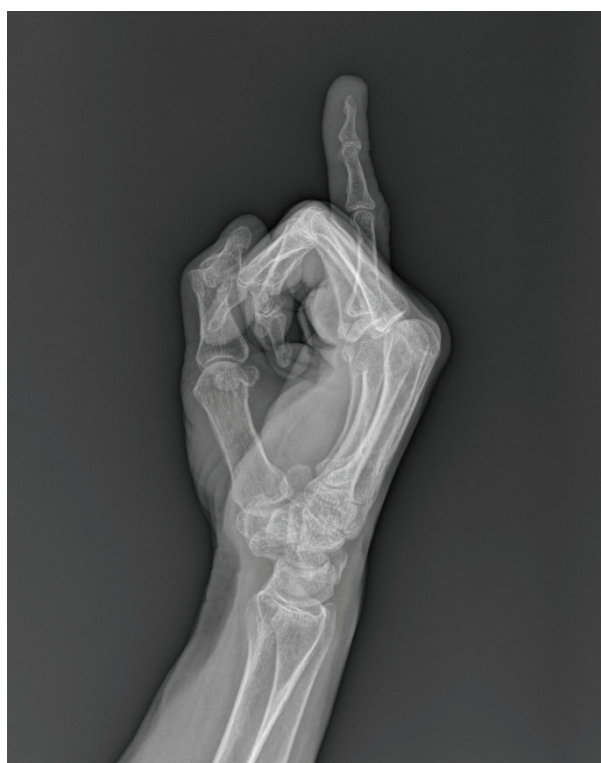refer the patient for metastasectomy and she had been treated with twenty sessions of splenic and left femoral radiotherapy. A bimonthly nivolumab therapy was initiated and it was continued for two years.

After a detailed history and a thorough physical examination, right-hand radiographs were obtained and an osteolytic lesion at the dorsal aspect of the fifth distal phalanx was detected (Figure 2). A punch biopsy was performed at the hyponychium and it revealed a gland forming, CD 10, PAX 8 and vimentin-positive renal clear cell carcinoma metastasis (Figure 3). A positron emission tomography and computed tomography scan were performed and splenic, left femoral and right fifth distal phalangeal metastases were found.

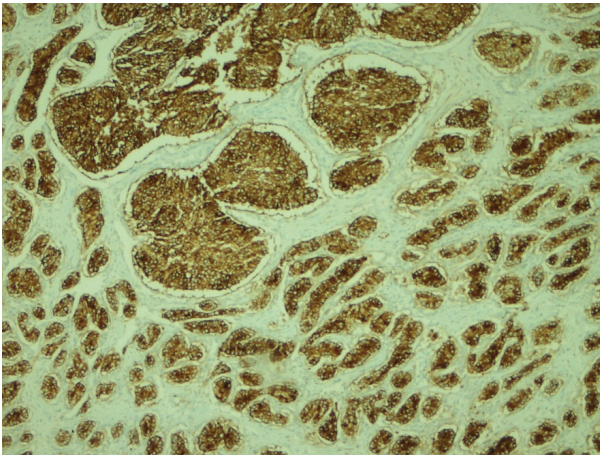
The operative treatment of this acrometastasis did not aim for a survival benefit for the patient; however, palliation was planned due to the progressive pain and enlargement of the lesion. Amputation of the right fifth distal phalanx was performed and the specimen was sent to the Department of Pathology, confirming the initial diagnosis. The patient was referred to the Department of Medical Oncology and her symptoms were relieved right after the operation. She did not come for the clinical follow-ups one year after the amputation.



**Figure 1:** The lesion is seen as a red macule at the junction between the nail plate and the hyponychium of the right fifth digit.



**Figure 2:** An osteolytic lesion at the dorsal aspect of the fifth distal phalanx is seen in the lateral view of the direct radiograph.



**Figure 3:** A gland forming, CD 10, PAX 8 and vimentin-positive renal clear cell carcinoma metastasis is demonstrated (200X magnification and Vimentin immunohistochemical staining).

The patient was informed about both the treatment and the study process and consent was obtained.

## DISCUSSION AND CONCLUSION

The hand has many primary mass lesions; however, physicians should be aware of metastatic lesions that may mimic primary ones (4). Primary lesions of the hand such as lobular capillary hemangioma, angiokeratoma, acral lentiginous malignant melanoma, squamous cell carcinoma and basal cell carcinoma should be included in the differential diagnosis of acrometastasis (9). In order to reach a precise diagnosis, a detailed history and physical examination is mandatory. Direct radiographs and contrast-enhanced computed tomography may aid in differentiating among other pathological conditions; however, histopathological verification of either excisional or incisional biopsy specimens is mandatory for accurate diagnosis (9).

Flynn et al. reviewed the relevant literature and they found that the male patients had twice as many acrometastases than female patients (1). Also, they found that the mean age of patients with acrometastases was 58 years (1). The age of this patient is concordant with the literature despite her gender. Flynn et al. evaluated the primary tumors and they found that renal cancer is the second most common source of acrometastases (1). This patient had renal clear cell carcinoma as her primary tumor and this finding is similar to the literature. The distal phalanx is the most common host for acrometastases (1) as it was seen in this patient. In the literature, the fifth digit is the least affected part of the hand; however, the acrometastasis was at the fifth digit of this patient (1). Thus, a rare metastasis was seen at a rare anatomic site.

Although metastasectomy does not affect overall survival, all studies support operative treatment of the acro-

metastases unless the patient has a medical contraindication for surgery (1-5). In fact, amputations may help to alleviate the debilitating symptoms of the patients, enabling palliation and increasing the quality of life.

Clinicians should be vigilant about new acral lesions in patients with a history of cancer. Despite their rarity, acrometastases should be included in the differential diagnoses of patients with renal clear cell carcinoma and a multidisciplinary approach should be the mainstay of the treatment.

**Peer Review:** Externally peer-reviewed.

**Author Contributions:** Conception/Design of Study- E.K., B.E.A., D.A., H.Ö.B.; Data Acquisition- E.K., B.E.A., D.A., H.Ö.B.; Data Analysis/Interpretation- E.K., B.E.A., D.A., H.Ö.B.; Drafting Manuscript- E.K., B.E.A., D.A., H.Ö.B.; Critical Revision of Manuscript- E.K., B.E.A., D.A., H.Ö.B.; Final Approval and Accountability- E.K., B.E.A., D.A., H.Ö.B.; Material or Technical Support- E.K., B.E.A., D.A., H.Ö.B.; Supervision- E.K., B.E.A., D.A., H.Ö.B.

**Conflict of Interest:** The authors have no conflict of interest to declare.

**Financial Disclosure:** The authors declared that this study has received no financial support.

## REFERENCES

1. Flynn C, Danjoux C, Wong J, Christakis M, Rubenstein J, Yee A, et al. Two cases of acrometastasis to the hands and review of the literature. *Curr Oncol* 2008;15(5):51-8. [\[CrossRef\]](#)
2. Milionis V, Vlachodimitropoulos D, Goutas D, Goutas N. Acrometastases in Renal Cell Carcinoma: A Case Report and Review of Literature. *Clin Oncol Case Rep* 2020;2:2.
3. Rommer E, Leilabadi SN, Lam G, Soltani A, Ellis CV, Rizvi M, et al. Metastasis of hepatocellular and renal cell carcinoma to the hand. *Plast Reconstr Surg Glob Open* 2014;1(9):e83. [\[CrossRef\]](#)
4. Hernández-Cortés P, Caba-Molina M, Gómez-Sánchez R, Ríos-Peregrina R. Renal clear cell carcinoma acrometastasis. an unusual terminal condition. *J Hand Microsurg* 2015;7(01):149-51. [\[CrossRef\]](#)
5. Kamala LH, Ranjith S, Benson R. Cutaneous acral metastasis from renal cell carcinoma—a case report. *Indian J Surg Oncol* 2019;1-3. <https://doi.org/10.1007/s13193-019-00961-2>. [\[CrossRef\]](#)
6. Capitanio U, Bensalah K, Bex A, Boorjian SA, Bray F, Coleman J, et al. Epidemiology of renal cell carcinoma. *Eur Urol* 2019;75(1):74-84. [\[CrossRef\]](#)
7. Padala SA, Barsouk A, Thandra KC, Saginala K, Mohammed A, Vakiti A, et al. Epidemiology of renal cell carcinoma. *World J Oncol* 2020;11(3):79-87. [\[CrossRef\]](#)
8. Ljungberg B, Albiges L, Abu-Ghanem Y, Bedke J, Capitanio U, Dabestani S, et al. European Association of Urology guidelines on renal cell carcinoma: the 2022 update. *Eur Urol*. 2022. [\[CrossRef\]](#)
9. Wolfe SW, Pederson WC, Kozin SH, Cohen MS. *Green's Operative Hand Surgery. Two Volumes. 5th Edition.* Elsevier, Churchill Livingstone. 2005.