

# Severe Abdominal Colic Pain During Pregnancy; A Case Report of Degenerate Uterine Leiomyoma

**Filiz Bilir, Nermin Akdemir, Selcuk Özden**

Sakarya Teaching and Education Hospital, Department of Gynecology and Obstetrics

## Abstract

Uterine leiomyoma and fibroma are the same name of the most common benign tumors of uterine and have been diagnosed on peri-menopausal ages. Even most of the women don't have any problem with fibroma's during their pregnancy, there is an increasing data about some complications in the literature. Here, we presented a case report women 33 years old at 20th week of gestation, admitted to our clinic with acute and colic abdominal pain with healthy fetus and growing fibroma. To our knowledge this is the first case report revealed that severe pain of fibroma can be treated with selected analgesics and it can spontaneously regress after the degeneration phase.

Key words: pregnancy, abdominal pain, myomauteri

### Introduction

Uterine leiomyoma and fibroma are the same name of the most common benign tumors of uterine and have been diagnosed on peri-menopausal ages. They are usually diagnosed incidentally so exact incidence is cannot calculate that, but, at least half of patients have decreased quality of life, any symptoms such as anemia, pain, menstrual dysfunctions and fertility problems. Even most of the women don't have any problem with fibroma's during their pregnancy, there is an increasing data about some complications in the literature.

Here, we presented a case report women 33 years old at 20th week of gestation, admitted to our clinic with acute and colic abdominal pain with healthy fetus and growing fibroma.

### Case Report

A pregnant woman 33 years old and she was on second pregnancy. She had slight abdominal pain which was started on 20th week of gestation, especially aggravated with exercise, but, after 3 days of this complaint she went to emergency for severe acute abdominal colic pain. According to abdominal ultrasound the baby was fine, no abdominal fluid collection, no any abnormal renal finding and there was an 8-cm fibroma at the left upper part of the uterus. She reported that her fibroma was 3 cm before the pregnancy. On physical examination, there was some tenderness in left abdomen with a palpable mass, no rebound but increased intestine sounds. She did not have pain relief with paracetamol 2 gr per day, so we ordered nonsteroidal anti-inflammatory suppo-

sitory (indomethacin 100 mg twice a day up to three days). First day of admission she had some pain relief, but on the second day she had severe pain again. During this time serum blood tests and urine tests excluded any abnormality. Pain characteristic was 4-5 times it has a peak severity with a relief within 5-10 minutes after peak, but most of the day she had a slight pain especially with turning on the bed. We ordered an abdomen MRI and it showed 8 cm heterogenous fibroma without bleeding (Figure 1). On the third day of indomethacin, we ordered Petidin hidroclor (Aldolan) flacon 1 time a day because of her severe colic pain. During this period baby did not have any stress finding in NTS and ultrasound measurements. After the 10th day of first pain starts, her pain become more than 75% of relief and discharged the patient. On follow up her last fibroid diameter was 4 cm and without any abnormal finding.

### Discussion

Estrogen peaking is one of the most, but not only one factor for fibromas grow. Their size usually increase in the first trimester without severe symptoms and then, slowly growing and decrease in size second and third trimester, respectively. In our case, first ultrasound examination showed a 8-cm fibroma which was done on 13th week of pregnancy and at this time the patient did not have any symptoms. When her complaint was started, she had 6 cm fibroma and it became up to 8-cm on 21th week of pregnancy. Last follow up imaging showed 4 cm of fibroma at third trimester. So, highest pain intensity was observed the peak of size and starting degeneration of fibroma. The pain can be explained by ische-

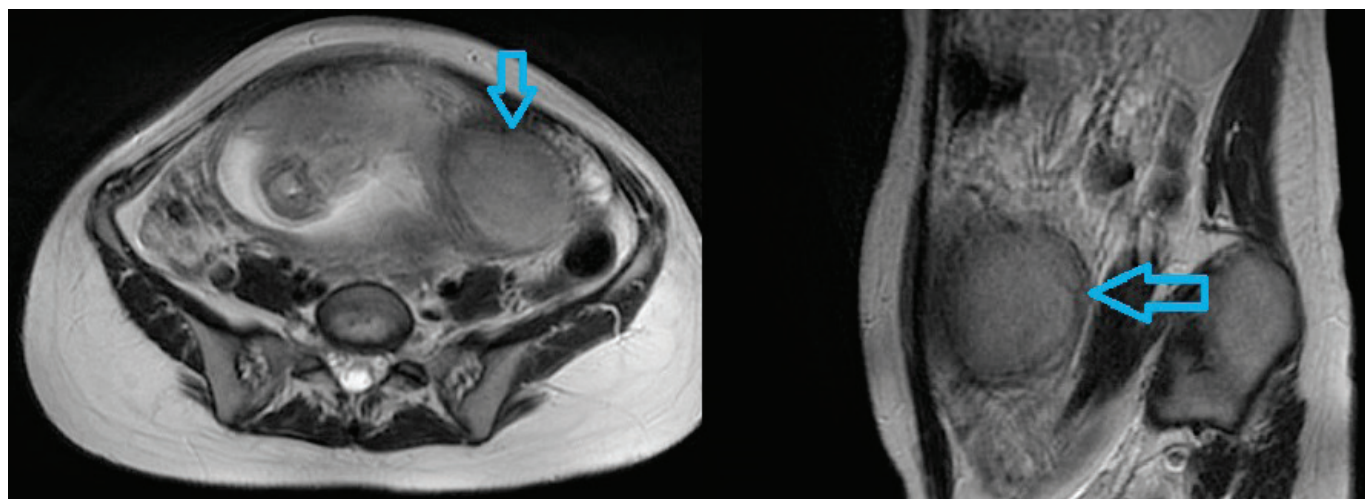


Figure 1: Two picture of pelvic MRI shows fibroma marked with blue arrows

mic effect of fibroma degeneration or compressing and/or pulling effect of the round ligament during the degeneration period.

Uterine fibromas can have some complications, submucosal and intramural fibroma usually cause fertility problems and surgical treatments can cause further infertility complications. Some of the fibroma can have a specific complication related to its size and location as increase the C-section rates<sup>1</sup>. Myomectomy is rarely done in pregnant women, except for symptomatic pedunculated fibroids, there are some case reports which fibromas complicated as torsion and massive abruption.

In our case report, fibroma complicated as an acute abdominal severe pain related to the degeneration of fibroma.

To our knowledge this is the first case report revealed that severe pain of fibroma can be treated with selected analgesics and it can spontaneously regress after the degeneration phase.



## References

1. Vitale SG, Padula F, Gulino FA. Management of uterine fibroids in pregnancy: recent trends. *Curr Opin Obstet Gynecol.* 2015;27:432-7.
2. Vilos GA, Allaire C, Laberge PY, et al. The management of uterine leiomyomas. *J Obstet Gynaecol Can* 2015; 37:157-181.
3. Benaglia L, Cardellicchio L, Filippi F, et al. The rapid growth of fibroids during early pregnancy. *PloS One* 2014; 9:e85933.
4. Piazza Garnica J, Gallo G, Marzano PF, et al. Clinical and ultrasonographic implications of uterine leiomyomatosis in pregnancy. *Clin Exp Obstet Gynecol* 1995; 22:293-297.
5. Sachan R, Patel ML, Sachan P, Arora A. Complete axial torsion of pregnant uterus with leiomyoma. *BMJ Case Rep* 2014; 2014: doi: 10.1136/bcr-2014- 205558.
6. Deshpande G, Kaul RPM. A case of torsion of gravid uterus caused by leiomyoma. *Case Rep Obstet Gynecol* 2011; 2011:206418. doi: 10.1155/2011/206418.