

Necrotizing Fasciitis After Hemorrhoidectomy

HEMOROİDEKTOMİ SONRASI NEKROTİZAN FASİİT

Arda Şakir YILMAZ,¹ **Yasin EKİCİ**,² **Bartu BADAĞ**²

¹Sivrihisar Devlet Hastanesi Genel Cerrahi, Eskişehir, Türkiye

²Osmangazi Üniversitesi Tıp Fakültesi Genel Cerrahi Anabilim Dalı Eskişehir, Türkiye

ABSTRACT

Necrotizing fasciitis (NF) is a progressive soft tissue infection involving the lower extremities and perianal region, extending from the skin to the fascia. Although it is frequently seen in the elderly, it can be seen in all age groups with concomitant diseases, previous surgery history, and immune system disorders. NF, which develops as a result of rapid tissue invasion, can cause serious morbidity and mortality if early diagnosis and early surgical debridement are not performed. Therefore, NF should be suspected if pain, fever, and septic markers are disproportionate to the lesion in the clinic. The most important step in the treatment of NF is early surgical debridement and initiation of appropriate antibiotics. In addition to these treatments, various wound care treatments can also be applied. We tried to explain the process from diagnosis to discharge in a patient who developed NF after hemorrhoidectomy in terms of treatment management.

Key words: Necrotizing fasciitis, fasciotomy, hemorrhoids

ÖZ

Nekrotizan fasiit (NF); genellikle alt ekstremitte ve perianal bölgeyi tutan, ciltten fasyaya kadar uzanan, progresif bir yumuşak doku enfeksiyonudur. Sıklıkla yaşlılarda görülmesine rağmen yandaş hastalıklar, geçirilmiş cerrahi öyküsü ve immün sistem bozuklukları olan her yaş grubunda görülebilmektedir. Hızlı doku istilası sonucu gelişen NF, erken tanı ve erken cerrahi debridman yapılamaz ise ciddi morbidite ve mortaliteye sebep olabilmektedir. Bu nedenle klinikte lezyon ile orantısız ağrı, ateş ve septik belirteçler varsa NF den şüphelenilmelidir. NF'nin tedavisinde en önemli basamak erken cerrahi debridman ve uygun antibiyoterapi başlanmasıdır. Ayrıca bu tedavilerin yanında çeşitli yara bakım tedavileri de uygulanabilmektedir. Biz de hemoroidektomi sonrası NF gelişen bir olguda tanıdan taburculuğa geçen süreci, tedavi yönetimi açısından anlatmaya çalıştık.

Anahtar kelimeler: Nekrotizan fasiit, fasyotomi, hemoroid

Arda Şakir YILMAZ

Sivrihisar Devlet Hastanesi, Genel Cerrahi
Eskişehir, Türkiye

E-posta: dr.ardayilmaz@hotmail.com

<https://orcid.org/0000-0003-1269-0814>

Necrotizing fasciitis (NF) is a soft tissue infection involving the skin, subcutaneous tissues, and fascia, often observed in the lower extremities and perineum (1). It is seen at a rate of 4.8 per hundred thousand per year in the United States, and it is more common in elderly individuals (2). Perianal infections, immune system disorders, surgical interventions, and traumas are among the main causes of

NF (3). These patients usually apply to the hospital with non-specific symptoms such as pain, weakness, and fever. However, if the diagnosis and treatment are delayed, it may come in a septic shock. In physical examination; progressive skin erythema, soft tissue crepitation, and fever are observed (4). The most common bacteria causing this are gram-positive aerobes such as enterococci and

streptococci; gram-negative aerobes such as *Escherichia coli* and *Pseudomonas aeruginosa*; They are anaerobes such as *Clostridium* and *Bacteroides* (5). NF, which develops as a result of rapid tissue invasion, can cause serious morbidity and mortality if early diagnosis and early surgical debridement are not performed.

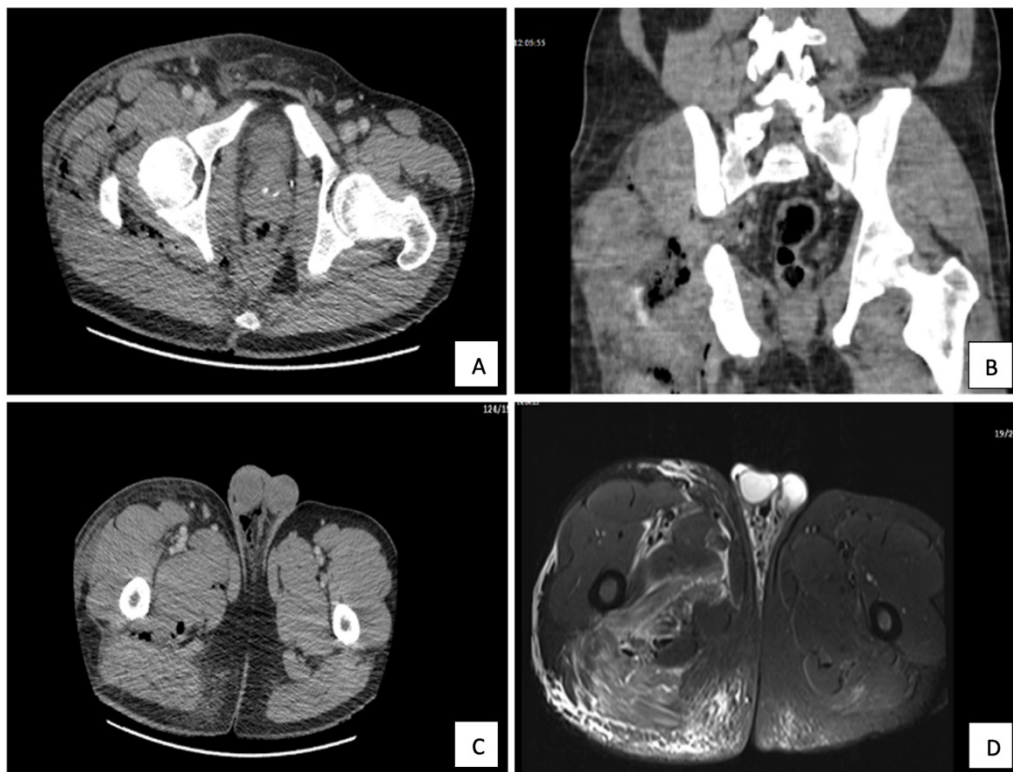
We tried to explain the process from diagnosis to discharge and the management of NF treatment in a patient with NF who developed after hemorrhoidectomy.

CASE REPORT

A 46-year-old male patient received medical treatment for his hemorrhoidal complaints for 2 years but was operated on in an external center because there was no response to the treatment. On the 2nd postoperative day, she was admitted to the hospital due to increased pain in

the anal region and swelling in the scrotum, and on the diagnostic pelvic CT, it was found that the skin and subcutaneous tissue thickness increased and edematous in the right pelvic region inferolateral and proximal anterior of the thigh. In addition, there are occasional air densities in the right gluteal, right proximal lateral and posterior parts of the right thigh, and diffuse free air densities were observed in the right hemiscrotum. In addition, loculated areas of fluid were observed between the fasciae in the neighborhood of the right femur (Figure 1A-C). In the subsequent pelvic magnetic resonance (MR) imaging, an increase in signal in favor of grade 1 strain was observed in the effusion and adductor muscle structures along the medial skin and subcutaneous fat planes in the right thigh proximal, and in the gluteus maximus muscle (Figure 1D).

Figure 1. A. Appearance of rough and edematous skin-subcutaneous and fascia **Figure1. B-C.** Edema and air densities in right gluteal and right thigh proximal **Figure 1.D.** Effusion in right thigh MR view



Thereupon, he was re-operated with the diagnosis of severe NF. Surgical debridement, curettage, fasciotomy, and abscess drainage from the scrotum were performed by

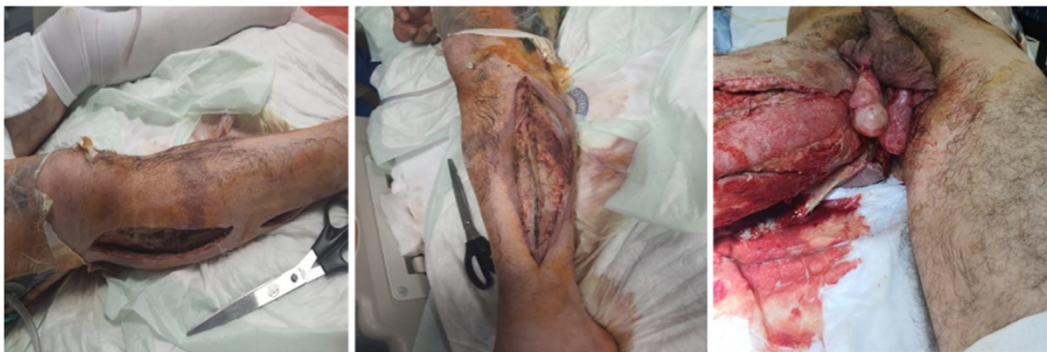general surgery, orthopedics, and urology. However, the patient was referred to us due to the deterioration of his

general condition and the development of sepsis during his follow-up.

In the laboratory values of the patient admitted to the intensive care unit; Hemoglobin: 14.6 g/dL, leukocytes: 10630 μ L, C-reactive protein: 310.9 mg/L, sodium: 139 mEq/L, glucose: 134 mg/dL, creatinine: 1.27 mg/dL, Lactate: 4.3 mmol/L, pH: 7.191 was seen. The patient was re-evaluated by us and the patient who was found to be septic

was operated for emergency surgical debridement after informed consent was obtained. During the operation, in the medial and lateral part of the right thigh; There was fasciitis involving the fascia of the quadriceps femoris, sartorius, gracilis, and gluteus maximus muscles, as well as extensively involving the perianal region and scrotum (Figure 2).

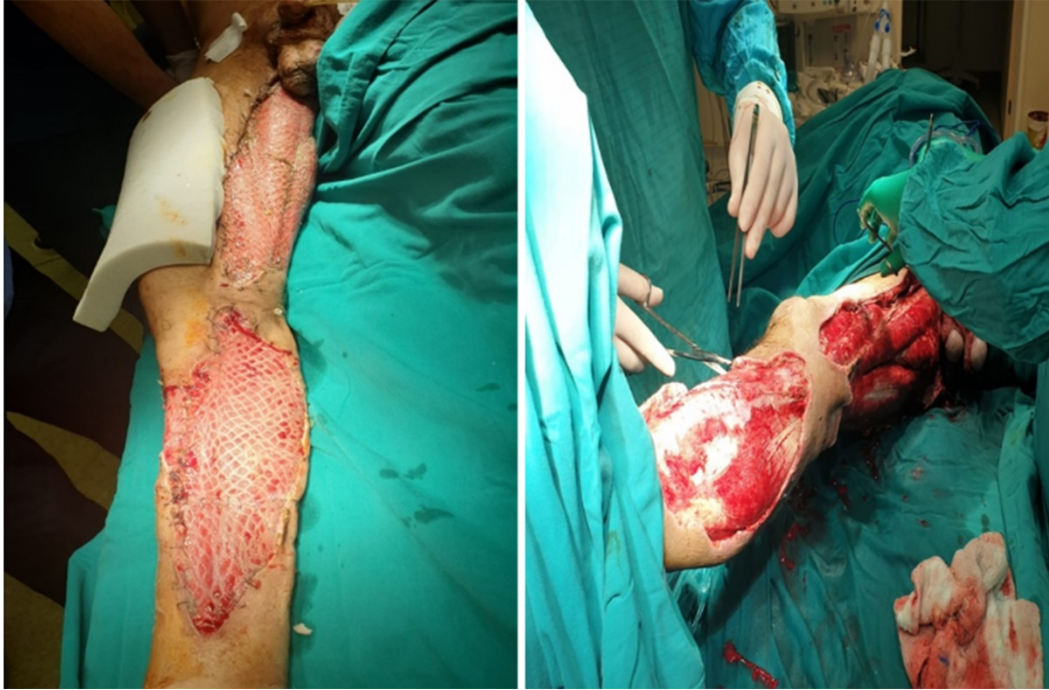Figure 2. Clinical evaluation at admission



In addition, there was a large area of fasciitis reaching the fascia in the lateral of the right leg, anterior and posterior to the tibialis, and saphenous vein necrosis. Wound cultures were taken. Then, the necrotic tissues in the area were debrided, the saphenous vein was resected, and the operation area was washed with abundant isotonic solutions. Negative pressure vacuum therapy (NBVT) was started in the area. To prevent contamination, the patient underwent a laparoscopic sigmoid loop colostomy. The patient was taken to the intensive care unit after the operation and was consulted to the relevant departments. Infectious diseases were discussed. Imipenem and vancomycin treatment were started, following the antibiotic therapy recommendations. In the follow-up, due to weak peripheral pulses in the right lower extremity, cardiovascular surgery was consulted and ileomedin and heparin infusion was started for 3 days. Then, subcutaneous enoxaparin sodium and trentilin treatment was started. The patient underwent serial operations for debridement and NBVT. Upon the growth of *Acinetobacter Baumani* in the wound cultures of the patient, infectious diseases were consulted again and the treatment was continued with imipenem, vancomycin, and colistin. After

serial surgeries, the plastic surgery department was consulted for grafts because of the absence of necrotic tissue in the wound and adequate circulation. A skin graft was applied through plastic surgery (Figure 3).

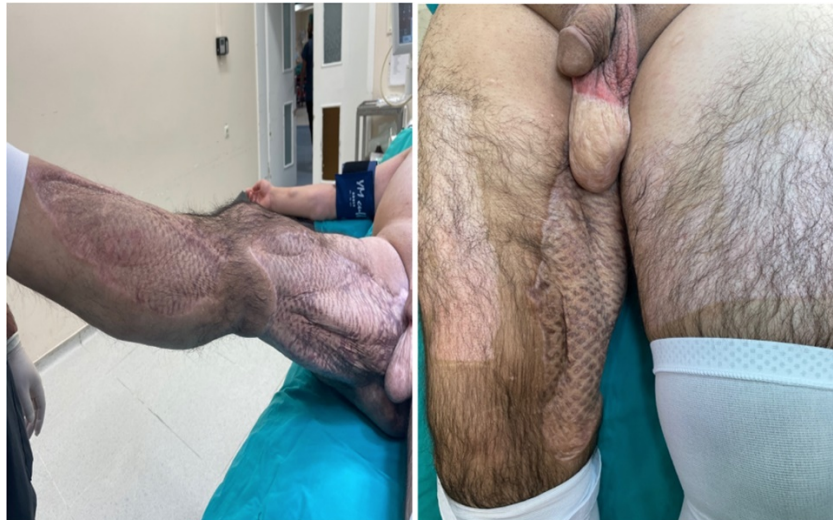Figure 3. Post-treatment grafting stage images



Then, about 10 days later, the patient was transferred to the physical therapy unit for rehabilitation. After 10 sessions of physiotherapy exercises, he was called for control and discharged. The patient was admitted to our center about 1 year later with a plan for closure of loop colostomy (Figure 4).

After the control colonoscopy, the anal sphincter tone was also normal and the colostomy was closed. He was discharged on the 6th postoperative day.

Figure 4. Appearance of well-being after treatment



DISCUSSION

NF is a soft tissue infection that commonly affects the skin, subcutaneous, and fascia in the lower extremities and inguinal region (1). In patients without early diagnosis and surgery, the mortality rate from NF varies between 8.7% and 73%, and this rate has decreased to 26-32% with early diagnosis and treatment in recent years (6-9). Common areas of involvement of the disease; the lower extremities (28%), upper extremity (27%), perineum (21%), trunk (18%), and head and neck (5%) (10). Similarly, perianal and scrotal region, right thigh, and right leg involvement were observed in our patient.

Important risk factors for the development of NF; Penetrant trauma or a history of surgery. Apart from these,

advanced age, diabetes mellitus, obesity, cancers, and autoimmune disorders are other causes (8). In our patient, previous perianal surgery, known smoking, and a history of phlebotitis are the main risk factors. Diagnosis is usually determined by clinical symptoms and suspicion. Patients may initially be confused with erysipelas and cellulitis. Pain and fever disproportionate to the lesion are important factors in the diagnosis (11). In addition, irregular borders and pain outside the lesion are characteristic (12, 13). The staging described by Wong (2005) and Wang (2007) is very useful in clinical evaluation. The clinical features of NF at the time of admission were evaluated and divided into three stages (Table 1) (12, 13).

Table.1 Staging of necrotizing fasciitis

Stage	Clinical features
I (early)	Tenderness on palpation (extending the visible skin involvement), erythema, swelling, caloric (increase in skin temperature)
II (medium)	bullae formation (serous fluid), fluctuation in the skin
III (late)	Crepitation, skin anesthesia, skin discoloration, tissue necrosis up to gangrene

According to this classification, our case was evaluated as stage 3. Wong et al. (2005) determined a risk score for NF according to laboratory results as well as determining clinical severity (Laboratory Risk Indicator for

NECrotizing fasciitis = LRINEC). As a result of the scores calculated with this scoring, the mortality of the disease was tried to be estimated (Table 2).

Table.2 Laboratory Risk Markers for Necrotizing Fasciitis (LRINEC)

Value	LRINEC score
C- reactive protein (mg/L)	
<150	0
>150	4
White blood cell count (cells/mm³)	
<15	0
15-25	1
25<	2
Hemoglobin level (mg/dl)	
>13.5	0
11-13.5	1
<11	2
Sodium level (mmol/L)	
≥135	0
<135	2
Creatinine level (mg/dL)	
≤ 1.6	0
>1.6	2
Glucose level (mg/dL)	
≤180	0
>180	1
According to LRINEC score; low stage: <5 points %50 mortality, moderate 6-7 points %50-75 mortality, high severe stage >8 points >%75 mortality.	

With this scoring, the estimated mortality rate for our case was calculated as 50% low stage.

NF is a multidisciplinary disease that requires early diagnosis and treatment. In order to reduce mortality, the diagnosis should not be delayed, and even if NF is suspected clinically, surgical intervention should be started immediately. If NF is clinically suspected, surgery should be performed even with a negative LRINEC score (14). This is because patients are at increased risk of amputation and death if intervention is delayed. Untreated or inadequately debrided patients can rapidly progress to septic shock with a mortality rate of nearly 100% (6). In addition, the patient's co-morbidities lead to a significant increase in mortality and morbidity. Cheng et al. found a significantly higher limb amputation rate compared to 28.6% in diabetic patients and 13.6% in non-diabetic patients ($p<0.05$) (15). Antibiotherapy should be chosen carefully in these patients. Antibiotics should be started empirically and

revised according to culture results. The average duration of antibiotic therapy defined for NF should be continued for 4-6 weeks.

CONCLUSION

In conclusion; NF is a rapidly progressive disease with a high mortality rate. For this reason, the most important parameter is clinical evaluation and aggressive surgical debridement should be performed in the early period, necrotic tissues should be removed from the environment and antibiotic therapy should be started as soon as possible.

REFERENCES

1. Legbo JN, Shehu BB. Necrotizing fasciitis: a comparative analysis of 56 cases. Journal of the National Medical Association. 2005;97(12):1692-1697.

2. Arif N, Yousfi S, Vinnard C. Deaths from necrotizing fasciitis in the United States, 2003-2013. *Epidemiology and infection*, 2016;144(6):1338-1344.
3. Stevens DL, Bisno AL, Chambers HF, et al. Practice guidelines for the diagnosis and management of skin and soft tissue infections: 2014 update by the infectious diseases society of America. *Clinical infectious diseases : an official publication of the Infectious Diseases Society of America*, 2014;59(2):147-159.
4. McDonald LS, Shupe PG, Raiszadeh K, Singh A. Misdiagnosed pneumothorax interpreted as necrotizing fasciitis of the chest wall: case report of a potentially preventable death. *Patient safety in surgery*, 2014;8:20.
5. Napolitano LM. Severe soft tissue infections. *Infectious disease clinics of North America*, 2009;23(3):571-591.
6. Weimer SB, Matthews MR, Caruso DM, Foster KN. Retroperitoneal Necrotizing Fasciitis from Fournier's Gangrene in an Immunocompromised Patient. *Case reports in surgery*, 2017;2017:5290793.
7. Chen Y, Wang X, Lin G, Xiao R. Successful treatment following early recognition of a case of Fournier's scrotal gangrene after a perianal abscess debridement: a case report. *Journal of medical case reports*, 2018;12(1):193.
8. Baig MZ, Aziz A, Abdullah UEH, Khalil MS, Abbasi S. Perianal Necrotizing Fasciitis with Retroperitoneal Extension: A Case Report from Pakistan. *Cureus*, 2019;11(7):e5052.
9. Roje Z, Roje Z, Matić D, Librenjak D, Dokuzović S, Varvodić J. Necrotizing fasciitis: literature review of contemporary strategies for diagnosing and management with three case reports: torso, abdominal wall, upper and lower limbs. *World journal of emergency surgery : WJES*, 2011;6(1):46.
10. Golger A, Ching S, Goldsmith CH, Pennie RA, Bain JR. Mortality in patients with necrotizing fasciitis. *Plastic and reconstructive surgery*, 2007;119(6):1803-1807.
11. Myers CM, Miller JJ, Davis WD. Skin and Soft Tissue Infections: A Case of Necrotizing Fasciitis. *Advanced emergency nursing journal*, 2019;41(4):322-329.
12. Wang YS, Wong CH, Tay YK. Staging of necrotizing fasciitis based on the evolving cutaneous features. *International journal of dermatology*, 2007;46(10):1036-1041.
13. Wong CH, Wang YS. The diagnosis of necrotizing fasciitis. *Current opinion in infectious diseases*, 2005;18(2):101-106.
14. Leiblein M, Marzi I, Sander AL, Barker JH, Ebert F, Frank J. Necrotizing fasciitis: treatment concepts and clinical results. *European journal of trauma and emergency surgery : official publication of the European Trauma Society*, 2018;44(2):279-290.
15. Cheng NC, Tai HC, Chang SC, Chang CH, Lai HS. Necrotizing fasciitis in patients with diabetes mellitus: clinical characteristics and risk factors for mortality. *BMC infectious diseases*, 2015;15:417.