

# An Intracranial Hemorrhage Complication: Terson Syndrome

 Muhammet Ikbal Isik<sup>1</sup>,  Ferhat Cuce<sup>1</sup>,  Mustafa Tasar<sup>1</sup>

<sup>1</sup>University of Health Sciences, Gülhane Training and Research Hospital, Clinic of Radiology, Ankara, Türkiye

## Abstract

Vitreous hemorrhage associated with subarachnoid hemorrhage is known as Terson's Syndrome (TS). However, it is also seen in the literature in cases of traumatic brain injury or intracranial hemorrhage. Management of visual manifestations is necessary in patients with intracranial hemorrhage.

A vitreous hemorrhage was found in the evaluation made due to visual symptoms in a patient who presented to the emergency department with intracranial hemorrhage. In addition to clinical findings, imaging techniques have an important place in the diagnosis of TS. Vitreous hemorrhage findings can be detected with imaging studies such as Computed Tomography (CT) and Magnetic Resonance Imaging (MRI).

In this case, the diagnostic findings and the importance of diagnosis in CT and MRI examinations in a patient with TS will be discussed. The purpose of this case report is to share the imaging findings of TS.

**Keywords:** Vitreous Hemorrhage, subarachnoid hemorrhage, terson syndrome, intracranial hemorrhage

## Introduction

Terson was the first to report the occurrence of intraocular hemorrhage (IOH) in subarachnoid hemorrhage (SAH). In a 60-year-old male patient, he reported having spontaneous intracranial hemorrhage (ICH) with right-sided IOH and transient left-sided [1]. Pathophysiologically, an abrupt and transient increase in intracerebral pressure is thought to be transmitted through the optic nerve sheath, causing rupture of the retinal vessels due to intraocular venous hypertension. Besides clinical neurological symptoms, patients usually have decreased visual acuity. A multidisciplinary approach is required in the treatment of TS. After the vital stabilization of the patient is achieved, there are a wide range of treatment options ranging from conservative methods to vitrectomy to correct the visual impairment [2]. Despite being a well-defined entity in the ophthalmological literature, it has rarely been interpreted in the neurosurgery discussion of SAH [3]. Attention should be paid to the presence of other findings that may be overlooked in addition to the common findings in the case of trauma. In head trauma, which is one of the most common conditions in emergency departments, other findings should be considered in addition to radiologically investigated traumatic brain injury, parenchymal hemorrhage, and skull base fractures. In this case, we wanted to draw attention to Terson's Syndrome,

which causes sequelae that can lead to permanent vision loss in the long term in patients with head trauma who applied to the emergency department.

## Case Report

An 84-year-old male patient was admitted to the emergency department with complaints of decreased vision in his left eye, loss of movement in his right arms and legs, and speech disorder. Neurological examination revealed a Glasgow Come Score (GCS) of 11/15 and right hemiparesis with mild motor aphasia. He had a history of chronic hypertension, stroke, coronary artery disease and diabetes. CT scan showed acute hyperdense parenchymal hematoma approximately 5 cm diameter in the parietooccipital lobe and fluid-fluid level of hemorrhage in the left bulbus oculi. Peri/retrobulbar soft tissues appear normal (**Figure 1**). Fluid-fluid leveling that supports bleeding products was clearly seen in Fluid Attenuated Inversion Recovery (FLAIR) sequence MRI examination (**Figure 2**). TS was diagnosed by considering ICH and IOH. Hygienic and dietary measures, strict rest, monitoring the disappearance of vitreous bleeding with periodic follow-ups, and thus increasing visual acuity constituted the ophthalmologic treatment. Surgical interventions were not considered. The patient was followed up in the intensive care unit and his treatment was started.

**Corresponding Author:** Muhammet Ikbal Isik

**e-mail:** drmikbaal@gmail.com

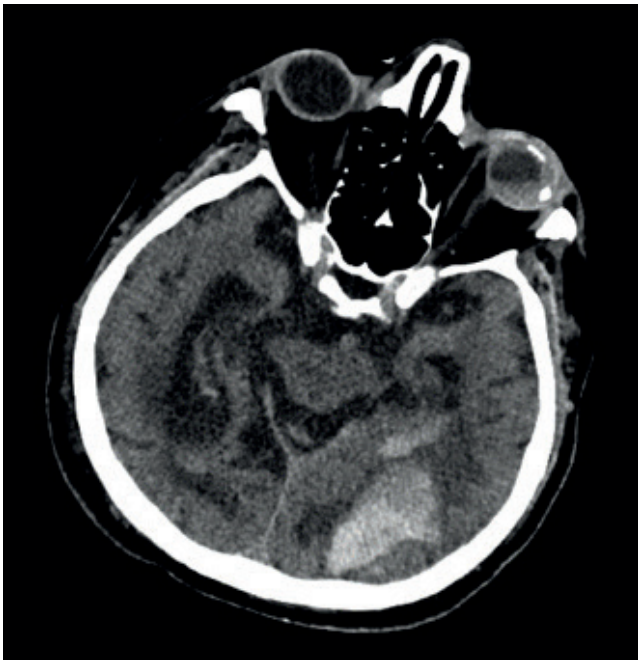
**Received:** 09.06.2023 • **Accepted:** 16.10.2023

**DOI:** 10.33706/jemcr.1312185

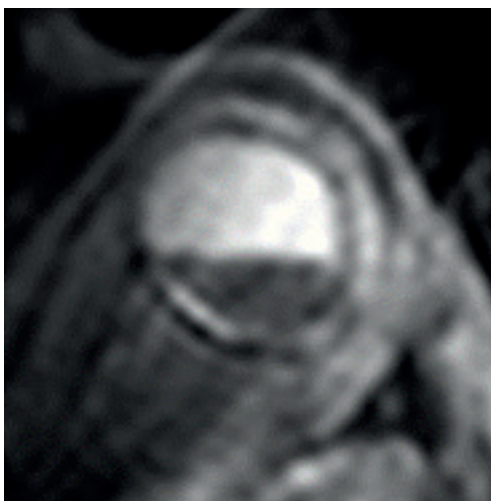
©Copyright 2020 by Emergency Physicians Association of Turkey -

Available online at [www.jemcr.com](http://www.jemcr.com)

**Cite this article as:** Isik MI, Cuce F, Tasar M. An intracranial hemorrhage complication: Terson syndrome. *Journal of Emergency Medicine Case Reports*. 2023;14(3): 66-68



**Figure 1.** In the axial unenhanced CT image, bleeding products that level the left bulbous oculi and intraparenchymal hemorrhage in an area of approximately 5 cm at the level of the left parietooccipital borderzone are observed.



**Figure 2.** Axial FLAIR sequence MR image shows a leveling appearance with low signal intensity consistent with vitreous hemorrhage in the left bulbous oculi.

Neurologically, the process was favorable with progressive improvement in his clinical condition.

## Discussion

TS is known as a secondary complication of SAH. The incidence of TS is defined as a variable in the literature and is reported between 10% and 50% after SAH. However, it seems to be underestimated in terms of its incidence and clinical course [3]. If not diagnosed early, it can cause serious ocular complications up to permanent blindness. In the literature, up to 46% of all SAH patients may suffer from

IOH, which in some cases leads to permanent blindness. In addition to SAH, TS can also be associated with traumatic brain injury (TBI) and ICH. Only a few prospective studies have been published on this condition. Less in the context of TS and ICH and TS and TBI. In our case, IOH was seen accompanying non-traumatic ICH.

TS is associated with a high mortality of up to 90% in SAH patients [4]. Currently, low GCS, high Hunt and Hess ratings, and high Fisher scale scores have been associated with a higher incidence of TS in large prospective studies. Frizzel et al. [5] reported that 8 patients with vitreous hemorrhage had a poor clinical course with transient or prolonged coma, and 89% of their patients had additional IOH.

Different pathophysiological mechanisms have been described for IOH. However, the widely accepted mechanism emerged with Manschot's experimental work in 1954 [6]. According to this mechanism, an abrupt increase in intracranial pressure (ICP) can cause rapid effusion of CSF from the optic nerve sheath to the periphery. As a result, dilatation of the retrobulbar portion of the optic nerve mechanically compresses the central retinal vein. Venous hypertension leads to venous stasis and subsequent rupture of the thin retinal vessels. A pattern of increase in ICP explains both the initial and delayed manifestations of ocular hemorrhage, as well as other pathologies with increased ICP that can lead to IOH [3]. Another accepted mechanism is the direct leak of SAH into the intraocular spaces [7].

Patients with TS should be evaluated in terms of radiological, ophthalmological, and neurosurgery and followed closely clinically. Demonstration of hyperdense bleeding products on CT and fundoscopic examination is diagnostically necessary. Ocular ultrasound examination can also be an effective tool to contribute to the diagnosis [8].

Conservative method is preferred primarily in the treatment. However, intraocular bleeding may persist in some patients. In these patients, an ophthalmological surgical intervention called pars plana vitrectomy is performed. Another emerging therapeutic option is intravitreal injection of tissue plasminogen activator or sulfur hexafluoride [9]. In addition, patients are followed closely with the ophthalmological examination. Elevating the head with bed rest, drinking plenty of fluids, and avoiding anticoagulant drugs may benefit patients. Generally, spontaneous resorption is expected to occur within a few months [2].

## Conclusion

Intracranial compartments are primarily evaluated in the emergency radiology of brain CT and orbital pathologies may be overlooked. Studies have shown that mortality is significantly increased in patients with intraocular hemorrhage, also known as TS [4]. Therefore, radiologists should pay attention to IOH and state it in their reports.

Thus, it is predicted that the prognosis will be better with rapid diagnosis and treatment.

### **Informed consent**

*Written informed consent was obtained from the patient for publication of this case and any accompanying images.*

## **References**

1. Fahmy JA. Vitreous haemorrhage in subarachnoid haemorrhage - Terson's syndrome: report of a case with macular degeneration as a complication. *Acta Ophthalmologica* 2009; 50:137–143.
2. Issiaka M, Mchachi A, Rachid R, Belhadji MEL, Mahazou I, Banao M. Terson syndrome: two case reports. *International Journal of Surgery Case Reports* 2022; 90:106700.
3. Czorlich P, Skevas C, Knospe V et al. Terson syndrome in subarachnoid hemorrhage, intracerebral hemorrhage, and traumatic brain injury. *Neurosurg Rev* 2015; 38:129–136.
4. Fountas KN, Kapsalaki EZ, Lee GP et al. Terson hemorrhage in patients suffering aneurysmal subarachnoid hemorrhage: predisposing factors and prognostic significance. *JNS* 2008; 109:439–444.
5. Frizzell RT, Morris R. Screening for ocular hemorrhages in patients with ruptured cerebral aneurysms: a prospective study of 99 patients. 1997; 41:6.
6. Manschot WA. Subarachnoid hemorrhage. *American Journal of Ophthalmology* 1954; 38:501–505.
7. Iuliano L, Fogliato G, Codenotti M. Intraoperative imaging of subinternal limiting membrane blood diffusion in Terson syndrome. *Case Reports in Ophthalmological Medicine* 2014; 2014:1–3.
8. Czorlich P, Burkhardt T, Knospe V et al. Ocular ultrasound as an easy applicable tool for detection of Terson's syndrome after aneurysmal subarachnoid hemorrhage. *PLoS ONE* 2014; 9:e114907.
9. Kapoor S. Terson syndrome: an often overlooked complication of subarachnoid hemorrhage. *World Neurosurgery* 2014; 81:e4.